

Late-onset Cerebrotendinous Xanthomatosis with Mild Symptoms: A Case Report

Gaoling Li¹, Pei Shang^{1*} and Chao Yuan^{1*}

¹Department of Neurology, Nanfang Hospital, Southern Medical University, Guangzhou, China

*Corresponding author:

Pei Shang,

Department of Neurology, Nanfang Hospital, Southern Medical University, Guangzhou Road North 8838#, Guangzhou, China, 510515, China; Department of Neurology, Mayo Clinic, Rochester, MN, USA and Chao Yuan, Department of Neurology, Nanfang Hospital, Southern Medical University, Guangzhou, China

Received: 03 Jan 2026

Accepted: 08 Jan 2026

Published: 12 Jan 2025

J Short Name: ACMCR

Copyright:

©2025 Pei Shang. This is an open access article distributed under the terms of the Creative Commons Attribution License, which permits unrestricted use, distribution, and build upon your work non-commercially

Keywords:

Cerebrotendinous Xanthomatosis; Dysarthria; Genetic Testing

Citation:

Pei Shang, Late-onset Cerebrotendinous Xanthomatosis with Mild Symptoms : A Case Report. Ann Clin Med Case Rep® 2026; V15(1): 1-3

1. Abstract

Cerebrotendinous xanthomatosis (CTX) typically presents with infantile diarrhea, juvenile cataracts, and tendon xanthomas. We report a diagnostically challenging case of late-onset CTX in a 48-year-old male presenting with isolated progressive dysarthria as the sole predominant neurological feature. Notably, the patient lacked classic biochemical hallmarks, demonstrating normal serum cholesterol levels, and exhibited only minimal, non-specific neuroimaging findings (subtle DWI hyperintensities in the posterior limbs of the internal capsules) without characteristic dentate nucleus abnormalities. A definitive diagnosis was established through genetic testing, which revealed compound heterozygous mutations in the CYP27A1 gene: a pathogenic splice-site variant (c.446+1G>T) and a variant of uncertain significance (c.877A>T, p. Met 293Leu). The patient was subsequently initiated on combination therapy with chenodeoxycholic acid and simvastatin. In this case, we focus on the oligosymptomatic CTX phenotype and highlight the critical role of genetic testing in confirming the diagnosis in cases with atypical presentations.

2. Introduction

CTX is a rare autosomal recessive inborn error of bile acid synthesis, caused by mutations in the CYP27A1 gene, leading to the accumulation of cholestanol and cholesterol in various tissues [1]. Thus far, only a few cases of CTX have been reported. Classic clinical manifestations of CTX are featured by infantile-onset diarrhea, childhood-onset cataracts, tendon xanthomas developing from adolescence to early adulthood. When reaching adulthood, the clinical picture becomes more complicated with progressive neurological dysfunctions (dementia, psychiatric disorders, pyramidal and/or cerebellar symptoms, dystonia, atypical Parkinson's disease, peripheral neuropathy, and epilepsy). While early diagnostic clues involve gait disturbance,

abnormal reflexes, and cataracts, we present a diagnostically challenging case of late-onset CTX where isolated progressive dysarthria was the sole predominant feature, absent the classic biochemical or imaging hallmarks.

3. Case Presentation

A 48-year-old Chinese male presented with a two-year history of progressive speech impairment. Neurological examination revealed significant dysarthria, but no abnormalities in muscle strength, sensation, or deep tendon reflexes. Laboratory investigations demonstrated unremarkable serum lipid profiles, with total cholesterol at 4.27 mmol/L (normal: <5.60 mmol/L) and low-density lipoprotein cholesterol (LDL-C) at 2.73 mmol/L (normal: <3.40 mmol/L). Laryngoscopy identified signs of chronic laryngitis (Figure 1); however, the patient's dysarthria showed no improvement following a prolonged course of anti-inflammatory therapy, suggesting a non-inflammatory, central neurological etiology. Notably, no tendon xanthomas were palpated, and the patient reported no family history of CTX or similar neurological disorders.

Brain magnetic resonance imaging (MRI) revealed subtle, symmetric hyperintensities on DWI sequences within the posterior limbs of the bilateral internal capsules. No significant abnormalities were observed in the cerebellar dentate nuclei on T2-weighted images (Figure 1).

Given the atypical presentation, genetic testing was pursued. Second-generation sequencing of the CYP27A1 gene identified two heterozygous mutations: a known pathogenic splicing variant (c.446+1G>T) and a variant of uncertain significance (c.877A>T, p. Met 293Leu). The diagnosis of CTX was confirmed based on the presence of one definitive pathogenic mutation. The patient was subsequently started on combination therapy with chenodeoxycholic acid (CDCA, 750 mg/day) and simvastatin (40 mg/day).

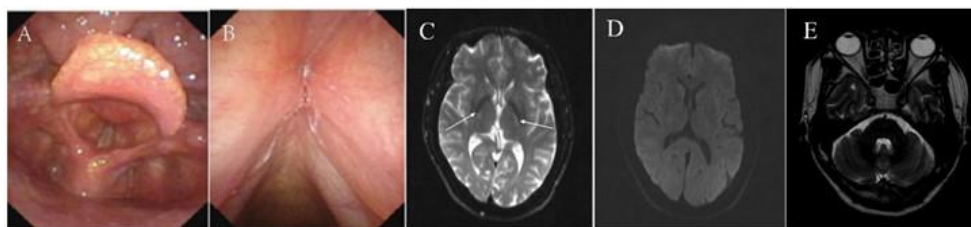


Figure 1: Neuroimaging and laryngoscopy findings. (A, B) Laryngoscopy showing chronic laryngitis. (C, D) Diffusion-weighted imaging (DWI) showing symmetric hyperintensities (arrows) in the posterior limbs of the bilateral internal capsules. (E) T2-weighted image showing no significant abnormalities in the cerebellar dentate nuclei.

3.1. Genetic Diagnosis

Genetic analysis of the *CYP27A1* gene revealed two heterozygous mutations. The c.446+1G>T variant is a canonical splice-site mutation, classified as pathogenic according to the American College of Medical Genetics and Genomics (ACMG) guidelines. The second variant, c.877A>T (p. Met 293Leu), is a missense mutation interpreted as a variant of uncertain significance (VUS).

3.2. Personal and Family History

The patient's parents are deceased with no reported history of neurological disease. He has two children. Genetic testing showed that his daughter carries neither mutation. His son is an asymptomatic carrier of the same compound heterozygous mutations (c.446+1G>T and c.877A>T) as the proband.

4. Discussion

This case highlights the diagnostic challenges posed by late-onset, oligosymptomatic CTX. Our patient presented with isolated progressive dysarthria, normal serum cholesterol levels, and only minimal, non-specific neuroimaging findings, deviating markedly from the classic clinical phenotype.

The estimated global prevalence of CTX is likely underestimated due to its nonspecific and heterogeneous presentation. Based on available epidemiological data and research methods, the current number of CTX cases is underestimated (e.g., estimated 3-5 per 100000 in Caucasians of American/European descent and the higher in east and South Asia) [1]. The notable disparity between the estimated incidence of CTX and the scant number of confirmed cases reported in the medical literature suggests a significant prevalence gap, pointing to widespread underdiagnosis or misdiagnosis. This implies that existing tools may fail to identify adults with mild or isolated neurological symptoms, leading to significant diagnostic delays.

A combination of clinical, biochemical, and imaging findings is employed in the diagnostic evaluation of CTX; however, genetic testing provides conclusive confirmation and is considered the diagnostic gold standard (2). The presenting features of CTX are often extra-neurological. Characteristic early signs include chronic diarrhea of infancy, juvenile cataracts, and the development of tendon xanthomas from adolescence onward [3, 4]. The clinical presentation in adults with late-onset disease commonly includes a combination of two or more neurological manifestations, for instance, pyramidal and cerebellar signs, cognitive impairment or dementia, and autistic features [5]. Not all pa-

tients develop the full constellation of classic symptoms. In fact, significant interindividual variation in the clinical phenotype is observed, attributable to differences in causative mutations (genotype-phenotype correlations), age, and racial background [1, 6]. The absence of tendon xanthomas in a subset of CTX patients poses a significant diagnostic challenge, often leading to misdiagnosis as peripheral neuropathy, congenital intellectual disability, or multiple sclerosis. In such cases, the detection of elevated serum cholestanol levels serves as a key discriminatory biomarker [1]. Furthermore, the early clinical presentation of CTX can overlap significantly with that of familial hypercholesterolemia and Marinesco-Sjögren syndrome, all of which are linked to hereditary cholesterol metabolic defects. This similarity poses a significant diagnostic challenge, making definitive differentiation reliant on specific biochemical and genetic assays [7, 8]. The diagnostic challenge in our case was compounded by two atypical features: the isolation of dysarthria as the primary symptom and the finding of a normal serum cholesterol level, necessitating genetic confirmation for a definitive diagnosis.

Brain MRI in patients with CTX typically reveals characteristic T2-weighted hyperintensities in specific deep gray matter nuclei, including the dentate nucleus, globus pallidus, substantia nigra, and inferior olivary nuclei. In advanced stages, the dentate nucleus may also exhibit T2 hypointensity [9]. These imaging abnormalities are likely attributable to neurotoxic injury resulting from the accumulation of cholestanol and cholesterol, which disrupts blood-brain barrier integrity. However, not all patients with CTX demonstrate these classic neuroimaging findings. In the present case, brain MRI revealed only subtle T2 hyperintensities within the posterior limbs of the bilateral internal capsules, with no notable atrophy or signal abnormalities in the dentate nuclei or evidence of diffuse white matter degeneration. The mild nature of these neuroimaging alterations correlates well with the patient's relatively modest clinical symptoms. This observation underscores the existence of an attenuated phenotypic variant of CTX, which may be substantially underdiagnosed in clinical practice due to its subtle radiological and clinical presentation.

The significant gap between the estimated and clinically identified prevalence of CTX highlights the urgent need for more sensitive screening strategies-whether through refined clinical criteria or novel biochemical markers-to improve detection of mild or atypical cases. As early as the year 2000, it was proposed that the presence of two or more of four key clinical features-premature cataracts, refractory diarrhea, progressive neu-

rological impairment, and tendon xanthomas—should prompt comprehensive biochemical evaluation for CTX, including serum cholestanol measurement and urinary bile alcohol analysis [10]. Particular attention should be paid to the co-occurrence of childhood cataracts and chronic diarrhea, as well as the later emergence of neuropsychiatric decline and xanthomas in adults [4]. To standardize early detection efforts, an international collaborative study developed a CTX suspicion index, integrating clinical elements such as neonatal cataracts, infantile diarrhea or cholestatic jaundice, adult-onset xanthomas, and characteristic neurological or MRI abnormalities [11]. While CTX is fundamentally a pediatric-onset disorder that manifests clinically in adulthood, early intervention is critical to altering disease progression, highlighting the importance of pediatric screening [12, 13]. The present case, with an onset at 46 years and mild symptomatology, fits the classification of late-onset CTX. Existing screening tools perform well in pediatric and severely affected populations, yet are likely to miss such oligosymptomatic adult cases. Therefore, in patients with late-onset, mild, or nonspecific neurological presentations, neurologists should maintain a high index of suspicion and pursue genetic testing to confirm or exclude CTX, even in the absence of classic biochemical or imaging abnormalities.

The pathophysiology of CTX involves mutations in the *CYP27A1* gene, which disrupts both the classical and alternative pathways of bile acid synthesis, leading to a marked deficiency of chenodeoxycholic acid (CDCA) and accumulation of cholestanol and cholesterol in tissues. Oral CDCA replacement therapy restores the negative feedback regulation on bile acid synthesis, thereby inhibiting the production of neurotoxic metabolites and has been shown to ameliorate clinical symptoms and potentially reverse certain disease processes [1]. In adult patients, the combination of CDCA with an HMG-CoA reductase inhibitor (statin) can further reduce serum cholesterol and LDL-C, offering complementary lipid-lowering benefits (14). In accordance with this evidence, the present patient was initiated on a regimen of CDCA (750 mg daily) combined with simvastatin (40 mg daily). The therapeutic efficacy of this intervention in halting disease progression or reversing neurological manifestations in this specific case requires further longitudinal assessment.

5. Conclusion

This report presents a case of late-onset CTX manifesting as isolated dysarthria without characteristic neuroimaging findings. The patient's subtle clinical presentation exemplifies the diagnostic difficulty in identifying CTX when both classic symptoms and typical radiological features are absent. Our experience reaffirms the crucial role of genetic testing in establishing a definitive diagnosis in such clinically ambiguous scenarios. Although CTX remains a rare disorder, it should be considered in the differential diagnosis of adults presenting with unexplained progressive dysarthria, even in the absence of distinctive imaging abnormalities. A comprehensive diagnostic approach including genetic analysis is warranted in these cases to facilitate accurate diagnosis and enable timely therapeutic intervention.

6. Fundings

The authors declare that financial support was received for the research and/or publication of this article. This work was supported by Clinical Research Fund of Nanfang Hospital, Southern Medical University(2023CR022).

Reference

1. Salen G, Steiner RD. Epidemiology, diagnosis, and treatment of cerebrotendinous xanthomatosis (CTX). *J Inher Metab Dis*. 2017; 40(6): 771-81.
2. Chen W, Kubota S, Teramoto T, Ishida S, Ohsawa N, Katayama T. Genetic analysis enables definite and rapid diagnosis of cerebrotendinous xanthomatosis. *Neurology*. 1998; 51(3): 865-7.
3. DeBarber AE, Duell PB. Update on cerebrotendinous xanthomatosis. *Curr Opin Lipidol*. 2021; 32(2): 123-31.
4. Cruysberg JR, Wevers RA, van Engelen BG, Pinckers A, van Spreken A, Tolboom JJ. Ocular and systemic manifestations of cerebrotendinous xanthomatosis. *Am J Ophthalmol*. 1995; 120(5): 597-604.
5. Duell PB, Salen G, Eichler FS, DeBarber AE, Connor SL. Diagnosis, treatment, and clinical outcomes in 43 cases with cerebrotendinous xanthomatosis. *J Clin Lipidol*. 2018; 12(5): 1169-78.
6. Pramparo T, Steiner RD, Rodems S, Jenkinson C. Allelic prevalence and geographic distribution of cerebrotendinous xanthomatosis. *Orphanet J Rare Dis*. 2023; 18(1): 13.
7. Huijgen R, Stork AD, Defesche JC, Peter J, Alonso R. Extreme xanthomatosis in patients with both familial hypercholesterolemia and cerebrotendinous xanthomatosis. *Clin Genet*. 2012; 81(1): 24-8.
8. Siebner HR, Berndt S, Conrad B. Cerebrotendinous xanthomatosis without tendon xanthomas mimicking Marinesco-Sjogren syndrome: a case report. *J Neurol Neurosurg Psychiatry*. 1996; 60(5): 582-5.
9. Barkhof F, Verrips A, Wesseling P, van Der Knaap MS, van Engelen BG. Cerebrotendinous xanthomatosis: the spectrum of imaging findings and the correlation with neuropathologic findings. *Radiology*. 2000; 217(3): 869-76.
10. Verrips A, van Engelen BG, Wevers RA, van Geel BM, Cruysberg JR. Presence of diarrhea and absence of tendon xanthomas in patients with cerebrotendinous xanthomatosis. *Arch Neurol*. 2000; 57(4): 520-4.
11. Mignarri A, Gallus GN, Dotti MT, Federico A. A suspicion index for early diagnosis and treatment of cerebrotendinous xanthomatosis. *J Inher Metab Dis*. 2014; 37(3): 421-9.
12. Degos B, Nadjar Y, Amador Mdel M, Lamari F, Sedel F, Roze E, et al. Natural history of cerebrotendinous xanthomatosis: a paediatric disease diagnosed in adulthood. *Orphanet J Rare Dis*. 2016; 11: 41.
13. Stelten BML, Huidekoper HH, van de Warrenburg BPC, Brilstra EH, Hollak CEM. Long-term treatment effect in cerebrotendinous xanthomatosis depends on age at treatment start. *Neurology*. 2019; 92(2): e83-e95.
14. Verrips A, Wevers RA, Van Engelen BG, Keyser A, Wolthers BG. Effect of simvastatin in addition to chenodeoxycholic acid in patients with cerebrotendinous xanthomatosis. *Metabolism*. 1999; 48(2): 233-8.