

ANCA-Associated Vasculitis Masquerading as Refractory Pneumonia: A Diagnostic Challenge and Lessons Learned

Ruidie MA^{1*} and Yingbing ME^{1,2*}

¹Hubei University of Chinese Medicine, Hubei Province, Wuhan 430065, China

²Hubei Provincial Hospital of Traditional Chinese Medicine, Hubei Province, Wuhan 430070, China

***Corresponding author:**

Ruidie MA,
Hubei University of Chinese Medicine,
Hubei Province, Wuhan 430065, China

Received: 03 Dec 2025

Accepted: 12 Dec 2025

Published: 24 Dec 2025

J Short Name: ACMCR

Copyright:

©2025 Ruidie MA. This is an open access article distributed under the terms of the Creative Commons Attribution License, which permits unrestricted use, distribution, and build upon your work non-commercially

Keywords:

ANCA-Associated Vasculitis; Refractory Pneumonia; Anti-Infective Therapy; Misdiagnosis Analysis; Multi-System Involvement

Citation:

Ruidie MA, ANCA-Associated Vasculitis Masquerading as Refractory Pneumonia: A Diagnostic Challenge and Lessons Learned. Ann Clin Med Case Rep® 2025; V15(1): 1-5

1. Abstract

We present the case of a 66-year-old woman hospitalized for a 7-day history of cough, productive sputum, chills, and fever, initially managed as community-acquired pneumonia. Despite aggressive antimicrobial therapy leading to some radiographic improvement, her systemic symptoms persisted and were subsequently compounded by clinical clues suggestive of multi organ involvement. Ultimately, testing for anti-neutrophil cytoplasmic antibodies (ANCA) confirmed a diagnosis of ANCA-associated vasculitis (AAV). This case illustrates how AAV, when primarily manifesting with respiratory symptoms, can be easily mistaken for a common infection. Our systematic analysis of the diagnostic pitfalls underscores a critical clinical insight: in cases of so-called “refractory pneumonia” that defy standard antibiotic regimens, the concomitant presence of sustained systemic inflammation (e.g., marked elevations in interleukin-6, erythrocyte sedimentation rate, and C-reactive protein) and subtle evidence of multi-system disease, especially renal involvement, should prompt immediate consideration of AAV. Early integration of ANCA testing into the diagnostic workup, coupled with a multidisciplinary evaluation, is paramount to enable timely intervention and mitigate the risk of irreversible organ damage, ultimately improving patient outcomes.

2. Introduction

Anti-neutrophil cytoplasmic antibody (ANCA)-associated vasculitis (AAV) encompasses a spectrum of autoimmune disorders characterized by inflammation targeting small and Medium sized vessels [1]. The primary clinical entities include granulomatosis with polyangiitis (GPA), microscopic polyangiitis (MPA), and eosinophilic granulomatosis with polyangiitis (EGPA), with

GPA and MPA constituting the majority (approximately 80-90%) of cases [2,3]. As a systemic disease, AAV can manifest across multiple organ systems. Pulmonary involvement is particularly common and exhibits a striking heterogeneity in presentation—from incidental nodules and indolent pneumonitis to fulminant, life-threatening diffuse alveolar haemorrhage [4-6]. When the initial presentation is dominated by pulmonary inflammation, the clinical and radiological features of AAV can closely mimic those of commonplace conditions like community-acquired pneumonia (CAP) or tuberculosis. This mimicry contributes to significant diagnostic challenges, with studies indicating that nearly 60% of AAV patients experience a prolonged delay in diagnosis [7]. In the context of so-called “refractory pneumonia” unresponsive to empirical antibiotics, the clinical focus often narrows to pursuing resistant pathogens or intensifying antimicrobial regimens, while the potential for an underlying autoimmune aetiology, such as AAV, is inadvertently overlooked. Such diagnostic oversight can have grave consequences, allowing disease progression that culminates in irreversible organ injury, most notably renal failure. This article presents an illustrative case of AAV masquerading as refractory pneumonia. Through this case, we delve into the factors contributing to misdiagnosis, distil key indicators for earlier suspicion, and offer insights to enhance clinical vigilance and diagnostic accuracy.

3. Case Presentation

A 66-year-old woman was hospitalized on August 12, 2025, presenting with a 7-day history of cough, productive sputum, chills, and fever. Her medical history included hypertension, type 2 diabetes mellitus, and hyperlipidaemia. On admission, her temperature was 37.3°C. Physical examination revealed coarse breath

sounds bilaterally without audible rales. Cardiac auscultation noted a regular rhythm with occasional premature beats. Chest computed tomography (CT) demonstrated findings suggestive of a focal infectious process in the posterior basal segment of the left lower lobe, along with a minor pericardial effusion. Initial laboratory investigations revealed leucocytosis ($14.38 \times 10^9/L$) with neutrophilia (84.5%), anaemia (haemoglobin 90 g/L), and an elevated C-reactive protein (CRP) level of 81.07 mg/L. Urinalysis was significant for occult blood (2+), trace protein (\pm), and leukocyte esterase (2+). A provisional diagnosis of community-acquired pneumonia was made, and empirical antibiotic therapy with cooper-zone-sulbactam was commenced.

Her clinical course was marked by persistent intermittent fever and limited symptomatic I'm provident despite initial treatment. Consequently, antimicrobial therapy was intensified to a combination of etoperidone-sulbactam and levofloxacin. This regimen led to only transient fever control. Further laboratory assessment showed significantly elevated inflammatory markers: interleukin-6 (IL-6) at 38.28 pg/mL, erythrocyte sedimentation rate (ESR) at 107 mm/h, and a persistently high CRP level.

The patient subsequently developed new symptoms of palpi-

tations and chest tightness. Cardiac examination at this stage detected a grade 5/6 diastolic rumbling murmur at the apex. Echo-cardio graphic findings were consistent with probable rheumatic heart disease, specifically severe mitral stenosis accompanied by mild regurgitation.

In light of the suboptimal response to aggressive antibiotic therapy and the emergence of clinical features indicative of multi-system involvement (affecting the pulmonary, cardiac, renal [suggested by urinalysis], and haematological systems), an evaluation for systemic vasculitis was undertaken. Anti-neutrophil cytoplasmic antibody (ANCA) testing yielded positive results for perinuclear ANCA (p-ANCA) with a highly elevated anti-myeloperoxidase antibody (MPO-ANCA) titer of >200 RU/mL. These findings confirmed a diagnosis of MPO-ANCA-associated vasculitis (MPO-AAV).

The temporal progression of the patient's body temperature, relevant imaging studies, and key laboratory parameters throughout her hospital course are summarized in Figures 1, 2, 3, and Table 1. Following confirmation of the diagnosis, the therapeutic strategy was shifted to in-duction remission therapy, comprising a combination of glucocorticoids and immunosuppressive agents.

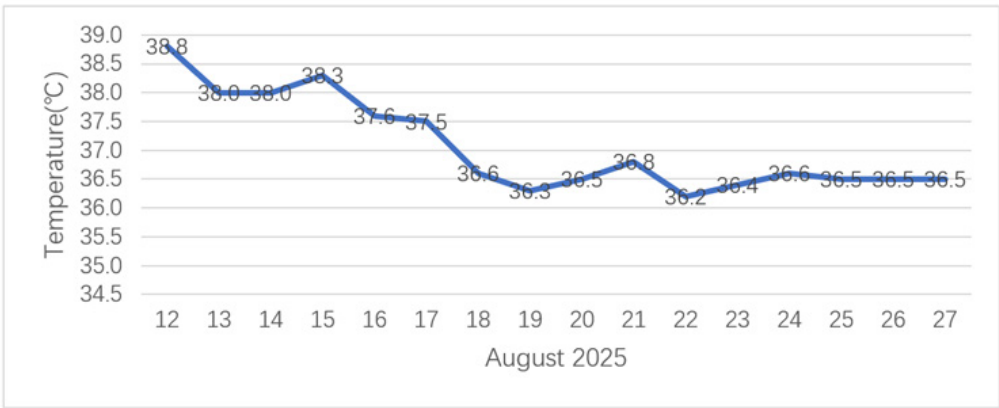


Figure 1: Temperature Change Chart.

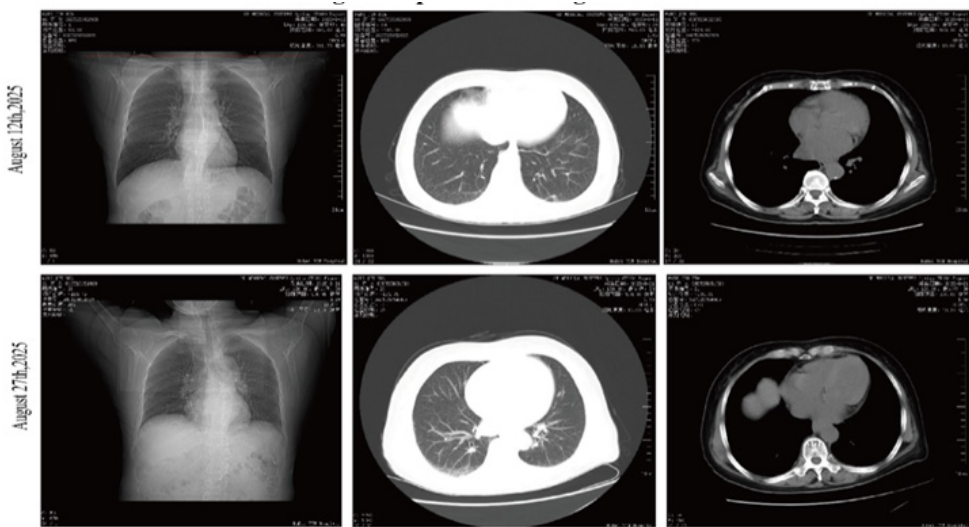


Figure 2: Comparison of Chest CT Scans Before and After Treatment. Left Lower Lobe (Posterobasal Segment, IM168): Possible focal infection. Both Lungs: Low-risk nodules; chronic bronchitis-like changes; minor dependent changes. Cardiovascular: Atherosclerosis of the aorta; calcifications along the coronary artery course; small amount of pericardial effusion.

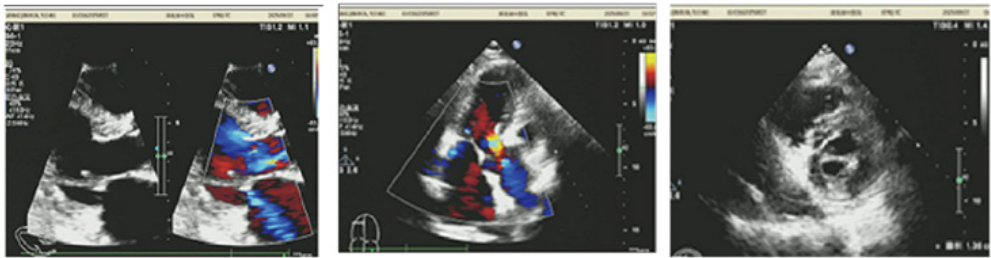

Figure 3: Cardiac Color Doppler Ultrasound. Rheumatic heart disease; Severe mitral stenosis with mild regurgitation; Mild aortic valve regurgitation.

Table 1: Changes in Key Blood Parameters During Treatment.

Category	Date	Aug.12 th	Aug.16 th	Aug.22 th	Aug.27 th
(WBC count (3.5-9.5x10 ⁹ /L		14.38	9.62	10.85	11.37
(Neutrophil Percentage (40-75%		84.5	75.4	77.8	84.5
(Lymphocyte Percentage (20-50%		6.2	14.2	14	8.9
(Hemoglobin (115-150g/L		90	85	84	84
(High-sensitivity C-Reactive Protein (0-4mg/L		81.07	48.75	41.96	58.47
(Estimated Glomerular Filtration Rate (>90mL/min/1.73m ²		78.7	85.6	-	-
(Interleukin-6(<7pg/mL		-	-	38.28	-
(Erythrocyte Sedimentation Rate (0-20mm/h		-	-	107	-

4. Discussion

4.1. Analysis of Misdiagnosis Causes

The elusive and non-specific character of AAV. AAV is a systemic immune-mediated disorder defined by inflammatory and necrotizing damage to the vascular wall [8]. The constellation of its systemic symptoms-including fever, malaise, night sweats, and unintended weight loss-often renders it clinically indistinguishable from infectious or malignant processes [5,9]. Pulmonary involvement in AAV is frequently characterized pathologically by alveolar capillaryitis, which radiologically translates into a spectrum of findings such as multiple cavitating nodules, focal or diffuse consolidations, and ground-glass opacities [10]. Notably, the lungs represent one of the most commonly affected organs in AAV, and the resulting respiratory symptoms can closely mimic those of conventional pulmonary infections [11]. In the present case, the initial chest CT revealed merely a focal infiltrate in the left lower lobe, devoid of more suggestive radiological clues to vasculitis-such as the “reversed halo sign” or “crazy-paving appearance.” [12]. This paucity of specific imaging features naturally steered the diagnostic focus toward pneumonia, inadvertently postponing the identification and appropriate management of the underlying vasculitis process.

The misleading nature of initial presentation and lab works. At admission, the patient’s prominent respiratory symptoms, coupled with laboratory findings of elevated WBC and GRAN% classic markers suggestive of bacterial infection created a compelling but potentially deceptive clinical picture. This convergence of symptoms and objective data naturally channelled diagnostic reasoning toward the most prevalent explanation:

community-acquired pneumonia. Even when subsequent, more specific microbiological investigations (including respiratory pathogen panels, multiplex PCR assays, and sputum cultures) returned negative, the persistence of elevated inflammatory markers perpetuated the assumption of a “culture-negative refractory infection.” This led to a cycle of escalating or switching antibiotic regimens, rather than a fundamental re-evaluation of the diagnostic premise itself.

Diagnostic bias from patient age and comorbidities. AAV is a protean systemic disorder capable of affecting virtually any organ system, resulting in a vast and heterogeneous array of symptoms that often mimic other diseases. This chameleon-like quality necessitates a broad differential diagnosis to unmask its true nature [13]. In this elderly patient with multiple chronic conditions, the clinical tableau was inherently complex. Adherence to the principle of Occam’s razor-the preference for a single, unifying diagnosis-unintentionally narrowed the diagnostic vision. This cognitive bias delayed the necessary expansion of the differential to include systemic autoimmune conditions like AAV.

Overlooked Diagnostic Clues and Delayed Definitive Testing. Several early clues pointing toward a systemic vasculitis were either minimized or misinterpreted. First, renal involvement: The early findings of microscopic haematuria, pyuria, and a subtly reduced estimated glomerular filtration rate (eGFR) are sensitive harbingers of renal disease in AAV, indicative of active glomerulonephritis.[9] Within the dominant pneumonia narrative, however, these were dismissed or ascribed to incidental or secondary causes. Concurrent anaemia, another common albeit non-specific feature in AAV, was also present; a drop in haemoglobin can sometimes signal occult alveolar haemorrhage

[13]. Second, delayed serological confirmation: Testing for Anti Neutrophil Cytoplasmic Antibodies (ANCA), the cornerstone serological marker for AAV, was regrettably postponed until multi-organ involvement became apparent and antibiotic therapy had demonstrably failed [14]. This delay underscores a critical gap in clinical vigilance: the under-recognition of ANCA testing's vital role as a screening tool in complex, treatment-resistant presentations.

4.2. Diagnostic Implications and Strategies for Early Detection

The imperative for early diagnosis and timely, appropriate intervention in AAV cannot be overstated, as it is pivotal in averting irreversible end-organ damage [15]. In the context of patients with unexplained respiratory symptoms, diffuse pulmonary infiltrates, and resistance to conventional antibiotic regimens, AAV must be actively considered in the differential diagnosis. A fundamental shift in clinical mindset is required: so-called "refractory pneumonia" should be viewed not as a diagnostic endpoint, but as a critical red flag prompting a broader investigation. A systematic workup for non-infectious inflammatory etiologies, prominently featuring AAV, is mandatory when pneumonia is accompanied by: (1) negligible clinical or radiological improvement or frank deterioration despite 1-2 weeks of adequate, broad-spectrum antimicrobial therapy; (2) persistently negative microbiological studies; (3) markedly elevated systemic inflammatory markers (e.g., CRP, ESR) disproportionate to or unexplained by infection alone; (4) subtle or overt clues of concomitant involvement of other organ systems, such as renal, cardiac, dermatological, neurological, or ENT.

Given the profound heterogeneity of AAV presentations, a structured, stepwise diagnostic algorithm is essential. Step 1: Clinical Vigilance. The diagnostic journey begins with a high index of suspicion based on the clinical picture. The emergence of symptoms suggestive of multi system disease—for instance, microscopic haematuria (renal), pericarditis/myocarditis (cardiac), palpable purpura (dermatological), mononeuritis multiplex (neurological), or refractory sinusitis/otitis (ENT) should immediately elevate AAV to a leading diagnostic possibility [16-21]. Step 2: Serological Screening. Subsequent evaluation hinges on serological testing. Serum ANCA analysis, encompassing both indirect immunofluorescence (IIF, detecting c-ANCA/p-ANCA patterns) and antigen-specific assays (for PR3-ANCA and MPO-ANCA), serves as the cornerstone screening tool, providing vital diagnostic and classificatory clues [22]. Step 3: Histopathological Confirmation. For cases with atypical features, negative serology, or when precise assessment of disease activity and chronicity is required, tissue biopsy remains the diagnostic gold standard. Histopathological examination of affected tissue—most commonly kidney, but also lung, skin, or nerve—can yield definitive evidence of pauci-immune necrotizing vasculitis or granulomatous inflammation [9].

In conclusion, a definitive diagnosis of AAV integrates clinical suspicion, supportive serology, compatible imaging, and, when

needed, confirmatory histopathology, all while rigorously excluding mimickers such as infection, malignancy, or other vasculitis's. Once diagnosed, prompt initiation of induction remission therapy—typically based on glucocorticoids combined with cyclophosphamide or rituximab—is critical. Optimal management necessitates a collaborative, multidisciplinary approach involving rheumatology, nephrology, pulmonology, and often other specialties to address the systemic nature of the disease and improve long-term outcomes [23].

5. Conclusion

In this case, AAV masquerading as refractory pneumonia led to diagnostic delay, attributable to its atypical presentation, a narrowed diagnostic focus, and postponement of definitive testing. This experience underscores a critical lesson: refractory pneumonia should not be accepted as a final diagnosis, but rather as a pivotal clinical alert demanding an expanded diagnostic framework. It compels clinicians to maintain a high index of suspicion for underlying systemic autoimmune disorders like AAV. The pathway to accurate and timely diagnosis hinges on several concerted actions: recognizing the diverse and often deceptive pulmonary manifestations of AAV; meticulously hunting for subtle, extra-pulmonary clues pointing to multi-system disease; implementing early serological screening, particularly ANCA testing; and pursuing confirmatory tissue biopsy when indicated. Prompt commencement of appropriate induction and maintenance immunosuppressive therapy is essential to halt disease progression, avert permanent organ injury, and secure favourable long-term outcomes. Finally, the intricate management of AAV necessitates a robust, multidisciplinary team approach, integrating expertise across specialties to navigate the complexities of this systemic illness.

References

1. Yaseen K, Mandell BF. ANCA associated vasculitis (AAV): a review for internists. *Postgrad Med.* 2023;135(sup1):3-13.
2. Casal Moura M, Merkel PA, Jayne D. Challenges in the diagnosis, classification and prognosis of ANCA-associated vasculitis. *Nat Rev Rheumatol.* 2025; 21(12): 719-736.
3. Kitching AR, Anders HJ, Basu N. ANCA-associated vasculitis. *Nat Rev Dis Primers.* 2020; 6(1): 71.
4. Wallace ZS, Fu X, Harkness T. All-cause and cause-specific mortality in AN-CA-associated vasculitis: overall and according to ANCA type. *Rheumatology (Oxford).* 2020; 59(9): 2308-2315.
5. Chevet B, Cornec D, Casal Moura M. Diagnosing and treating ANCA-associated vasculitis: an updated review for clinical practice. *Rheumatology (Oxford).* 2023; 62(5): 1787-1803.
6. Fussner LA, Flores-Suárez LF, Cartin-Ceba R. Alveolar Hemorrhage in Antineutrophil Cytoplasmic Antibody-Associated Vasculitis: Results of an International Randomized Controlled Trial (PEXIVAS). *Am J Respir Crit Care Med.* 2024; 209(9): 1141-1151.
7. Sreih AG, Cronin K, Shaw DG. Diagnostic delays in vasculitis and factors associated with time to diagnosis. *Orphanet J Rare Dis.* 2021; 16(1): 184.

8. Wortel CM, van de Wetering R. Anti-myeloperoxidase IgM B cells in an-ti-neutrophil cytoplasmic antibody-associated vasculitis. *Nat Commun.* 2025; 16(1): 1582.
9. Hunter RW, Welsh N, Farrah TE. ANCA associated vasculitis. *BMJ.* 2020; 369: m1070.
10. Elgueta F, Wurmman P, Mac-Namara M, Grandjean J, Ardiles L. Compromiso pulmonar en vasculitis asociadas a anticuerpos anticitoplasma de neutrófilos [Pulmonary manifestations of anti-neutrophil cytoplasmic antibody associated vasculitis]. *Rev Med Chil.* 2022; 150(4): 505-511.
11. Luo W, Liu C, Zhang L. Characteristics and risk factors for infection in patients with ANCA-associated vasculitis: A systematic review and meta-analysis. *Autoimmun Rev.* 2025; 24(2): 103713.
12. Godoy MC, Viswanathan C, Marchiori E. The reversed halo sign: update and differential diagnosis. *Br J Radiol.* 2012; 85(1017): 1226-1235.
13. Kronbichler A, Bajema IM, Bruchfeld A. Diagnosis and management of AN-CA-associated vasculitis. *Lancet.* 2024; 403(10427): 683-698.
14. Sinico RA, Radice A. Antineutrophil cytoplasmic antibodies (ANCA) testing: detection methods and clinical application. *Clin Exp Rheumatol.* 2014; 32(3 Suppl 82): S112-S117.
15. Alberici F, Flossmann O, Lamprecht P. Antineutrophil cytoplasmic anti-body-associated vasculitis: insights into relapse risk and future management directions. *Front Immunol.* 2025; 16: 1655326.
16. Benichou N, Charles P, Terrier B. Proteinuria and hematuria after remission induction are associated with outcome in ANCA-associated vasculitis. *Kidney Int.* 2023; 103(6): 1144-1155.
17. Sarmad A, Gholizadeh Ghouloujeh Z, Hanna PE. Cardiovascular involvement in ANCA-associated vasculitis. *Nephrol Dial Transplant.* 2025; 40(12): 2256-2267.
18. Shakshouk H, Gibson LE. Cutaneous manifestations of ANCA-associated vasculitis: a retrospective review of 211 cases with emphasis on clinicopathologic correlation and ANCA status. *Int J Dermatol.* 2023; 62(2): 231-238.
19. Koike H, Nishi R, Ohshima K. ANCA-Associated Vasculitic Neuropathies: A Review. *Neurol Ther.* 2022; 11(1): 21-38.
20. Fernandes-Serodio J, Prieto-González S, Espígol-Frigolé G. Significance of clinical-immunological patterns and diagnostic yield of biopsies in microscopic polyangiitis and granulomatosis with polyangiitis. *J Intern Med.* 2024; 295(5): 651-667.
21. Yang R, Xu Z, He X. The Clinical Features of Otitis Media with Antineutrophil Cytoplasmic Antibody-Associated Vasculitis and the Role of Routine Blood Tests in Its Diagnosis. *Ear Nose Throat J.* Published online. 2025.
22. Guchelaar NAD, Waling MM, Adhin AA. The value of anti-neutrophil cytoplasmic antibodies (ANCA) testing for the diagnosis of ANCA-associated vasculitis, a systematic review and meta-analysis. *Autoimmun Rev.* 2021; 20(1): 102716.
23. Trivioli G, Casal Moura M, Kronbichler A. Advances in the treatment of AN-CA-associated vasculitis. *Nat Rev Rheumatol.* 2025; 21(7): 396-413.