

Schistosomiasis Presenting as A Liver Mass in A Resident of Türkiye Without Overseas Travel: A Case-Based Review Running Title: Schistosomiasis Presenting as A Liver Mass in A Resident of Türkiye

Sonat Pınar Kara¹, Nazan Tuna², Dilara Bulut Gokten^{3*}, Meltem Oznur⁴ and Nurten Turkel Kucukmetin⁵

¹Department of Internal Medicine, Tekirdag Namik Kemal University, Tekirdag, Turkey

²Department of Infectious Diseases and Clinical Microbiology, Tekirdag Namik Kemal University, Tekirdag, Turkey

³Division of Rheumatology, Department of Internal Medicine, Tekirdag Namik Kemal University, Tekirdag, Turkey

⁴Department of Pathology, Tekirdag Namik Kemal University, Tekirdag, Turkey

⁵Division of Gastroenterology, Department of Internal Medicine, Tekirdag Namik Kemal University, Tekirdag, Turkey

*Corresponding author:

Dilara Bulut Gokten,
Division of Rheumatology, Department of
Internal Medicine, Tekirdag Namik Kemal
University, Tekirdag, Turkey

Received: 08 Aug 2025

Accepted: 29 Aug 2025

Published: 09 Sep 2025

J Short Name: ACMCR

Copyright:

©2025 Dilara Bulut Gokten. This is an open access article distributed under the terms of the Creative Commons Attribution License, which permits unrestricted use, distribution, and build upon your work non-commercially

Keywords:

Hepatic Schistosomiasis; Non-Endemic Region; Schistosomiasis

Citation:

Dilara Bulut Gokten, Schistosomiasis Presenting as A Liver Mass in A Resident of Türkiye Without Overseas Travel: A Case-Based Review Running Title: Schistosomiasis Presenting as A Liver Mass in A Resident of Türkiye. Ann Clin Med Case Rep® 2025; V15(1): 1-7

1. Abstract

Schistosomiasis is a parasitic disease commonly found in endemic regions such as sub-Saharan Africa, the Middle East, and parts of Asia. However, cases in non-endemic countries like Türkiye are extremely rare and typically linked to travel or migration. This case-based review presents a unique instance of hepatic schistosomiasis in a 47-year-old Turkish male with no history of overseas travel or exposure to endemic areas. The patient exhibited constitutional symptoms and was initially evaluated for a hepatic mass suspicious for malignancy. Despite extensive work-up, including imaging, serologic tests, and liver biopsies, the diagnosis remained elusive until *Schistosoma* ova were detected in urine microscopy. The patient responded favourably to praziquantel therapy, with clinical and radiologic improvement over six months. This case underscores the diagnostic challenges posed by schistosomiasis in non-endemic settings and highlights the importance of considering parasitic infections in the differential diagnosis of hepatic granulomatous inflammation. To the best of our knowledge, this represents one of the first confirmed cases of liver schistosomiasis acquired within Türkiye without international travel. Increased awareness among clinicians is essential for timely diagnosis and management of such atypical presentations in non-endemic regions.

2. Introduction

Schistosomiasis, also referred to as bilharziasis, was first de-

scribed in 1852 by German surgeon Theodor Bilharz, who identified the parasite during autopsies conducted in Egypt [1]. Schistosomiasis is a tropical disease caused by trematodes of the *Schistosoma* genus. Although the parasite is most prevalent in sub-Saharan Africa, it is also endemic in parts of South America, the Caribbean, the Middle East, and certain regions of Asia. In non-endemic areas, cases are occasionally encountered as a result of international travel, migration, or tourism [2]. According to estimates, approximately 230 million people, 85% of whom reside in Africa, are infected. The disease is estimated to cause up to 280,000 deaths annually and is recognized as the second most common parasitic infection in humans after malaria [3]. The parasite can affect multiple organs, including the urethra, liver, bladder, intestines, skin, and bile ducts. Potential complications include renal failure, bladder cancer, hydronephrosis, portal hypertension, gastrointestinal bleeding, and, in severe cases, subsequent development of shock [4]. Six primary *Schistosoma* species are known to infect humans: *S. japonicum*, *S. mansoni*, *S. haematobium*, *S. intercalatum*, *S. mekongi*, and *S. malayensis*. Among these, the first three are responsible for the majority of intestinal and urogenital schistosomiasis cases. *Schistosoma haematobium*, the species associated with urogenital schistosomiasis (UGS), derives its name from its hallmark feature, hematuria, and is considered the second most common cause of bladder cancer worldwide [5]. Hepatosplenic schistosomiasis (HSS) is characterized by inflammation and fibrosis of

the presinusoidal portal tracts within the liver [6]. The primary *Schistosoma* species responsible for hepatobiliary disease are *S. mansoni* and *S. japonicum*. Clinically, affected individuals may present with hepatomegaly, hepatic fibrosis, and presinusoidal obstruction of portal blood flow, accompanied by increased splenic venous return leading to portal hypertension and splenomegaly. In the compensated stage, laboratory findings are typically normal or only mildly abnormal. In more advanced cases, complications such as esophageal varices, ascites and hematemesis may occur [7]. Although schistosomiasis is a common parasitic infection globally, Türkiye is considered a non-endemic region, and cases are rarely encountered. This case report presents a patient with hepatic schistosomiasis, initially investigated for a granulomatous liver lesion mimicking malignancy, despite having no history of international travel or residence in endemic regions.

3. Case Presentation

A 47-year-old male patient with a history of benign left adrenal adenoma and hepatitis B carriage presented to an external clinic with a six-month history of recurrent fever, night sweats, fatigue, and unintentional weight loss of 22 kg. One year ago, when the patient was initiated on steroid therapy for rheumatoid arthritis, antiviral prophylaxis for hepatitis B was also started. The patient was prescribed tenofovir disoproxil fumarate (245 mg, once daily). He had been working in a grocery warehouse under potentially unhygienic conditions and denied any recent travel, known parasitic exposure, or contact with infected individuals. Initial evaluation was prompted by persistent constitutional symptoms and the detection of a liver mass on ultrasonography. Contrast-enhanced abdominal computed tomography (CT) revealed a hypodense lesion measuring approximately 10×12 cm in the right hepatic lobe. Serum tumor markers were within normal limits. Upper gastrointestinal endoscopy was unremarkable. A liver biopsy was performed at the external center due to the patient's chronic hepatitis B carriage and detectable HBV DNA level, given the associated risk for hepatocellular carcinoma (HCC). Histopathological evaluation excluded malignancy and instead revealed nodular formations composed of fibrotic connective tissue with central necrosis, peripheral granulomatous reaction, and a dense inflammatory cell infiltrate. The overall findings were interpreted as necrotizing granulomatous inflammation. Based on the information obtained from the external medical records, the differential diagnosis included tuberculosis, fungal infections, sarcoidosis, and malignancy. Despite comprehensive microbiological and immunological testing, including serologic assays and polymerase chain reaction (PCR) analyses for tuberculosis, brucellosis, toxoplasmosis, echinococcus, histoplasmosis, HIV, and other granulomatous diseases, no definitive etiology was identified. The patient's symptoms continued to worsen, prompting referral to our tertiary care facility due to progressive clinical decline marked by recurrent high-grade fevers, hypotension, and profound fatigue. On presentation to the emergency department, he was hypotensive with a blood pres-

sure of 90/60 mmHg and febrile at 39.2°C. Laboratory testing revealed normocytic anemia with a hemoglobin level of 7.7 g/dL (reference: 13.5–17.5 g/dL), thrombocytopenia with a platelet count of 69.10³/μL (reference: 150–400.10³/μL), and leukocytosis with neutrophilic predominance. C-reactive protein (CRP) was markedly elevated at 142.4 mg/L (reference: 0–5 mg/L), and D-dimer was increased to 6.75 mg/L (reference: 0–0.55 mg/L). The international normalized ratio (INR) was slightly prolonged at 1.44 (reference: 0.8–1.3), and liver transaminases were in normal range. Serum albumin was notably decreased at 1.8 g/dL (reference: 3.5–5.0 g/dL). Cholestatic enzyme levels were increased, with gamma-glutamyl transferase (GGT) at 318 U/L (reference: 8–61 U/L) and alkaline phosphatase (ALP) at 543 U/L (reference: 40–130 U/L). Serum tumor marker analysis revealed elevated levels of CA 19-9 at 62.35 U/mL (reference: 0–37 U/mL) and CA 125 at 68.12 U/mL (reference: 0–35 U/mL), while alpha-fetoprotein (AFP) was within the normal range at 0.76 ng/mL (reference: 0–8.5 ng/mL). Real-time (RT)-PCR was used to quantify hepatitis B virus (HBV) DNA in the patient, who was hepatitis B surface antigen (HBsAg) positive. The HBV DNA level was measured as 43 IU/mL. Angiotensin-converting enzyme (ACE) levels were within normal limits, and the autoimmune hepatitis panel was negative. Serologic tests for hydatid disease, brucellosis, syphilis and *Coxiella burnetii* were also negative. In addition, tests for *Rickettsia*, galactomannan antigen, and Epstein–Barr virus were unremarkable. Tuberculosis workup, including PCR, sputum acid-fast bacilli (AFB) staining, and *Mycobacterium tuberculosis* culture, yielded negative results. Both the quantiferon assay and purified protein derivative (PPD) skin test were non-reactive. Blood, urine, and sputum cultures were obtained, and empirical antibiotic therapy with meropenem, vancomycin, and doxycycline was initiated. Contrast-enhanced abdominal magnetic resonance imaging (MRI) revealed a progressively enlarging hepatic lesion with ill-defined borders and internal heterogeneity, measuring approximately 15×13×7 cm and occupying most of the right hepatic lobe. The liver was enlarged, measuring 229 mm in craniocaudal length, and showed irregular contours with imaging findings suggestive of fibrosis. The spleen was also enlarged, with a longitudinal diameter of 15 cm. Additionally, a fluid collection measuring 6×2.5 cm was detected in the posterior region between the liver and the right kidney. Given the lack of clinical improvement and the diagnosis of chronic hepatitis B, which strengthens the initial suspicion of HCC, a second liver biopsy was performed. Histopathological analysis once again demonstrated chronic necrotizing granulomatous inflammation, with no evidence of malignancy (see Figure 1). **Urine microscopy, repeated on two separate occasions, revealed the presence of *Schistosoma* ova (see Figure 2).** Following consultation with the infectious diseases team, schistosomiasis was considered the most probable diagnosis, and antiparasitic therapy with praziquantel was initiated after obtaining the medication through international procurement (40 mg/kg/day oral). Broad-spectrum

antibiotics were discontinued. Subsequently, the patient's fever gradually resolved, inflammatory markers declined, and his overall clinical condition improved in seven days. As his hemodynamic parameters stabilized, he was transferred from the intensive care unit to the internal medicine ward. Despite evidence of advanced hepatic involvement and features of portal hypertension, liver function remained preserved throughout the course of hospitalization. No signs of hepatic encephalopathy, jaundice, esophageal varices, or gastrointestinal bleeding were observed. Imaging performed three months after the initiation of treatment

demonstrated a decrease in the size of the hepatic lesion, now measuring approximately 10×7 cm, with less defined margins and reduced conspicuity. Due to the persistence of the hepatic lesion, a second course of treatment was administered at a dose of 60 mg/kg orally. At the 6-month follow-up, both laboratory parameters and imaging findings had normalized, with complete resolution of the hepatic mass (see Figure 3). Serum albumin was 4.2 g/dL, C-reactive protein was 2.1 mg/L, and all other routine biochemical parameters were within normal limits. No parasitic ova were detected on urine microscopy.

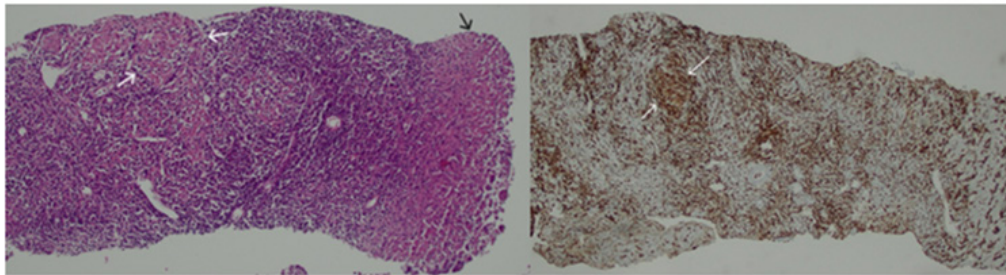


Figure 1: Histopathological examination of the liver tissue (black arrow) demonstrates a granuloma (white arrow), stained with hematoxylin and eosin (H&E) ($\times 100$). Immunohistochemical staining with CD68 highlights the granuloma (white arrow) in the same tissue section ($\times 100$).

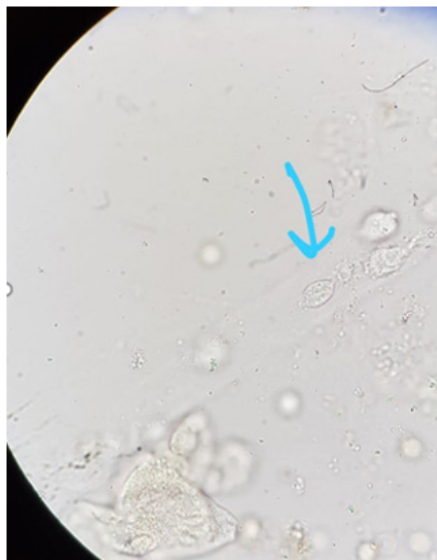

Figure 2: Urine microscopy, repeated on two separate occasions, revealed the presence of *Schistosoma* ova.

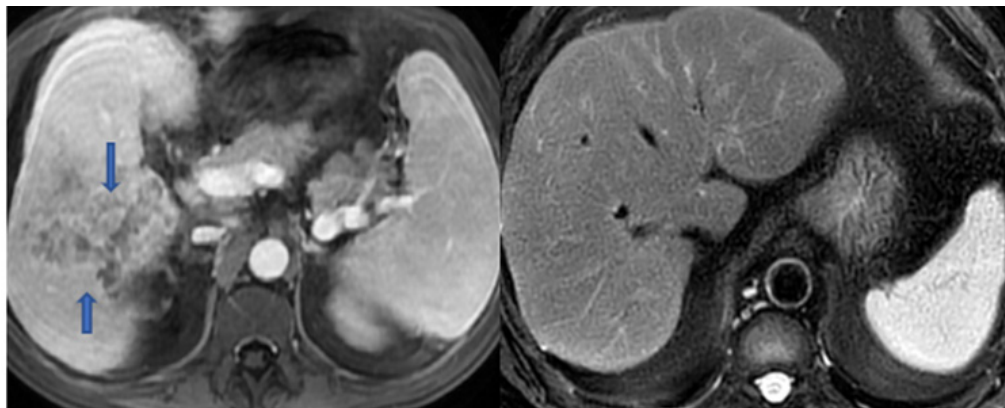


Figure 3: Contrast-enhanced abdominal magnetic resonance imaging (MRI) revealed a progressively enlarging hepatic lesion with ill-defined borders and internal heterogeneity, measuring approximately 15×13×7 cm (arrows). The liver was enlarged, measuring 229 mm in craniocaudal length. The spleen was also enlarged, with a longitudinal diameter of 15 cm. At the 6-month follow-up, imaging showed complete resolution of the hepatic mass and normalization of liver and spleen size.

4. Discussion

As far as can be determined from the current literature, this is one of the first documented case of liver schistosomiasis in Türkiye in a patient without a history of travel to endemic regions. Although schistosomiasis is globally widespread, Türkiye is classified as a non-endemic country, and all previously published cases have involved individuals who acquired the infection abroad. Nearly all of these imported cases were related to *Schistosoma haematobium* and presented with urogenital involvement. Unlike those reports, the current case is notable for its hepatic manifestation of schistosomiasis, making it rare and challenging. Human schistosomiasis occurs through contact with immature parasites in freshwater. After penetrating the skin, they reach the liver via the bloodstream, where they settle in the portal venous system, and produce eggs. The eggs are excreted into the environment through stool and urine [8]. Larvae emerging from eggs hatched in freshwater infect freshwater snails [9]. Within a few weeks, these larvae leave the snails and re-enter the water, seeking a new human host [10]. *Schistosoma* eggs become embedded in tissues, eliciting a strong immune response characterized by granuloma formation promoting surrounding fibrosis. Hepatobiliary schistosomiasis (HSS) is an immune-mediated disease marked by granulomatous inflammation and fibrosis in the presinusoidal portal areas [11]. Histologically, fibrosis is observed in the branches of the portal vein. In the current case, two separate liver biopsies revealed necrotizing granulomatous inflammation, and the histopathological findings were consistent with schistosomiasis. Periportal collagen accumulation obstructs portal blood flow, leading to the development of portal hypertension. Clinical manifestations may include splenomegaly, hypersplenism, and variceal formation [7]. In the present case, the presence of splenomegaly supported the diagnosis of portal hypertension, although no evidence of esophageal varices or gastrointestinal bleeding was observed. In the early stages of hepatic schistosomiasis, a Th1-dominant immune response is observed, while a subsequent shift to a Th2 cytokine profile helps limit inflammation and protects against hepatocyte damage [7]. Therefore, unlike cirrhosis, patients with chronic liver disease due to schistosomiasis typically lack overt clinical signs, and hepatic synthetic functions are generally preserved [10, 12]. Indeed, in the present case, liver function tests were largely preserved, and there were no signs suggestive of decompensated cirrhosis. Definitive diagnosis of schistosomiasis relies on a combination of diagnostic tools, including microscopic detection of eggs, serological tests, and radiological findings. Nonspecific laboratory abnormalities may also be present, such as thrombocytopenia due to splenic involvement, and anemia related to chronic blood loss, as observed in the current case [13]. The most commonly used diagnostic method is the detection of parasite eggs in stool or urine samples. In addition, the use of anti-*Schistosoma mansoni* IgG ELISA serology enhances diagnostic sensitivity [14]. For early-stage diagnosis of schistosomiasis, PCR detection of circulating parasite DNA is a valuable. However, under current conditions, PCR was not available in our country [15].

According to the study by Bezerra et al., magnetic resonance imaging (MRI) is highly useful in differentiating chronic hepatic schistosomiasis from cirrhosis [16]. Radiologic features characteristic of chronic hepatic schistosomiasis include peripheral portal fibrosis, hepatomegaly, splenomegaly, and parenchymal heterogeneity of the liver, all of which were also observed in the present case [17]. The primary goal of treatment in hepatic schistosomiasis is parasite eradication, which reduces the egg burden and helps prevent chronic complications such as fibrosis and portal hypertension. The first-line therapy is praziquantel, an effective, low-cost, and generally well-tolerated agent [18]. A single dose of praziquantel typically achieves a cure rate of 70–100%; in cases of treatment failure, a second dose may be administered. In the present case, an initial course was given with partial regression observed, followed by a second course that resulted in a complete therapeutic response. Co-infection with *Schistosoma* and hepatitis B virus (HBV) represents a significant clinical concern, as it may negatively impact the course of liver disease [19,20]. Studies have reported higher rates of HBsAg carriage among patients with schistosomiasis, with this co-infection linked to more severe hepatic inflammation and faster disease progression [21]. In several published reports, patients with chronic hepatitis B infection, including those with detectable HBV DNA levels, were unexpectedly found to have concurrent schistosomal involvement on liver biopsy. In such cases, parasitic eggs were identified within granulomatous lesions, suggesting that schistosomiasis may exacerbate liver inflammation [19,22]. Similarly, in this case, although the patient was diagnosed with chronic hepatitis B, no histological findings of HCC were detected. In the literature, when examining cases reported from Türkiye, one case from 2022 described a Guinean male who was initially misdiagnosed with ulcerative colitis after developing bloody diarrhea following travel to South Africa. Treatment was ineffective, and subsequent colon biopsy revealed *Schistosoma mansoni* eggs and granulomas [23]. In a second case, a male underwent liver resection for suspected metastatic adenocarcinoma. However, histopathology revealed *Schistosoma* eggs within the tumor tissue. Apart from travel to Korea during the war, an area not considered endemic, no other visits to endemic regions were reported [24]. Another case involved a male from Mali diagnosed with urinary schistosomiasis. The patient had hematuria, and a biopsy of a bladder wall lesion revealed *Schistosoma haematobium* eggs [25]. In a similar case, a male developed terminal hematuria after returning to Türkiye. He had traveled to Guinea and Mali. Vesical schistosomiasis was diagnosed [26]. In the case presented, there was no history of travel to endemic areas. In Türkiye, it is mostly seen as sporadic cases, but rarely it has been found endemic in some villages along the streams in the Nusaybin district of Mardin [27]. In recent years, an increase in tropical diseases has been observed due to wars and migrations. Bingül et al. reported a 7-year-old boy with no known risk factors who underwent excision of a growing lower lip hemangioma. Histopathology revealed numerous *Schistosoma mansoni* larvae within the hemangioma

tissue [28]. In another case, a male with no history of travel to endemic areas presented with gross hematuria. A bladder tumour was detected, and histopathological examination revealed urothelial carcinoma along with *Schistosoma mansoni* eggs. The carcinoma was attributed to the parasitic infection [29]. Yazar et al. reported two *Schistosoma haematobium* cases in Nigerian and Ghanaian students residing in Türkiye, both presenting with hematuria and confirmed by detection of eggs in urine [30,31]. A 2009 report described three Turkish men who developed urinary schistosomiasis after business trip to Mali. They presented with

hematuria and *Schistosoma haematobium* eggs were identified [32]. The first reported case of *Schistosoma* infection following bone marrow transplantation (BMT) in the literature is from Türkiye. It involved a male who underwent allogeneic BMT for acute myeloid leukemia. After transplantation, he developed portal hypertension and hematuria, and *Schistosoma mansoni* eggs were detected in both stool and urine samples [21]. Finally, Özvatan et al. reported a case of urinary schistosomiasis in a male patient who had worked in Cameroon, Guinea, and Mali [27] (see Table 1).

Table 1: Summary of Reported Schistosomiasis Cases in Türkiye: Demographics, Clinical Features, and Diagnostic Methods.

Author (year)	Age/sex	Nation	Affected Region	Species/Egg Type	Clinical Presentation	Risk Factor/Travel	Diagnosis	Treatment	Other Notes
Kiremit et al. (2015)	67- male	Turkish	Bladder	<i>S. mansoni</i> / egg	Macroscopic hematuria, bladder tumor	No history of travel	Histopathology (eggs and TCC in TUR specimen)	Praziquantel 40 mg orally, intravesical immunotherapy	Bladder carcinoma associated with <i>S. mansoni</i> ; rare in the literature
Ak et al. (2022)	26 / male	Guinean nationality, residing in Türkiye	Colon	<i>S. mansoni</i> / egg	Bloody diarrhea, abdominal pain and weight loss	Visit to South Africa	Colon biopsy	Praziquantel 40 mg/kg single dose	The initial diagnosis was ulcerative colitis; the correct diagnosis was made upon histopathological reevaluation
Sağol et al. (2013)	67 / male	Turkish	Liver	<i>S. mansoni</i> / egg	Liver resection due to suspected metastasis	Visit to Korea (non-endemic area)	Histopathology (resection specimen)	Unspecified	Eggs detected within the tumor tissue
Yılmaz et al. (2024)	20 / male	Malian nationality, residing in Türkiye	Bladder	<i>S. haematobium</i> / egg	Intermittent hematuria	History of living in Mali	Bladder biopsy, urine microscopy	Praziquantel (2 × 40 mg/kg)	Symptoms regressed after treatment; the patient returned to their home country before follow-up
Aytaç (2012)	37 / male	Turkish	Bladder	<i>S. haematobium</i> / egg	Terminal hematuria, irritative voiding	Work trip to Guinea and Mali (five years ago, stayed for six months)	Urine cytology, bladder biopsy	Praziquantel (2 × 25 mg/kg, single day)	Non-caseating granulomas and clusters of eggs on histopathology; symptoms began 1 month after travel.
Bingül et al. (2005)	7 / male	Turkish	Lower lip, hemangioma tissue	<i>S. mansoni</i> / larva	Congenital hemangioma	No history of travel	Histopathological examination of the excised hemangioma tissue	Single dose of praziquantel (800 mg)	First reported case of <i>Schistosoma</i> within a hemangioma in the literature; eggs were not detected in stool or urine.

Yazar et al. (2010)	17 / male	Nigerian, in Türkiye as a student	Bladder	<i>S. haematobium</i> / egg	Hematuria and dysuria for seven years	History of swimming in a pond in Nigeria	Urine microscopy	Praziquantel 40 mg/kg single dose	Symptoms resolved after treatment; no eggs detected at follow-up
Yazar et al. (2008)	16 / male	Ghanaian, in Türkiye as a student	Bladder	<i>S. haematobium</i> / egg	Terminal hematuria for two years	Born and raised in Ghana, an endemic region	Urine microscopy	Praziquantel was planned but not provided	Return to home country was recommended; preventive measures against transmission were advised
Gül et al. (2009)	32, 35, 40 / male	Turkish / Malian	Bladder	<i>S. haematobium</i> / egg	Hematuria, fever, back and muscle pain	Visit to Mali, swimming in the Niger River	Urine microscopy, bladder biopsy	Praziquantel 40 mg/kg orally, single dose	No recurrence at 12-month follow-up
Yalçın et al. (1999)	28 / male	Turkish	Bladder and liver	<i>S. mansoni</i> / egg	Portal hypertension, hematuria (post bone marrow transplant)	Unspecified	Stool and urine microscopy	Stool and urine microscopy	Post-allogeneic stem cell transplantation case
Özvatan et al. (2011)	37 / male	Turkish	Bladder	<i>S. haematobium</i> / egg	Hematuria at the end of micturition, bladder lesion	Worked near ponds in Cameroon, Guinea, and Mali for six months	Urine microscopy	Praziquantel 1650 mg	Diagnosis made after TUR; symptoms began five years later

5. Conclusion

In regions where schistosomiasis is not typically encountered, the presence of a liver mass in a patient with elevated HBV DNA levels may lead clinicians to prioritize malignancy in the differential diagnosis. However, this case illustrates that parasitic infections such as schistosomiasis can mimic neoplastic processes, even in patients with no travel to endemic areas. Careful pathological evaluation enabled accurate diagnosis and appropriate treatment, highlighting the importance of maintaining a broad diagnostic perspective in complex hepatic presentations.

References

- Nour NM. Schistosomiasis: health effects on women. *Rev Obstet Gynecol.* 2010; 3(1): 28-32.
- Ekloh W, Asafu-Adjaye A, Tawiah-Mensah CNL, Ayivi-Tosuh SM, Quartey NK. A comprehensive exploration of schistosomiasis: Global impact, molecular characterization, drug discovery, artificial intelligence and future prospects. *Heliyon.* 2024; 10(12): e33070.
- Tan SY, Ahana A. Theodor Bilharz (1825-1862): discoverer of schistosomiasis. *Singapore Med J.* 2007; 48(3): 184-5.
- WHO. Current estimated total number of individuals with morbidity and mortality due to Schistosomiasis haematobium and *S. mansoni* infection in sub-Saharan Africa. 2020.
- Santos LL, Santos J, Gouveia MJ, Bernardo C, Lopes C. Urogenital Schistosomiasis-History, Pathogenesis, and Bladder Cancer. *J Clin Med.* 2021; 10(2).
- Strickland GT. *Hunter's Tropical Medicine.* 1991.
- Shaker Y, Samy N, Ashour E. Hepatobiliary Schistosomiasis. *J Clin Transl Hepatol.* 2014; 2(3): 212-6.
- Ekloh W, Asafu-Adjaye A, Tawiah-Mensah CNL, Ayivi-Tosuh SM, Quartey NK-A. A comprehensive exploration of schistosomiasis: Global impact, molecular characterization, drug discovery, artificial intelligence and future prospects. *Heliyon.* 2024; 10(12): e33070.
- Schwartz C, Fallon PG. Schistosoma "Eggs-Itting" the Host: Granuloma Formation and Egg Excretion. *Frontiers in Immunology.* 2018; 9 - 2018.
- Abdelghani E, Zerpa R, Iliescu G, Escalante CP. Schistosomiasis and liver disease: Learning from the past to understand the present. *Clin Case Rep.* 2020; 8(8): 1522-6.
- Colley DG, Bustinduy AL, Secor WE, King CH. Human schistosomiasis. *The Lancet.* 2014; 383(9936): 2253-64.
- Andersson KL, Chung RT. Hepatic schistosomiasis. *Current Treat-*

- ment Options in Gastroenterology. 2007; 10(6): 504-12.
13. Leder K, Weller P. Diagnosis and treatment of schistosomiasis. Version 14.3 UpToDate 2005.
 14. Carneiro TR, Pinheiro MC, de Oliveira SM, Hanemann AL. Increased detection of schistosomiasis with Kato-Katz and SWAP-IgG-ELISA in a Northeastern Brazil low-intensity transmission area. *Rev Soc Bras Med Trop*. 2012; 45(4): 510-3.
 15. Elbaz T, Esmat G. Hepatic and intestinal schistosomiasis: review. *J Adv Res*. 2013; 4(5): 445-52.
 16. Bezerra AS, D'Ippolito G, Caldana RP, Leopoldino DD, Batista GR. Differentiating cirrhosis and chronic hepatosplenic schistosomiasis using MRI. *AJR Am J Roentgenol*. 2008; 190(3): W201-7.
 17. Cimini A, Ricci M, Gigliotti PE, Pugliese L, Chiaravallotti A. Medical Imaging in the Diagnosis of Schistosomiasis: A Review. *Pathogens*. 2021; 10(8).
 18. Mnkugwe RH, Minzi OS, Kinung'hi SM, Kamuhabwa AA. Efficacy and Safety of Praziquantel for Treatment of *Schistosoma mansoni* Infection among School Children in Tanzania. *Pathogens*. 2020; 9(1): 28.
 19. Ranalli TV, Dell'Isola S, Gomes VV, Ialungo AM, Starnini G. Liver schistosomiasis: an unexpected finding in hepatitis B virus-related chronic hepatitis. *International Journal of Infectious Diseases*. 2008; 12(6): e67-e70.
 20. Gasim GI, Bella A, Adam I. Schistosomiasis, hepatitis B and hepatitis C co-infection. *Virology Journal*. 2015; 12(1): 19.
 21. Yalçın A, Avcu F, Ural AU, Beyan C, Omay SB. *Schistosoma mansoni* Infection Following Allogeneic Bone Marrow Transplantation. *Turk J Haematol*. 1999; 16(4): 181-4.
 22. Zhang Y, Xie Y, Chen Q, Chen X, Dong Z, Tan X. Prevalence and co-infection of schistosomiasis/hepatitis B among rural populations in endemic areas in Hubei, China. *Trans R Soc Trop Med Hyg*. 2020; 114(3): 155-61.
 23. Ak Ç, Sayar S, Kılıç ET. A *Schistosoma Colitis* Case Misdiagnosed as Ulcerative Colitis in a Non-Endemic Area: A Case Report. *Iran J Parasitol*. 2022; 17(3): 431-5.
 24. Sağol Ö, Özen E, Şimşek İ, Ellidokuz E. Hepatic Schistosomiasis: Report of a Case Accompanying a Metastatic Tumor in the Liver. *EASTERN JOURNAL OF MEDICINE*. 2013; 5(1): 31-2.
 25. Yılmaz D, Bayrak E, Mızrak M. İkinci Basamak Bir Hastanede Takip Edilen Üriner Şistozomiazis Olgusu. *Klinik Journal/Klinik Dergisi*. 2024; 37(3).
 26. Aytaç B. A rare parasitic infection in Turkey: schistosomiasis. Case report. *Turkish Journal of Pathology*. 2012; 28(2).
 27. Özvatan TŞ, Koçak C, Alver O, Mıstık R, Aslan E. Seyahat İlişkili Üriner Şistozomiyaz: Olgu Sunumu. *Türkiye Parazitol Derg*. 2011; 35: 175-7.
 28. Bingul F, Tuncali D, Terzioğlu A, Aslan G. Hemangioma of the lower lip associated with schistosomiasis: a case report. *British journal of plastic surgery*. 2005; 58(5): 736-7.
 29. Kiremit MC, Cakir A, Arslan F, Ormeci T, Erkurt B, Albayrak S. The bladder carcinoma secondary to *Schistosoma mansoni* infection: A case report with review of the literature. *International Journal of Surgery Case Reports*. 2015; 13: 76-8.
 30. Yazar S, Yaman O, Çetinkaya Ü, Hamamcı B, Kaya M. BİR SÜREDİR TÜRKİYE DE YAŞAYAN NİJERYALI BİR ÖĞRENCİDE SCHISTOSOMA HAEMATOBİUM ENFEKSİYONU. *Türk Hijyen ve Deneysel Biyoloji Dergisi*. 2010; 67(4): 185-8.
 31. YAZAR S, SİPAHİOĞLU M, ÜNAL A, YAMAN O. Bir süredir Türkiye'de yaşayan Ganalı bir hastada *Schistosoma haematobium* enfeksiyonu. *Türkiye Parazitol Derg*. 2008; 32(2): 161-3.
 32. GÜL HC, COŞKUN Ö, BEŞİRBELLİOĞLU BA, ARAZ E, ÖNGÖRÜ Ö. Mali'ye seyahat eden Türkler arasında üriner şistozomiyaz: üç olgu sunumu. *Türkiye Klinikleri Journal of Medical Sciences*. 2009; 29(6): 1763-6.