

Unexpected Success of Bilateral Robotic-Assisted Ureteral Reconstruction with Buccal Mucosa Graft for Bilateral Ureteral Strictures: A Case of Delayed Graft Healing

Eyad Al Qadiri, Furat Abd Ali and Karl-Dietrich Sievert*

Department of Urology, Medical Faculty OWL, University of Bielefeld, Klinikum Lippe, Röntgenstrasse 18, 32756 Detmold, Germany

*Corresponding author:

Karl-Dietrich Sievert,
Department of Urology, Medical Faculty OWL,
University of Bielefeld, Klinikum Lippe,
Röntgenstrasse 18, 32756 Detmold, Germany

Received: 26 Sep 2024

Accepted: 29 Oct 2024

Published: 02 Nov 2024

J Short Name: ACMCR

Copyright:

©2024 Karl-Dietrich Sievert. This is an open access article distributed under the terms of the Creative Commons Attribution License, which permits unrestricted use, distribution, and build upon your work non-commercially

Citation:

Karl-Dietrich Sievert, Unexpected Success of Bilateral Robotic-Assisted Ureteral Reconstruction with Buccal Mucosa Graft for Bilateral Ureteral Strictures: A Case of Delayed Graft Healing. *Ann Clin Med Case Rep.* 2024; V14(6): 1-4

1. Introduction

Ureteral strictures represent a common urological challenge, often requiring repeated interventions. This case report presents a patient with bilateral ureteral strictures who successfully underwent staged bilateral robotic-assisted ureteral reconstruction using a buccal mucosa graft (BMG). In recent years, significant advancements in minimally-invasive techniques and technologies have transformed the treatment of ureteral strictures. Historically, the management of these strictures often required open surgery, however, the introduction of minimally-invasive techniques has allowed for effective treatment in most patients without the necessity to use open procedures [1].

The robotic repair of ureteral stenosis has emerged as a useful treatment option for strictures unsuitable for endoscopic resolution demonstrating good results, lower morbidity and faster recovery than open techniques. Depending on the strictures length and location, reconstructive options are reimplantation, psoas hitch, Boari flap, ureteroureterostomy, appendiceal onlay flap, buccal mucosa graft (BMG) ureteroplasty, ileal replacement or renal auto-transplantation. The robotic approach offers a magnified vision and the possibility of adding near-infrared fluorescence (NIRF) imaging, indocyanine green (ICG), and Firefly™ to facilitate the technique [2]. Robotically-assisted laparoscopic techniques may be used for proximal-to-distal ureteral strictures [3]. There is a rapid expansion of robotic ureteral reconstructive techniques, platforms, and adjunctive technologies, enabling more efficient, safer and

novel surgical approaches that could not be done in the past. For instance, indocyanine green use allows rapid, precise location of ureteral stenosis and determination of tissue perfusion. Multi-image display allows the surgeon to integrate the robotic field and ureteroscopic images. Novel robotic surgical techniques, such as buccal mucosa ureteroplasty, are changing the treatment algorithm for ureteral strictures [4]. Recent reports have described the efficacy of robotic BMG ureteroplasty and the utilization of near-infrared fluorescence to assist with precise identification of the ureteral stricture margins. BMG ureteroplasty is well-suited for ureteral reconstruction as it allows for minimal disruption of the delicate ureteral blood supply and facilitates a tension-free anastomosis. This technique is particularly useful in patients with long ureteral strictures not amenable to ureteroureterostomy and in patients with a recurrent ureteral stricture after a previously failed ureteral reconstruction [5].

1.1. Patient Description

A 66-year-old male patient with a long-standing history of nephroureterolithiasis, who had undergone multiple urological interventions, including repeated ureteroscopies (URS) and extracorporeal shock wave lithotripsy (ESWL), was presented with bilateral ureteral stenosis, which made several double-J (DJ) stent placements and exchanges necessary to preserve kidney function. Most likely, the patient developed bilateral ureteral stricture due to repeated urgent endourological procedures and the associated inflammatory responses (Figure 1). In February 2023, the patient underwent

robotic-assisted ureteral reconstruction with a buccal mucosa graft for a 3 cm stricture in the right ureter. The postoperative course was largely uneventful, apart from a necessary DJ stent change due to obstruction and temporary hydronephrosis, as well as a single urinary tract infection. Overall, the reconstruction was successful, with no long-term complications. In June 2023, the left ureter, which had three separate strictures, was also addressed with robotic-assisted reconstruction by the same surgeon (KDS) as the initial one using a buccal mucosa graft, each patch 0.5cm larger than the initial stricture. Postoperatively, the patient experienced transient hydronephrosis and a failed DJ stent placement which necessitated a percutaneous nephrostomy to preserve kidney function (Figure 2). Significant concern arose regarding the success of the second reconstruction, prompting consideration of the classic ileal replace-

ment approach. However, by December 2023, antegrade imaging unexpectedly revealed that the reconstructed ureter had reopened without further surgical intervention—an outcome not previously documented in surgical literature. After four months of nephrostomy support, a follow-up ultrasound confirmed good drainage without recurrence of hydronephrosis. With no evidence of significant obstruction, the nephrostomy was permanently removed. During the follow-up (Oct. 2024, (15 months after the initial surgery and 10 months after the removal of the left nephrostomy) kidney function scintigraphy (Figure 3) showed 47% left and 53% right renal function without any sign of obstruction along the recovered creatinine and glomerula filtration rate (GFR). The patient remained asymptomatic, demonstrating that the buccal mucosa graft healed and became functional over time without additional surgery.

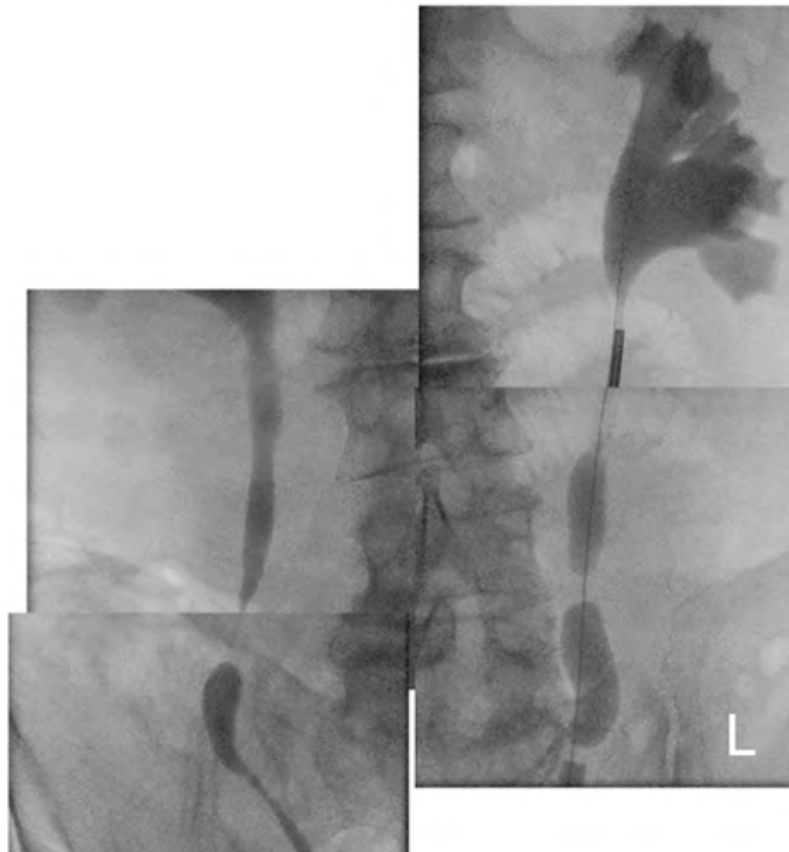


Figure 1: Patched X-Rays as result of retrograde contrast media injection demonstrating the urethral strictures bilateral (Jan. 2023, Left=L).

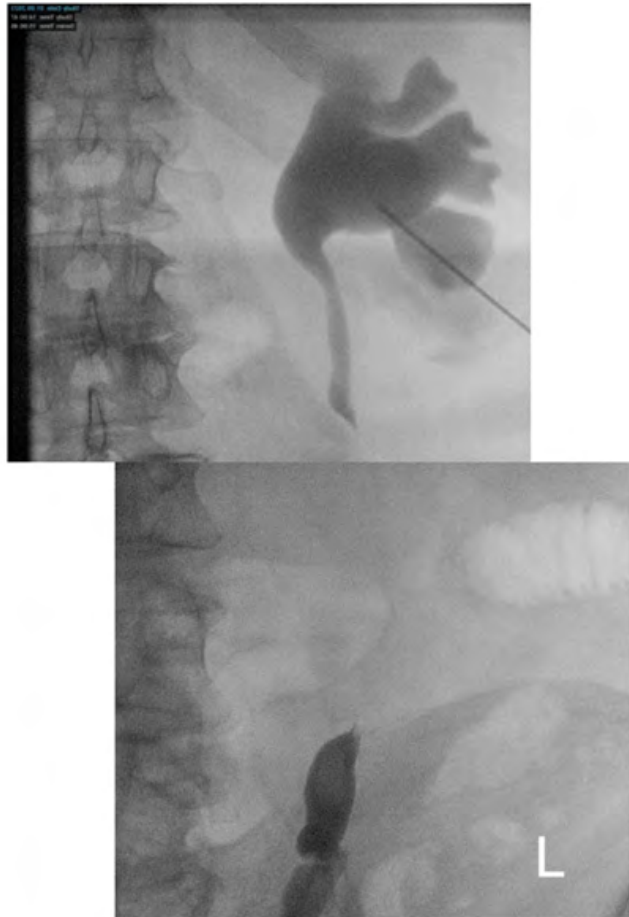


Figure 2: Patched X-Rays from the percutaneous puncture of the lower clix of the left kidney, demonstrating the stricture of the mid ureter (top part of the picture) and retrograde contrast application (lower part of the picture) demonstrates the same stricture of the left ureter (Sep. 2023, L=Left).

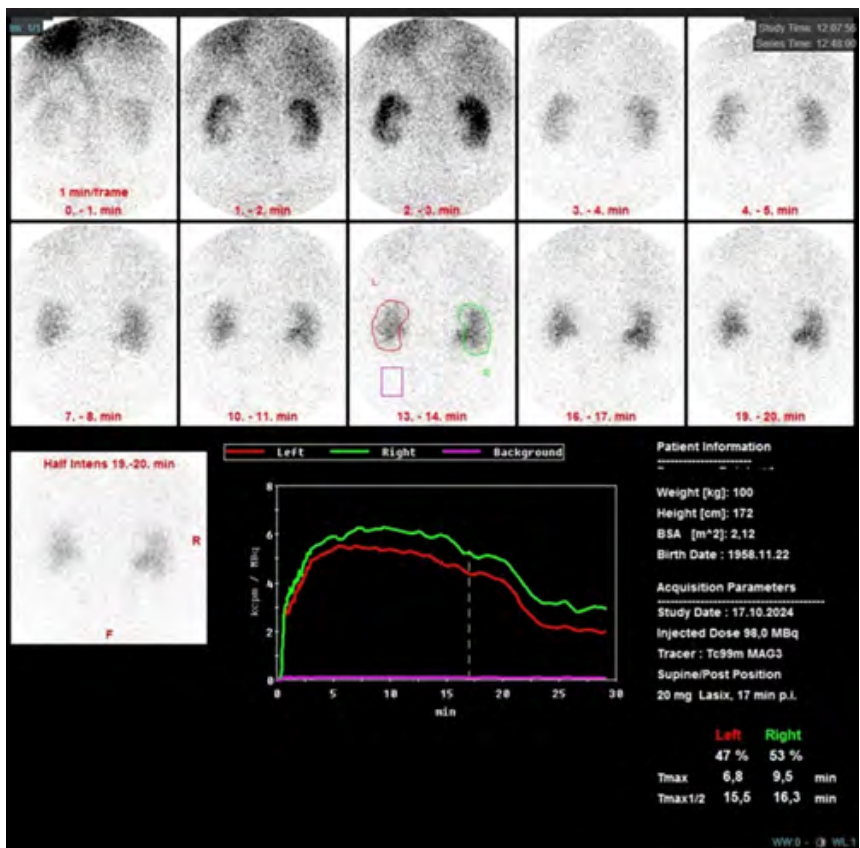


Figure 3: The kidney functional szintigraphy (Oct 2024, 16 months after surgery) shows recovered normal kidney function.

2. Discussion

Traditionally, complex ureteral strictures were managed through open surgery, which posed higher risks of morbidity and resulted in longer recovery times. However, with advancements in minimally invasive robotic-assisted surgery, the treatment landscape has transformed, offering safer alternatives with quicker recovery and fewer complications [2]. The use of buccal mucosa graft (BMG) in urology has become increasingly popular due to several advantageous characteristics: ease of harvest, excellent surgical handling, lack of hair, compatibility in wet environments, and its early in-growth and graft survival. These features make BMG an ideal substitute for ureteral reconstruction, endearing it to the field of reconstructive urology [6]. This procedure is a safe and feasible for ureteral reconstruction that can serve as another choice for managing long, complex ureteral strictures [7]. In this particular case, the buccal mucosa graft enabled precise reconstruction of the ureters while preserving and securing its blood supply and ensuring a tension-free anastomosis, which is critical for proper healing and long-term patency. Additionally, the use of robotic-assisted surgery allowed for improved visualization and precision, minimizing the risk of complications. The integration of near-infrared fluorescence (NIRF) with indocyanine green (ICG) further enhanced this precision by helping to identify the stricture margins and ensuring adequate perfusion of the graft and surrounding tissues. This advanced technology reduced the likelihood of ischemia-related complications, contributing to better post-operative outcomes [5]. This case illustrates the advantages of robotic-assisted techniques for managing complex bilateral ureteral strictures and highlights the role of buccal mucosa graft (BMG) ureteroplasty in restoring urinary drainage in severe cases. Notably, there was considerable uncertainty regarding the success of the left ureter reconstruction. The nephrostomy served as a crucial bridging solution, preventing further deterioration of renal function during the healing period. Just before contemplating a classic ileal replacement, antegrade contrast imaging revealed unexpectedly that the reconstructed ureter had reopened and was functioning. This remarkable outcome had not been reported with other surgical approaches. Although initial assessments suggested possible BMG failure, it ultimately healed and became functional. This case underscores the potential for BMG to integrate and recover over time, which may alleviate the need for additional surgical interventions. The successful outcome, achieved after a four-month waiting period when improvement is usually not anticipated, points to the possibility that BMGs possess an underexplored regenerative capacity. It is conceivable that similar cases went unrecognized due to insufficient post-operative observation, with surgeons opting for further surgery too soon.

3. Conclusion

Robotic-assisted ureteral reconstruction with a buccal mucosa

graft is a highly effective, minimally-invasive treatment for complex ureteral strictures, especially when other interventions have failed. In this instance, the staged bilateral approach successfully resolved strictures in both ureters, preserved renal function, and resulted in minimal long-term complications. The left ureter's unexpected recovery, despite initial concerns, emphasizes the healing potential of buccal mucosa grafts over time, suggesting that extended observation may help avoid unnecessary surgeries. The integration of advanced robotic technologies, such as near-infrared fluorescence, has enhanced procedural precision and safety, yielding excellent outcomes in challenging cases. This case not only supports the growing adoption of robotic-assisted surgery and buccal mucosa grafting for complex ureteral strictures but also raises the intriguing possibility of untapped regenerative potential in buccal mucosa grafts, warranting further research. Ultimately, this approach provides patients with reduced morbidity, faster recovery, and the potential for success even when initial results seem unfavorable. Robotic ureteroplasty with buccal mucosa graft is associated with low peri-operative morbidity and excellent intermediate-term outcomes [8]. However, further long-term, multi-center investigations are necessary to validate the positive findings reported in existing case series. Compared with open surgery, robot-assisted reconstruction techniques yield superior functional outcomes, fewer postoperative complications, and accelerated recovery for the treatment of ureteral strictures [9].

References

1. Hafez KS, Wolf JS Jr. Update on minimally invasive management of ureteral strictures. *J Endourol.* 2003; 17(7): 453-64.
2. Elbers JR, Rodríguez Socarrás M, Rivas JG, Autran AM, Esperto F. Robotic Repair of Ureteral Strictures: Techniques and Review. *Curr Urol Rep.* 2021; 22(8): 39.
3. Drain A, Jun MS, Zhao LC. Robotic Ureteral Reconstruction. *Urol Clin North Am.* 2021; 48(1): 91-101.
4. Fuller TW, Daily AM, Buckley JC. Robotic Ureteral Reconstruction. *Urol Clin North Am.* 2022; 49(3): 495-505.
5. Lee Z, Keehn AY, Sterling ME, Metro MJ, Eun DD. A Review of Buccal Mucosa Graft Ureteroplasty. *Curr Urol Rep.* 2018; 19(4): 23.
6. Zimmerman WB, Santucci RA. Buccal mucosa urethroplasty for adult urethral strictures. *Indian J Urol.* 2011; 27(3): 364-70.
7. Yang K, Fan S, Wang J, Yin L, Li Z, Xiong S, Han G. Robotic-assisted Lingual Mucosal Graft Ureteroplasty for the Repair of Complex Ureteral Strictures: Technique Description and the Medium-term Outcome. *Eur Urol.* 2022; 81(5): 533-540.
8. Lee Z, Lee M, Koster H, Lee R, Cheng N. Collaborative of Reconstructive Robotic Ureteral Surgery (CORRUS). A Multi-Institutional Experience with Robotic Ureteroplasty with Buccal Mucosa Graft: An Updated Analysis of Intermediate-Term Outcomes. *Urology.* 2021; 147: 306-310.
9. Xu MY, Song ZY, Liang CZ. Robot-assisted repair of ureteral stricture. *J Robot Surg.* 2024; 18(1): 354.