

Vertebral Artery Dissection Rupture in a Patient with Varicella Zoster Virus Infection after Cervical Spine Manipulation: Case and Review of the Literature

Duo Lu Wu^{1*}, Bin He², Yue Long Wang², Liang Xue Zhou², Yi Liu² and Jian Guo Xu^{2*}

¹Department of Neurosurgery, West China Hospital, Sichuan University, Chengdu, 610041, PR China

²Department of Obstetrics, West China Second Hospital, Sichuan University, Chengdu, PR China

*Corresponding author:

Jian Guo Xu

Department of Obstetrics, West China Second Hospital, Sichuan University, Chengdu, PR China

Received: 01 July 2024

Accepted: 22 July 2024

Published: 29 July 2024

J Short Name: ACMCR

Copyright:

©2024 Duo Lu Wu, Jian Guo Xu. This is an open access article distributed under the terms of the Creative Commons Attribution License, which permits unrestricted use, distribution, and build upon your work non-commercially

Citation:

Duo Lu Wu, Jian Guo Xu, Vertebral Artery Dissection Rupture in a Patient with Varicella Zoster Virus Infection after Cervical Spine Manipulation: Case and Review of the Literature. *Ann Clin Med Case Rep.* 2024; V13(23): 1-6

Keywords:

Vertebral artery dissection (VAD); Varicella Zoster Virus (VZV); Pseudoaneurysm; Cervical spine manipulation

Abbreviations:

VAD: Vertebral Artery Dissection; VZV: Varicella Zoster Virus; ICA: Internal Carotid Artery; MCA: Middle Cerebral Artery; CSF: Cerebrospinal Fluid; CT: Computed Tomography; SLE: Systemic Lupus Erythematosus; PCR: Polymerase Chain Reaction; SAH: Subarachnoid Hemorrhage

1. Abstract

We report a case of vertebral artery dissection (VAD) rupture and pseudoaneurysm after cervical spine manipulation that occurred in a 29-year-old male with varicella zoster vasculopathy (VZV) infection. The patient was successfully treated with arterial embolization therapy. Here, we explored its possible mechanism regarding the association of varicella zoster virus infection with vertebral artery dissection and scrutinized the diagnosis and treatment profiles surrounding VZV induced vasculopathy.

2. Introduction

Varicella zoster virus (VZV) is a highly infectious neurotropic double-stranded DNA alpha herpesvirus. More commonly, primary VZV infection, which usually occurs in children, results in chickenpox (varicella), after which the virus becomes latent in ganglionic neurons along the entire neuraxis [1]. Moreover, given that >95 % of the world population is latently infected with VZV and that 50 % will experience virus reactivation and develop zoster before the age of 85, it is probably not uncommon [2].

VZV invades not only nerves but also their adjacent arteries. For instance, VZV, which resides in the trigeminal ganglion, may migrate through the trigeminal nerves innervating the arterial tree at the level of the distal internal carotid artery (ICA) and proximal

middle cerebral artery (MCA) to cause inflammation of the arterial wall [3]. VZV infection may trigger the inflammatory cascade which causes vessel wall damage and inflammation. In recent decades, VZV-induced vasculopathy's clinic spectrum has expanded to include not only ischemic and hemorrhagic stroke, but also multifocal VZV vasculopathy, with temporal artery infection mimicking giant cell arteritis, extracranial vasculopathy, aneurysm with and without subarachnoid hemorrhage, cerebral venous sinus thrombosis, spinal cord infarction and arterial dissection [2]. When it is in children, VZV vasculopathy is thought to account for 31% of all arterial ischemic strokes; moreover, stroke was preceded by chickenpox in 44% of children with transient cerebral arteriopathy [3]. However, the exact correlation of VZV related VAD rupture in the cervical segment of vertebral artery and the formation of pseudoaneurysm remains unclear. We did not identify any additionally identical cases. This is the first report focusing on the relationships mentioned above.

3. Case Report

A previously healthy 29-year-old man presented to our hospital with 15-day history of continuous neck pain and a progressively enlarged neck mass. He confirmed after the neck pain begun, a cervical spine manipulation was performed, then a neck mass

appeared. About 10 days later after the neck mass appeared, some chickenpox appeared on the skin of the left side of the neck. And there was no anomaly in his previous history. During the physical examination, the lesion on the anterior left side of the neck appeared as crusted vesicles and a spherical pulsatile soft mass was palpated at the posterior left side of the neck (size 5×3cm, Figure1A, arrow). He had a neck movement disorder accompanied with unilateral hypoesthesia of the head and neck. The remainder of the physical examination was unremarkable. Laboratory data revealed a viral infection with WBC count 22.58×10⁹ (polymorphonuclear leukocytes 8% and absolute monocyte count 2.08×10⁹), an erythrocyte sedimentation rate 119.0 mm/h and a CRP concentration 199.00 mg/L. VZV IgG antibody in serum was significantly elevated (27.20 index value; a VZV IgG titer >1.10 was considered positive). Electrolytes, creatinine, and liver function tests were within normal limits. HIV, hepatitis B, and hepatitis C serology were negative. A cerebrospinal fluid (CSF) examination was not performed. Enhanced computed tomography (CT) scan images of his neck showed a weak signal in the artery upon the level of C4 and there was a mixed signals of soft tissue density lesion of 3.3×4.4cm in size (Figure1B,C, arrow). Angiography of neck vessels showed left vertebral artery dissection rupture (Figure1D; Video 1) with pseudoaneurysm formation. The Neck Vascular Color Doppler Ultrasound revealed a blood flow signal: a double arterial phase and bidirectional arterial spectrum in the laceration between the vertebral artery and the mass.

The patient was then treated with the left vertebral arterial embolization therapy (Figure1E; Video 2) on the 6th day after presentation. At last, he was discharged with neck pain relieved. Ten days later, he came back to our department for reexamination. A Neck Vascular Color Doppler Ultrasound revealed that there was no blood flow signal in the site of previous cervical mass.

4. Discussion

The clinic feature of vasculopathy following the VZV, have been widely reported before. It is clear that, VZV, after reactivation from ganglia, spreads transaxonally to the arterial adventitia followed by transmural spread of virus (Figure1F). Then the virus will experience a disruption from the internal elastic lamina with cells expressing α -SMA and SM-MHC causing progressive intimal thickening and decreased smooth muscle cells in the media 2. It can invade both cranial nerves and cerebral arteries [4,5]. Vasculopathy secondary to VZV infection via the pathway mentioned above has been described over the past few years. The VZV vasculopathy can cause ischemic infarction of the brain and spinal cord, as well as aneurysm, subarachnoid and cerebral hemorrhage, dissection, and, rarely, thrombosis in the central venous system [2]. We have reviewed 18 cases of patients who developed VZV induced vasculopathy [Table 1]. Among all these patients, [11] people were healthy and without previous diseased, people who were immunocompromised (such as HIV-positive patients, patients

with systemic lupus erythematosus (SLE), and transplant recipients) were more likely to be rash-free [6-10]. Therefore, people who without rash or “shingles” cannot be ignored when vasculopathy occurs. The presenting clinic symptoms of patient at the onset were varied, half of them were febrile or having a chill followed by the severe headache and lethargy [7-9,11-15], about 6 patients suffered from focal seizure [8,11,12]. Since VZV is a type of neurotropic virus, it has the ability to transmit from the Gasserian ganglion to the trigeminal nerve, which results in zoster ophthalmicus [5,14,16], if the virus went down to the intrapetrosal structures, it would affect the eighth cranial nerve causing hypoacusis and pain in the ear [14]. A patient with the VZV infection who doesn't receive treatment in time, may develop persistent weakness or palsy of the body and face for affecting the cerebral arteries which dominate the corresponding area relating to motor and sensory cortex [10,11,14]. The CSF are usually tested to primarily identify the possibility infection by virus and in most cases it presented with a elevated high total lymphocyte count, whereas the glucose and protein revealed rather normal with no remarkable significance. Because VZV prevails in the thickened intima and the media of the arteries: at the time of CSF analysis the concentration of VZV DNA was probably below the detection limit of PCR in lumbar CSF 5. Thus, it is better to take a polymerase chain reaction (PCR) of targeted virus in CSF together with serum specific antibodies to confirm the causation. CT is sensitive to subarachnoid hemorrhage (SAH) if the case involves the aneurysm rupture [8, 9,15], since the CT scan alone is not sufficient to assess the degree of vasculopathy and the invasion of cranial nerves, so we opt for booking the MRI scan to detect potential lesion as well as provide essential information through follow-up examinations. Moreover, angiograms can be considered, on the one hand, it directly shows cranial arteries and venous abnormality, it also stands as a kind of treatment [7,14,17]. In the cases of VZV-infected dissection and aneurysm reported, coil embolization or ligation was performed. Of all cases we reviewed, it is recommended that every patient should be receiving intravenous acyclovir as long as the diagnose is confirmed. Treatment with intravenous acyclovir resulted in reduction in the size of most aneurysms and complete resolution of the 2 largest aneurysms [8], it is also pointed out that early acyclovir treatment may have suppressed the skin vesicles 9. Nonetheless, an adequate amount of i.v. antiviral drug doesn't guarantee the immediate revolve of neurologic complications for it can only stop the progression of the disease [5,18]. Another thing should be mentioned is that the patient receiving transplant surgeries should decrease the immunosuppressor medication accordingly [7]. Glucocorticoid therapy hadn't been confirmed to have a valid effect in treating patient with VZV vasculopathy, and long-term antiviral drugs are far less risky than long-term glucocorticoid [5]. The management of hematoma in patients of this kind needs to be personalized. The period between the onset and neurologic symptoms can vary widely from 2 days to 6 months in our overview. An arti-

cles has described the period between onset of childhood VZV infection and the vascular stenosis which occasionally progresses up to 6 months after presentation, however, the vascular changes generally regress subsequently in as long as 48 months, no child with stroke preceded by primary VZV infection showed progressive arteriopathy [19]. Taking appropriate treatment in time, most patients' condition can gradually be improved within 1 week [11,20]. We recently encountered a case of VAD rupture in the cervical segment of vertebral artery associated with VZV infection, which had probably been aggravated after cervical spine manipulations. In fact, this is the first case reporting VZV-induced VAD in extracranial segment of the vertebral artery. The mechanism of the progression of this case is still unclear, but we have two hypothesizes of VAD rupture and the formation of the pseudoaneurysm. First, VAD was caused by the VZV through spreading transaxonally to the arterial adventitia. In our case, the high level of VZV IgG antibody in serum (27.20 index value) indicated the infection of VZV. The area of the spherical mass and chickenpox is the innervating areas of left C3 nerve posterior root, which is adjacent to the left vertebral artery. Thus, the serologic examination results and the symptom mentioned above have led to the realization that the cervical manifestations are predominantly the result of arterial disease caused by VZV infection. Then, the Cervical Spine Manipulation facilitated the rupture of the VAD and the formation of the pseudoaneurysm. There are a series of cases indicated that most cervical artery dissections reported in the previous decade were spontaneous while some were associated with trauma/trivial trauma, as well as a minority with cervical spine manipulation [21]. As

a result of that, Mechanical forces can lead to intimal injuries of the vertebral arteries and internal vertebral arteries which result in artery dissection. Moreover, Clinical reports suggest that mechanical forces play a role in a considerable number of cervical artery dissections and many population-controlled studies have found an association between cervical manipulative therapy and vertebral artery dissection stroke in young patients [22]. In our case, the patient had a medical history of cervical spine manipulation for the neck pain. The cervical mass developed gradually after cervical spine manipulation. Headache and neck pain occur in 50% to 80% of cervical artery dissection, and it may be the only warning symptoms of impending dissection [23,24]. That means in this case VZV had already caused the VAD prior to manipulative therapy, then the VAD caused by VZV infection through the C3 nerve posterior root contributed to neck pain, thus the patient requested for cervical spine manipulation, which led to the rupture of the VAD and the formation of the pseudoaneurysm. Under the condition of viral infection, the vertebral artery wall was already vulnerable, the following manipulative therapy accelerated the rupture of extracranial VAD and the development of the pseudoaneurysm. This theory is strengthened by a statement that current biomechanical evidence is insufficient to establish the claim that cervical manipulative therapy alone will directly cause cervical artery dissection, the VAD caused by cervical manipulative therapy in our case occurs only when the vessel wall is weakened by the VZV infection. We then successfully treated this patient with the left vertebral arterial embolization therapy with the neck mass disappeared a few days later.

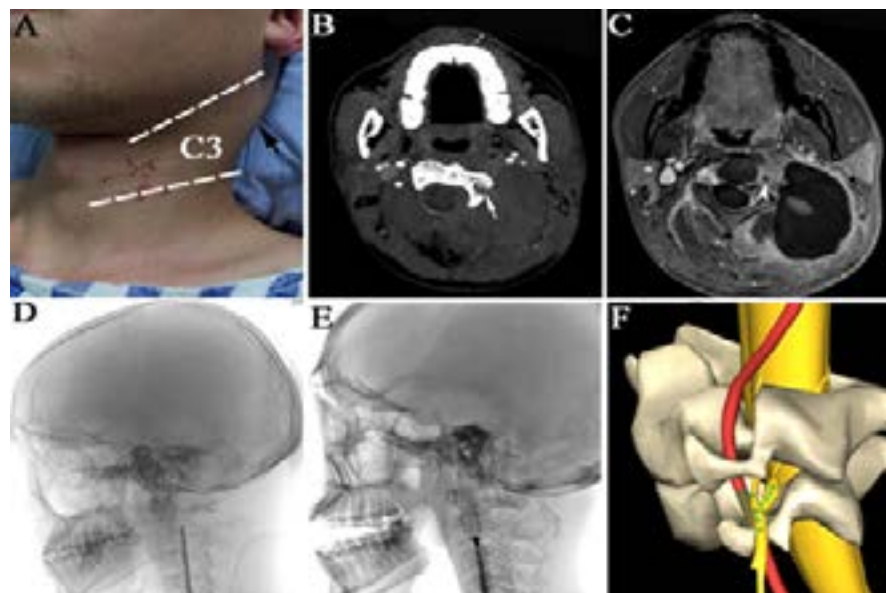


Figure 1: A. The area of cervical mass(arrow) and chickenpox(between two white lines) is the innervating areas of left C3 nerve posterior root; B. Enhanced CT performed contrast media display a weak signal in the artery upon the level of C4 and a mixed signals of soft tissue density images which size is about 3.3×4.4cm(arrow); C. MRA indicated that there was hemorrhage in the cervical mass adjacent to the vertebral artery; D,E. Angiography showed left vertebral artery dissection rupture with pseudoaneurysm formation; F, the local relation of the vertebral arteries and the left C3 nerve root.

Table 1: Literature Review of All VZV induced vasculopathy Reported Cases

Study	Patients	History	Vasculopathy Type	Clinical Manifestation	Diagnosis	Treatment	Prognosis
Bhayani et al. (2008)7	42 years, male	Kidney transplantation	Aneurysm	Lethargy, chills, headache, pain	Serum VZV IgG CSF PCR Angiogram	Acyclovir, prednisone Stent-assisted coil embolization	Complete recovery
Gursoy et al. (1980)14	24 years, female	None	Aneurysm	Rash, tenderness, fever, pain, peripheral facial palsy, contralateral hemiplegia, hypoacusis	Angiogram	Local corticosteroid, antibiotics, vitamins, Proximal ligation	Minimal hemiparesis, peripheral facial palsy
Fukumoto et al. (1986)15	70 years, male	None	Aneurysm	Rash, chill, pain	Serum VZV IgG CT Autopsy	Analgesics, vitamins, anti-inflammatory drugs, gamma-globulin	Death
Daugherty et al. (2009)25	14 years, female	Familial CVID with T-cell dysfunction, chronic bronchiectasis, pulmonary infections, chronic mucocutaneous candidiasis	Aneurysm	Headache, pain, hypesthesia	CSF PCR CT MRI Angiography	Acyclovir, valacyclovir, aspirin	The fusiform aneurysms are stable
Kawatani et al. (2012)26	6 years, female	None	Aneurysm	Rash, aphasia	MRI	Aspirin	Detected a 3-mm-diameter saccular aneurysm in the ACA 27 months after onset
Fulmer et al. (1998)8	6 years, female	HIV positive	Aneurysm	Lethargy, fever, headache, seizure, nausea, vomiting, cough	CT Angiogram	Hydrated Ventriculostomy	Postoperative CT revealed increased SAH with a casted ventricular system
Fulmer et al. (1998)8	41 years, female	Systemic lupus erythematosus (SLE)	Aneurysm	Fever, headache	CSF PCR Fluorescent antibody staining of rash swab MRI CT	Acyclovir, valacyclovir, prednisone, methylprednisolone	Right hemiplegia
Lee et al. (2016)17	60 years, female	None	Dissection	Rash, mental deterioration	CSF VZV IgM and IgG CT Angiogram	Intravenous acyclovir, aspirin, Coil embolization	Complete recovery
Ueno et al. (2002)20	4 years, male	None	Infarction	Hemiplegia	CT MRI	Acyclovir	Complete recovery
Patrick et al. (1995)4	56 years, male	Arterial hypertension and rheumatoid arthritis	Infarction	Rash, weakness, dizziness,	Serum VZV IgG antibody MRI Angiogram	Acyclovir, prednisone, methylprednisolone, aspirin	Lower extremity paresis and left upper extremity plegia
Eidelberg et al. (1986)10	20 years, female	Nodular sclerosing Hodgkin's disease	Thrombosis	Weakness, headache, aphasia, hemiparesis, keratitis	CT Angiogram	Cyclophosphamide	Death
Siddiqi et al. (2012)11	15 years, male	None	Thrombosis	Drowsiness, fever, headache, seizures, hemiparesis	MRI	Acyclovir, antipyretics, diazepam	Complete recovery
Siddiqi et al. (2012)11	20 years, male	Insulin-dependent diabetes mellitus	Thrombosis	Rash, drowsiness, fever, headache, vertigo, seizures	MRI	Acyclovir, levetiracetam, enoxaparin	Complete recovery
Chan et al. (2004)27	55 years, female	None	Thrombosis	Pain, nausea, vomiting, photophobia	Serum VZV IgG CT	Acyclovir, neurontin	Complete recovery
Hausler et al. (2002)12	4 years, female	None	Subcortical Inflammation	Rash, drowsy, fever, seizure	Serum VZV IgG MRI	Acyclovir, steroid, phenytoin	Complete recovery
Gilden et al. (2021)28	80 years, male	None	Giant cell arteritis	Rash, ipsilateral ischemic optic neuropathy (ION)眼病	Biopsy	Acyclovir, steroids	Complete recovery
Nau et al. (1998)5	42 years, male	None	Giant cell arteritis	Dys- and hypesthesia	MRI CSF VZV IgG	Acyclovir, steroids	Complete recovery
Caruso et al. (2001)13	7 years, female	None	Arteritis	Lethargy, rash, fever, headache, pain, vomiting	Serum VZV IgG CSF PCR CT MRI	Acyclovir, methylprednisolone, prednisone	Complete recovery

VZV, varicella zoster virus; CSF, cerebrospinal fluid; PCR, polymerase chain reaction; CT, computerized tomography; MRI, magnetic resonance imaging

5. Conclusion

Although there are differences between the two hypotheses above, we consider that this patient had VZV-associated vascular disease of the left vertebral artery that led to a weakened vessel wall in association with dissection formation, and subsequent dissection rupture and the pseudoaneurysm formation related to the cervical spine manipulation. Thus, VZV vasculopathy should be considered if a patient with ischemic or hemorrhagic stroke due to ruptured cerebral artery dissection or aneurysm whose medical record has a current or history of chickenpox. In addition, manipulative therapy practitioners should consider the possibility of VAD based on symptoms (such as headache and neck pain), especially in some patients who are at high risk of vasculopathy, and patients should be informed of the probable connection and danger between VAD and the cervical spine manipulation before undergoing massage treatment. We also believe the overall description of existing VZV-induced vasculopathy could allow us to have a better understanding of and give advice on this typical type of disease course.

6. Disclosure

The research was supported by the General Program of the National Natural Science Foundation of China (82173175); 1·3·5 project for disciplines of excellence Clinical Research Incubation Project, West China Hospital, Sichuan University (2020HXFH036); and the Key research and development project of science and technology department of Sichuan Province (2023YFS0105).

References

- Gilden D, Cohrs RJ, Mahalingam R, Nagel MA. Varicella zoster virus vasculopathies: diverse clinical manifestations, laboratory features, pathogenesis, and treatment. *Lancet Neurol*. 2009; 8(8): 731-740.
- Nagel MA, Gilden D. Update on Varicella Zoster Virus Vasculopathy. *Curr Infect Dis Rep*. 2014; 16(6): 407.
- Braun KPJ, Bulder MMM, Chabrier S. The course and outcome of unilateral intracranial arteriopathy in 79 children with ischaemic stroke. *Brain*. 2008; 132(2): 544-557.
- Patrick JT, Russell E, Meyer J, Biller J, Saver JL. Cervical (C2) herpes zoster infection followed by pontine infarction. *J Neuroimaging*. 1995; 5(3): 192-193.
- Nau R, Lantsch M, Stiefel M, Polak T, Reiber H. Varicella zoster virus-associated focal vasculitis without herpes zoster: Recovery after treatment with acyclovir. *Neurology*. 1998; 51(3): 914-915.
- Gilden DH, Kleinschmidt-DeMasters BK, LaGuardia JJ, Mahalingam R, Cohrs RJ. Neurologic complications of the reactivation of varicella-zoster virus. *N Engl J Med*. 2000; 342(9): 635-645.
- Bhayani N, Ranade P, Clark NM, McGuinn M. Varicella-zoster virus and cerebral aneurysm: case report and review of the literature. *Clin Infect Dis*. 2008; 47(1): e1-3.
- Fulmer BB, Dillard SC, Musulman EM, Palmer CA, Oakes JW. Two Cases of Cerebral Aneurysms in HIV+ Children. *Pediatr Neurol*. 1998; 28(1): 31-34.
- Lieberman AL, Nagel MA, Hurley MC, Caprio FZ, Bernstein RA, Gilden D. Rapid development of 9 cerebral aneurysms in varicella-zoster virus vasculopathy. *Neurology*. 2014; 82(23): 2139-2141.
- Eidelberg D, Sotrel A, Horoupian DS, Neumann PE, Pumarola-Sune T, Price RW. Thrombotic cerebral vasculopathy associated with herpes zoster. *Annals of Neurology*. 1986; 19(1): 7-14.
- Siddiqi SA, Nishat S, Kanwar D, Ali F, Azeemuddin M, Wasay M. Cerebral Venous Sinus Thrombosis: Association with Primary Varicella Zoster Virus Infection. *Journal of Stroke and Cerebrovascular Diseases*. 2012; 21(8): 917.e1-917.e4.
- Häusler M, Schaade L, Kemény S, Schweizer K, Schoenmackers C, Ramaekers VT. Encephalitis related to primary varicella-zoster virus infection in immunocompetent children. *Journal of the Neurological Sciences*. 2002; 195(2): 111-116.
- Caruso JM, Tung GA, Brown WD. Central Nervous System and Renal Vasculitis Associated With Primary Varicella Infection in a Child. *Pediatrics*. 2001; 107(1): e9-e9.
- Gürsoy G, Aktin E, Bahar S, Tolun R, Özden B. Post-herpetic aneurysm in the intrapetrous portion of the internal carotid artery. *Neuroradiology*. 1980; 19(5): 279-282.
- Fukumoto S, Kinjo M, Hokamura K, Tanaka K. Subarachnoid hemorrhage and granulomatous angiitis of the basilar artery: demonstration of the varicella-zoster-virus in the basilar artery lesions. *Stroke*. 1986; 17(5): 1024-1028.
- Nagel MA, Traktinskiy I, Azarkh Y, et al. Varicella zoster virus vasculopathy: analysis of virus-infected arteries. *Neurology*. 2011; 77(4): 364-370.
- Lee K, Park H, Park I, Han J. Endovascular treatment using woven stents for ruptured vertebral artery dissecting aneurysm induced by varicella zoster virus: case report. *Br J Neurosurg*. 2016; 30(6): 672-674.
- Débat Zoguéreh D, Saadoun R, Zandotti C, Cawston P, Moreau J. AIDS-related varicella zoster meningoencephalitis and radicular pain without cutaneous eruption. *AIDS*. 1996; 10(13): 1604-1606.
- Lanthier S, Armstrong D, Domi T, deVeber G. Post-varicella arteriopathy of childhood: natural history of vascular stenosis. *Neurology*. 2005; 64(4): 660-663.
- Ueno M, Oka A, Koeda T, Okamoto R, Takeshita K. Unilateral occlusion of the middle cerebral artery after varicella-zoster virus infection. *Brain and Development*. 2002; 24(2): 106-108.
- Haneline MT, Lewkovich GN. An Analysis of the Etiology of Cervical Artery Dissections: 1994 to 2003. *Journal of Manipulative and Physiological Therapeutics*. 2005;28(8): 617-622.
- Biller J, Sacco RL, Albuquerque FC, et al. Cervical Arterial Dissections and Association With Cervical Manipulative Therapy: A Statement for Healthcare Professionals From the American Heart Association/American Stroke Association. *Stroke*. 2014; 45(10): 3155-3174.

23. Guillon B, Berthet K, Benslamia L, Bertrand M, Bousser MG, Tzourio C. Infection and the risk of spontaneous cervical artery dissection: a case-control study. *Stroke*. 2003; 34(7): e79-81.
24. Silbert PL, Mokri B, Schievink WI. Headache and neck pain in spontaneous internal carotid and vertebral artery dissections. *Neurology*. 1995; 45(8): 1517-1522.
25. Daugherty WP, Clarke MJ, Cloft HJ, Lanzino GL. Going viral: fusiform vertebrobasilar and internal carotid aneurysms with varicella angiitis and common variable immunodeficiency. *J Neurosurg Pediatr*. 2009; 4(6): 528-531.
26. Kawatani M, Nakai A, Okuno T, Tsukahara H, Ohshima Y, Mayumi M. A case of intracranial saccular aneurysm after primary varicella zoster virus infection. *Brain and Development*. 2012; 34(1): 80-82.
27. Chan J, Bergstrom RT, Lanza DC, Oas JG. Lateral sinus thrombosis associated with zoster sine herpete. *American Journal of Otolaryngology*. 2004; 25(5): 357-360.
28. Abendroth A, Slobedman B. Varicella-Zoster Virus and Giant Cell Arteritis. *J Infect Dis*. 2021; 223(1): 4-6.