

Endobronchial Leiomyoma: A Rare Case Report

Khaldoon Abo Dakka¹, Omar Fawzi Lootah^{2*}, Syed Zafare Khatab^{3*} and Wessam Ahmad⁴

¹Specialist Thoracic Surgeon, Prime Hospital, Dubai, UAE

²Medical Student, Year 5, University of Sharjah, Sharjah, UAE

³Medical Intern, Prime Hospital, Dubai, UAE

⁴Medical Intern, Al Qassimi Hospital, Sharjah, UAE

*Corresponding author:

Omar Fawzi Lootah,
Medical Student, Year 5, University of Sharjah,
Sharjah, UAE

Received: 12 Aug 2024

Accepted: 16 Sep 2024

Published: 21 Sep 2024

J Short Name: ACMCR

Copyright:

©2024 Omar Fawzi Lootah. This is an open access article distributed under the terms of the Creative Commons Attribution License, which permits unrestricted use, distribution, and build up on your work non-commercially

Keywords:

Leiomyomas; Bronchial neoplasm; Bronchoscopic surgical procedure; Tracheal incision; Immunolabeling techniques

Citation:

Omar Fawzi Lootah, Endobronchial Leiomyoma: A Rare Case Report. Ann Clin Med Case Rep. 2024; V14(5): 1-5

1. Abstract

Bronchial leiomyoma is extremely rare. To date less than 60 cases have been reported in the world literature. The presented case here is a 41-year-old female who presented with a chronic cough and shortness of breath. Imaging revealed an intrabronchial mass causing left lung atelectasis. Diagnosis was made by histological and immunohistochemical examination of the specimens obtained during bronchoscopy. The mass was excised via bronchoscopy using endoscopic snare, and histopathology confirmed a benign leiomyoma, resulting in complete symptom resolution. Differential diagnoses of endobronchial lesions are discussed along with clinical, radiographic, pathologic characteristics and various treatment modalities for endobronchial leiomyomas.

2. Introduction

Endobronchial leiomyomas are rare, benign tumors originating from the smooth muscle layer of the bronchial wall [1]. Representing rare benign bronchial neoplasms, in which one third of these lesions are of endobronchial origin [2-3]. Despite their benign nature, endobronchial leiomyomas can cause significant clinical symptoms due to their size and location. Common presentations include cough, wheezing and chest discomfort (4). In this case report, we present a detailed account of a patient diagnosed with an endobronchial leiomyoma, highlighting the clinical presentation, diagnostic workup, surgical management, and postoperative outcomes. This report aims to contribute to the existing body of

knowledge on lung leiomyomas and provide insights into optimal management strategies for these rare but clinically significant tumors.

3. Case Presentation

A 41-year-old female presented with a chronic cough lasting for three months, accompanied by shortness of breath. Initial evaluation at a local hospital included a chest radiograph, which revealed volume loss of the left lung, mediastinal shift towards the left, and elevation of the left diaphragm representing lower lobe atelectasis (Figure 1). There was narrowing of the left bronchus with a heterogeneous area at the left hilum, possibly indicating a hilar mass. The right lung fields were clear with mild herniation across the midline. A subsequent contrast-enhanced computed tomography (CT) scan showed an intrabronchial mass obstructing the left lung (Figure 2). The patient was treated with antibiotics and mucolytics and was discharged after stabilization. The patient later again presented to our hospital with similar symptoms. Imaging confirmed intrabronchial obstruction in the left lung due to a tumor. Diagnostic bronchoscopy was planned, during which a moveable polypoid tumor was observed at the carina, moving with respiration. A biopsy was performed, and all post-obstructive secretions were cleared, resulting in symptom improvement, as confirmed by a follow-up chest X-ray. The biopsy results identified the mass as intrabronchial leiomyoma. The patient was admitted for further management. Rigid bronchoscopy was performed to improve the airway and ex-

cise the tumor. During the procedure, the left side was cleared of secretions post-obstruction, and bronchoalveolar lavage was performed to secure the airway for tumor removal. Given the mobility of the tumor, there was a risk of left lung blockage during excision. Therefore, a balloon catheter was inflated post-tumor to prevent the tumor from falling into the bronchus. A flexible bronchoscope was employed, and an endoscopic snare was used to perform thermal excision at the base of the tumor, which was located on the medial side of the left main bronchus at the carina. Rigid optical bronchoscopy forceps were used to remove it through the sheath

and the balloon catheter was used to pull out the tumor. The excised mass was sent for histopathological examination, which revealed that it was benign bronchial leiomyoma (Figure 5). Post-excision, the left lower lobe bronchus was cleared of secretions, and the tumor's base was checked to ensure no thermal injury or perforation, revealing normal mucosa. The patient was monitored for 24 hours post-procedure, showing significant improvement with complete expansion of the left lung, and no postoperative complications. A follow-up bronchoscopy was planned for one month later, but the patient was lost to follow-up.

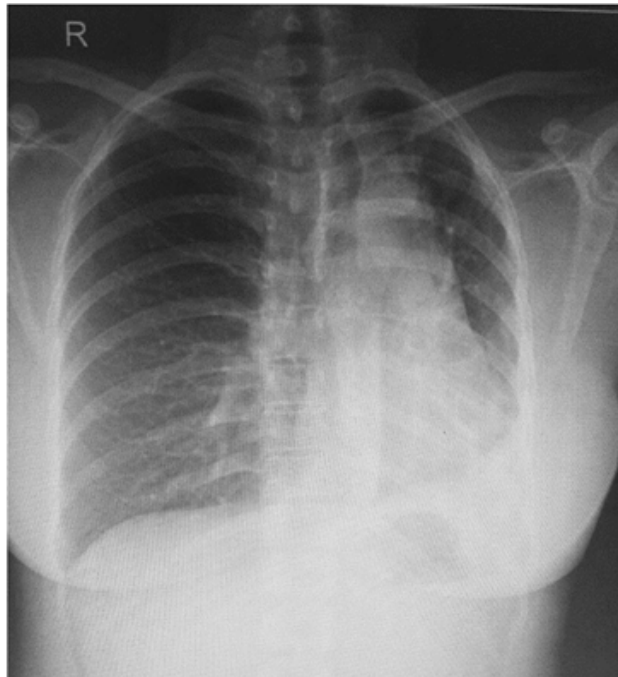


Figure 1: Which revealed volume loss of the left lung, mediastinal shift towards the left, and elevation of the left diaphragm representing lower lobe atelectasis.

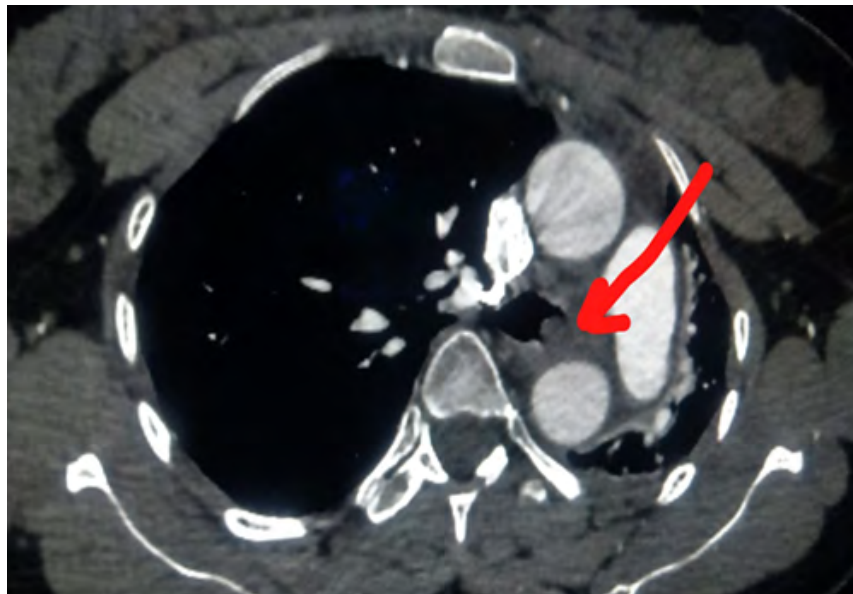


Figure 2: The right lung fields were clear with mild herniation across the midline. A subsequent contrast-enhanced computed tomography (CT) scan showed an intrabronchial mass obstructing the left lung.

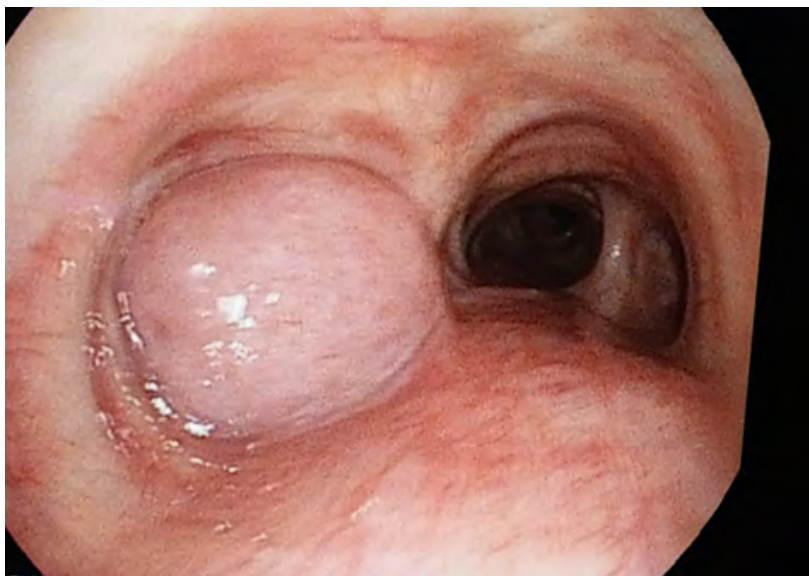

Figure 3: Image showing the intrabronchial polypoid mass located at the intersection of the trachea and the left main bronchus.

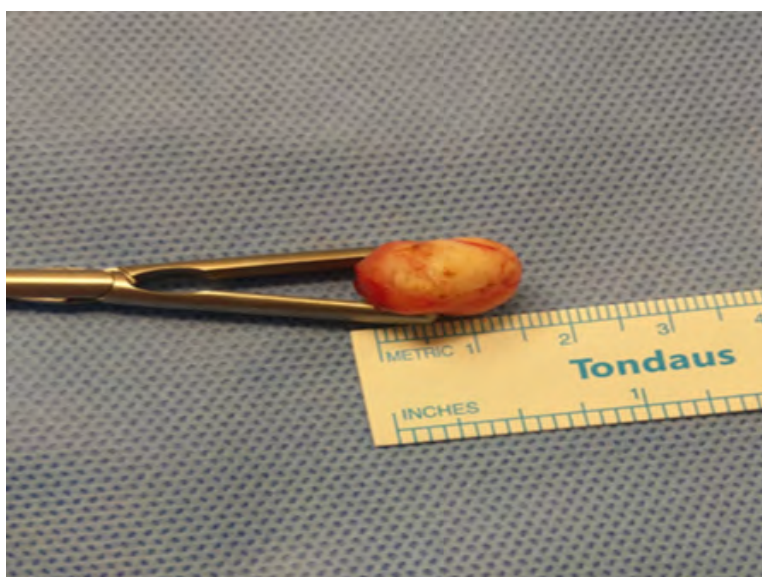


Figure 4: Excised Tumor mass.

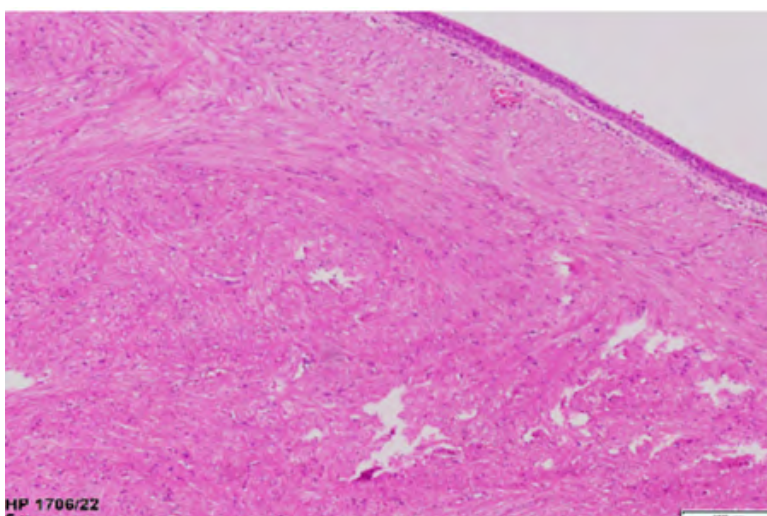


Figure 5: H&E image showing a well-circumscribed bronchial leiomyoma composed of spindle-shaped smooth muscle cells arranged in interlacing fascicles, with no evidence of malignancy.

4. Discussion

Leiomyoma is a benign tumor of the smooth muscles. It is common in the uterus, but very uncommon in the smooth muscles of extrauterine sites. When they are located in other than well-known locations, i.e., oesophagus, small intestine or uterus, generally they are symptom free and detected by chance while performing routine check-up measures or diagnostic studies for other pathologies. Other locations of leiomyomas include thyroid [5], extrapleural chest wall, lungs, trachea [6,7] and bronchi. Till date only very few cases have been reported in the world literature. Bronchial leiomyomas are benign tumors which predominantly occur in the fourth decade of life with female preponderance [8,9]. Bronchial leiomyomas are thought to arise from the smooth muscle cells of the bronchial wall and the interstitium or from the smooth muscles of the arterioles. Leiomyomas of the respiratory tract can be termed according to site of occurrence e.g, tracheal bronchial, parenchyma based on the anatomical site of occurrence. Symptoms depend on the location of the tumor, its size and the secondary changes of the lung distal to it. Patients with bronchial leiomyomas can have respiratory symptoms such as coughing, wheezing, dyspnea, chest pain or fever, due to partial or complete obstruction of the affected bronchus and superimposing infection resulting from atelectasis or bronchiectasis distal to obstruction [10-13,14]. Intermittent or constant dyspnea and wheezing are the most common symptoms of tracheal leiomyoma and have been erroneously ascribed to bronchial asthma [10,15]. Clubbing of the fingers may be the only clinical sign in children while hemoptysis occur when the tumor surface ulcerates [16]. The chest radiographic findings of endobronchial leiomyomas range from normal in patients with small tumor nodule to a solitary round mass or pneumonic infiltration, mediastinal shift, and collapse of lung to unilateral emphysema or hyperlucency according to obstructive sequel of bronchus due to the tumor [17-19]. A mass lesion with airway obstruction and/or pulmonary consolidation may be seen in computed tomography scans [17,19]. Also an iceberg appearance of the tumor (small intraluminal component and large extraluminal component) has been reported [17]. Calcification may rarely occur in the lesion [17,20]. In the present case, volume loss of the left lung, mediastinal shift towards the left, and elevation of the left diaphragm representing lower lobe atelectasis. The CT findings showed an intrabronchial mass obstructing the left lung. The exact diagnosis of endobronchial leiomyoma can be made by bronchoscopy in most cases because it can provide biopsy specimen for histological examination besides visualizing and localizing of the tumor [13,21]. Histological criteria, including cellularity, mitotic activity, and pleomorphism have been proposed to differentiate between benign and malignant smooth muscle neoplasms. The principle criterion is mitotic activity that should be less than 5 per 50 HPF [22]. Differential diagnosis includes other spindle cell tumors and tumor lesions such as bronchial carcinoid of the large spindle cell

variant, pleural fibrous mesothelioma, metastatic malignant melanoma, metastatic synovial sarcoma and occasionally plasma cell granuloma [19,23]. To discriminate these lesions, immunohistochemical studies can be of great help in which both benign and malignant smooth muscle neoplasms show muscle markers like actin and desmin [23]. The treatment should be as conservative as possible since the tumor is usually benign. These tumors do not need to be removed unless clinically causing symptoms. Other treatment options include resection, highly active antiretroviral (HAART) in cases of AIDS and less often chemotherapy and radiotherapy. Surgery remains the mainstay of treatment for bronchial leiomyoma, type of surgery depending upon the location of the tumour. Treatment of bronchial leiomyoma should be conservative since the tumor is mostly benign. Localized resection, bronchotomy, segmental resection or bronchoscopic removals are different modes of surgery employed to treat the tumour. YAG laser or electrocautery can be used via bronchoscope to resect the tumor [24].

5. Conclusion

In summary, endobronchial leiomyomas are among the rarest of benign tumors of the respiratory tract. These neoplasms may mimic asthma or other obstructive diseases of the lung and should be kept in mind as a rare cause of asthma like symptoms especially in an adult female who is no longer responsive to bronchodilators. Histological examination and immunohistochemistry provide the exact diagnosis which can always exclude the possibility of a metastatic leiomyoma/leiomyosarcoma. Treatment is as conservative as possible and includes bronchial resection, segmentectomy, lobectomy or pneumonectomy.

References

1. Leiomyomas of the lower respiratory tract.
2. Shahian DM, McEnany MT. Complete endobronchial excision of leiomyoma of the bronchus. *J Thorac Cardiovasc Surg.* 1979; 77: 87-91.
3. Vera-Roman JM, Sobonya RE, Gomez-Garcia JL. Leiomyoma of the lung. Literature review and case report. *Cancer* 1983; 52: 936-41.
4. Benign Endobronchial Tumors: A Clinicopathologic Review. 2021.
5. Erkilic S, Erkilic A, Bayazit YA. Primary leiomyoma of the thyroid gland. *J Laryngol Otol.* 2003; 117: 832-4.
6. Park JS, Lee M, Kim HK, Choi YS, Kim K, Kim J. Primary leiomyoma of the trachea, bronchus, and pulmonary parenchyma: A single-institutional experience. *Eur J Cardiothorac Surg.* 2012; 41: 41-5.
7. Bharadwaj SC, Unruh HW. Leiomyoma of the trachea. *Ann Thorac Surg.* 2012; 93: 669-70.
8. Taylor TL, Miller DR. Leiomyoma of the bronchus. *J Thorac Cardiovasc Surg.* 1969; 57: 245-8.
9. Sakaguchi M, Nakamura T, Shimizu T, Koike S, Kumeda S, Shigematsu H, et al. Leiomyoma of the lung: A case report. *Kyobu Geka.* 1999; 52: 157-60.

10. White SH, Ibrahim NB, Forrester- Wood CP, Jeyasingham K. Leiomyomas of the lower respiratory tract. *Thorax*. 1985; 40(4): 306-11.
11. Olgun N, Ozaksoy D, Uçan ES, Türkmen MA, Canda T, Oto O. Paediatric endobronchial leiomyoma mimicking asthma. *Respir Med*. 1995; 89(8): 581-2.
12. Ayabe H, Tsuji H, Tagawa Y, Tomita M, Tsuda N, Chen J. Endobronchial leiomyoma: report of a case treated by broncoplasty and a review of the literature. *Surg Today*. 1995; 25(12): 1057-60.
13. Ozelik U, Kotiloglu E, Goçmen A. Endobronchial leiomyoma: a case report. *Thorax*. 1995; 50(1): 101-2.
14. Metta H, Corti M, Redini L, Dure R, Campitelli AM, Narbaitz M. Endobronchial leiomyoma: an unusual non- defining neoplasm in a patient with AIDS. *Rev Inst Med Trop Sao Paulo*. 2009; 51(1): 53-5.
15. Tamura M, Murata T, Kurumaya H, Ohta Y. Leiomyoma of an accessory tracheal bronchus. *Ann Thorac Surg*. 2004; 78(6): 2163-5.
16. Vera- Román JM, Sobonya RE, Gomez- Garcia JL, Sanz- Bondia JR, Paris- Romeu F. leiomyoma of the lung: Literature review and case report. *Cancer*. 1983; 52(5): 936-41.
17. Kim YK, Kim H, Lee KS, Han J, Yi CA, Kim J, et al. Airway leiomyoma: imaging findings and histopathologic comparisons in 13 patients. *AJR Am J Roentgenol*. 2007; 189(2): 393-9.
18. Kim KH, Suh JS, Han WS. Leiomyoma of the bronchus treated by endoscopic resection. *Ann Thorac Surg*. 1993; 56(5): 1164-6.
19. Bilgin S, Yılmaz A, Okur E, Düzgün S, Tahaoğlu C, Akkaya E. Primary endobronchial leiomyoma: a case report. *Tuberk Toraks*. 2004; 52(3): 272-4.
20. Ko SM, Han SB, Lee SK, Woo SK, Kim MJ, Keum DY, et al. Calcified endobronchial leiomyoma. *Br J Radiol*. 2007; 80(953): e91-3.
21. Percinel S, Okcu Heper A, Savas B, Ceyhan K, Enon S, Gungor A. Bronchial leiomyoma with presumptive diagnosis of lung carcinoma: a case report and review of the literature. *Turkish Resp J*. 2008; 9(1): 41-5.22.
22. Sharifi N, Massoum SH, Shahri MK, Rezaei A, Ashari AA, Attar AS, et al. Endobronchial leiomyoma: Report of a case successfully treated by bronchoscopic resection. *J Res Med Sci*. 2010; 15: 364-70.
23. Gal AA, Brooks JS, Pietra GG. Leiomyomatous neoplasms of the lung: a clinical, histologic, and immunohisto- chemical study. *Mod Pathol*. 1989; 2(3): 209-16.
24. Endobronchial leiomyoma: A rare and innocent tumour of the bronchial tree. 2013.