

A 57-Year-Old Man with *Mycobacterium Mageritense* and *Pneumocystis Jirovecii* Coinfection after Loss to Follow-Up for 9 Years

Wei-Ping Chen^{1,2}, Ning-Chi Wang^{2*}

¹Department of Internal Medicine, Taoyuan Armed Forces General Hospital, Taoyuan 325, Taiwan

²Division of Infectious Diseases and Tropical Medicine, Department of Internal Medicine, Tri-Service General Hospital, Taipei 114, Taiwan

*Corresponding Author:

Ning-Chi Wang, Division of Infectious Diseases and Tropical Medicine, Department of Internal Medicine, Tri-Service General Hospital Taipei 114, Taiwan

Received: 11 Aug 2024

Accepted: 19 Aug 2024

Published: 23 Aug 2024

J Short Name: ACMCR

Copyright:

©2024 Wang NC, This is an open access article distributed under the terms of the Creative Commons Attribution License, which permits unrestricted use, distribution, and build upon your work non-commercially.

Citation:

Wang NC. A 57-Year-Old Man with *Mycobacterium Mageritense* and *Pneumocystis Jirovecii* Coinfection after Loss to Follow-Up for 9 Years: A Rare Case Report. *Anna Clin Med Case Rep.* 2024; 14(3): 1-3

Keywords:

Mycobacterium mageritense; *Pneumocystis jirovecii*; Human immunodeficiency virus; Opportunistic infections

1. Abstract

Future randomized controlled trials are required to develop better treatment strategies. Herein, we present a case of pneumonia caused by *M. mageritense*. A 57-year-old man with a history of being a human immunodeficiency virus (HIV) carrier and who had been irregularly followed up in outpatient clinics for approximately 9 years was previously treated with Kaletra and Kivexa. He had a cough with sputum and shortness of breath for week. The patient presented to the emergency room with respiratory distress. Subsequent high-resolution computed tomography of the thorax revealed thickening of the interstitial lines, a honeycomb pattern in both lungs, and patchy consolidation in the right lower lobe. A sputum test yielded positive results for *Pneumocystis jirovecii*. Trimethoprim/sulfamethoxazole was prescribed for the *P. jirovecii* infection. *Mycobacterium* culture identified *M. mageritense* using a matrix-assisted laser desorption ionization time-of-flight method. Ciprofloxacin, linezolid, and imipenem/cilastatin were prescribed for 16 d, followed by a shift to linezolid and ciprofloxacin after discharge. After 8 months of treatment, the patient improved well. *M. mageritense* can induce infections in both immunocompetent and immunocompromised individuals. It has a broad spectrum of clinical manifestations. Treatments include surgical intervention and combined antibiotics [1]. *P. jirovecii*-induced pneumonia (PJP) and nontuberculous mycobacterial diseases share overlapping risk factors. Our case demonstrated coinfection with *M. mageritense* and *P. jirovecii*. Careful differentiation of opportunistic infections in patients with HIV is warranted. However, the optimal antibiotic therapy duration for *M. mageritense* remains uncertain. Future randomized controlled trials are imperative for the development of enhanced treatment strategies.

2. Introduction

Opportunistic infections have long posed significant challenges to the management of immunocompromised patients, particularly those affected by acquired immunodeficiency syndrome (AIDS). Among the myriads of pathogens contributing to the burden of opportunistic infections, nontuberculous mycobacterial (NTM) infections stand out because of the widespread presence of these bacteria in the environment and capacity to cause diseases in both immunocompetent and immunocompromised hosts. There are more than 190 NTM species and subspecies [2]. They can be divided into two categories based on their growth rates: "rapid growth" and "slow growth". Rapidly growing mycobacteria are generally defined as nontuberculous species that grow within 7 days in laboratory media [3]. The current official ATS/ERS/ESCMID/IDSA Clinical Practice Guidelines focus on pulmonary disease in adults without cystic fibrosis or human immunodeficiency virus (HIV) infection) caused by the most common NTM pathogens, including *Mycobacterium avium*

complex (MAC), *Mycobacterium kansasii*, and *Mycobacterium xenopi*, among the slow-growing NTM, and *Mycobacterium abscessus*, among the rapidly growing NTM [4]. *M. mageritense* is a rapidly growing bacterium. As there are no specific guidelines for *M. mageritense*, the treatment of infections caused by this bacterium is determined according to established clinical practices [4,5].

3. Case Presentation, Management, and Follow-Up

We present the case of a 57-year-old man with a history of HIV infection who underwent Kaletra and Kivexa treatment. The patient was lost to follow-up after 9 years. At that time, he had a cough with sputum and shortness of breath for 1 week. He visited the emergency department and was diagnosed with fever. The patient appeared to have respiratory distress. His blood pressure was 94/72 mm Hg, his pulse was 90 beats per minute, his temperature was 35.4°C, and he had a respiration rate of 26 breaths per minute. The patient presented with septic shock and respiratory distress, leading to admission with the impression of community-acquired pneumonia. The initial laboratory data revealed a white blood cell count of 6,760/μL; a hemoglobin concentration of 12.5 g/dL; an immature granulocyte frequency of 6.1%; a C-reactive protein concentration of 9.06 mg/dL; an HIV viral load of 371,000 cp/mL; a CD4⁺ cell count of 15/μL; a cytomegalovirus viremia < 500 copies/mL; and a positive polymerase chain reaction (PCR) result for *P. jirovecii* in sputum. *Salmonella* group D was isolated from a single blood culture set. Chest radiography revealed patchy opacities in both lungs (Figure 1). Chest high-resolution computed

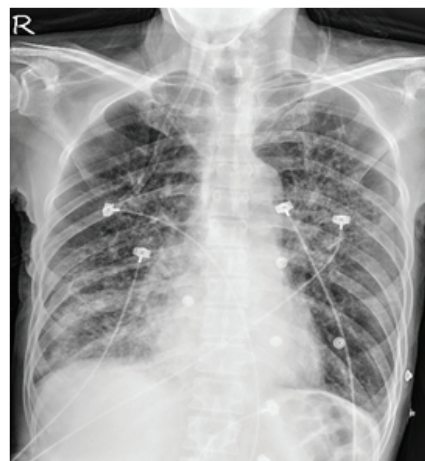


Figure 1: X-ray showing patchy opacity in the bilateral lungs.

tomography revealed thickening of the interstitial lines, a honeycomb pattern in both lungs, and patchy consolidation in the right lower lobe (Figure 2A). Ceftriaxone, trimethoprim/sulfamethoxazole (TMP/SMX), and ganciclovir were prescribed for initial infection control. The patient's fever gradually subsided. One week after the initiation of TMP/SMX, Biktarvy was prescribed to treat AIDS. However, *M. mageritense* was identified in one set of *Mycobacterium* cultures. Ciprofloxacin, linezolid, and imipenem/cilastatin were added to treat the *M. mageritense* infection. The patient's condition improved after the treatment. Linezolid and ciprofloxacin were administered following discharge. Follow-up in the outpatient department (OPD) indicated an undetectable HIV viral load. After 8 months of treatment, the patient underwent high-resolution computed tomography for a follow-up assessment (Figure 2B), and a focal nodular opacity was observed in the right upper lung, along with bilateral emphysema. The opacity was completely resolved. The patient recovered remarkably.

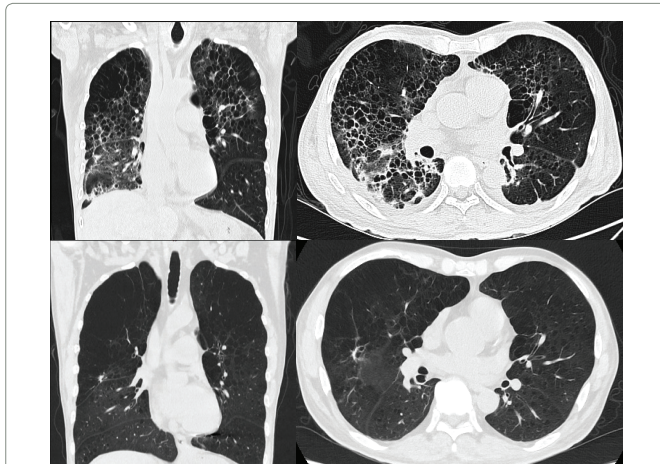


Figure 2: Comparison of High-Resolution Computed Tomography (HRCT) Images Before and After Treatment A) High-resolution computed tomography revealed patchy consolidation, thickening of interstitial lines, pulmonary emphysema, a honeycomb pattern in both lungs, and patchy consolidation in the right lower lobe initially. B) Some focal nodular opacity was observed in the right upper lung, along with bilateral emphysema after finishing treatment.

4. Discussion

Opportunistic infections frequently occur in immunosuppressed patients, such as those with AIDS. Due to the rapid development of effective HIV treatments, the incidence of opportunistic infections has significantly decreased. However, some patients fail to adhere to their medications, resulting in immunodeficiency and subsequent opportunistic infections. According to a retrospective study, 50% of respiratory specimens from patients with HIV admitted for pneumonia tested positive for NTM pathogens [6]. *M. mageritense* was first isolated in Spain in 1987. In 1997, Domenech et al. [5], named this pathogen *M. mageritense* [7]. The disease association was described in 2002 [5]. *M. mageritense* can induce infections in both immunocompetent and immunocompromised individuals [5,8]. It is a rapidly growing *Mycobacterium* commonly found in the environment, such as in soil, natural products, municipal water supplies, and nosocomial settings [9,10]. To identify *M. mageritense*, a multifaceted approach involving PCR, restriction enzyme analysis of the 65-kDa heat shock protein (*hsp*) and *rpoB* gene sequences, partial sequencing of the *16S rRNA* gene, and high-performance liquid chromatography was employed. Finally, matrix-assisted laser desorption/ionization time-of-flight mass spectrometry was implemented, which is a rapid and precise method to analyze specific patterns in bacterial protein spectra and differentiate between closely related species [5, 11, 12]. *M. mageritense* is associated with a broad spectrum of clinical manifestations, including lymphadenitis, pulmonary disease [13], pleural effusion [8,11], skin and soft tissue infections [14], osteomyelitis [5], bloodstream infections [15], endocarditis [15], central nervous system infections [16], catheter-associated infections [10], prosthetic joint infections [17], and sinusitis [5]. Several key risk factors for the development of PJP have been identified. One of the primary risk groups includes individuals with

HIV infection, particularly those with a CD4⁺ lymphocyte count less than 200 cells/mm³ and a high HIV viral load [18, 19]. Moreover, predisposing factors for PJP in HIV-negative patients include corticosteroid treatment [20], cirrhosis [21], cystic fibrosis [22], CD4⁺T-lymphocytopenia [23], tumor necrosis factor (TNF) α inhibitor treatment [24], and chemotherapy plus corticosteroids [25]. A study of immune control of *M. abscessus* and *M. fortuitum* in murine hosts demonstrated that T cells are crucial for a protective immune response [26, 27]. Chronic obstructive pulmonary disease (COPD), α -1-antitrypsin deficiency, cystic fibrosis, gastric reflux disease with proton pump inhibitors use, an older age, bronchiectasis, rheumatoid arthritis, anti-TNF therapy, inherited deficiencies in the production or response to interferon-gamma (IFN- γ), and HIV infection with deficiencies in CD4⁺ T cell function also predispose to NTM infections [28-32]. PJP and NTM infections share overlapping risk factors, which led to coinfection in our patient. This is a rare case of someone who had HIV with AIDS and acquired *M. mageritense* and *P. jirovecii* coinfection. Treatment for *M. mageritense* associated skin and soft tissue infection, prosthetic Joint Infection and osteomyelitis include surgical intervention and antibiotics [1,5,17]. A thorough literature review indicated that *M. mageritense* is susceptible to ciprofloxacin and sulfamethoxazole, and susceptible or intermediate to amikacin, linezolid, imipenem, and cefoxitin. The presence of the inducible erythromycin methylase gene (*erm 40*) [5], leading to macrolide resistance. Levofloxacin is avoided as monotherapy because of the risk of developing mutational resistance [5]. The established duration of antibiotics ranged from 9 weeks to 14 months (8 weeks of induction and 4 months of maintenance treatment) [1, 11, 17, 33-35]. Currently, controlled studies that provide guidance for determining the optimal duration of parenteral and oral antibiotics for *M. mageritense* infections are lacking. Clinical guidance relies primarily on case report information. There are no established guidelines for the treatment of *M. mageritense*. Future randomized controlled trials are required to develop better treatment strategies.

5. Conclusion

Despite advances in HIV treatment, opportunistic infections remain a concern in patients with AIDS. *M. mageritense* affects both immunocompetent and immunocompromised individuals. PJP and NTM infections share common risk factors related to immune function, potentially resulting in coinfection. Careful differentiation and treatment are essential for effective management of complex cases. The optimal duration of antibiotic therapy for *M. mageritense* is uncertain, and clinical guidance relies heavily on case reports rather than established guidelines. Future randomized controlled trials are required to develop improved treatment strategies.

References

- Joya CA, C Deegan, TD Gleeson. *Mycobacterium mageritense* infection following mastectomy and breast reconstruction requiring triple antibiotic therapy and surgical debridement. *BMJ Case Rep.* 2021; 14(2).
- Genus *Mycobacterium*. 2021.
- Brown-Elliott BA, Wallace J, Richard J, *Mycobacterium*. Clinical and Laboratory Characteristics of Rapidly Growing *Mycobacteria*, in *Manual of Clinical Microbiology*. 2011; 525-538.
- Daley CL. Treatment of Nontuberculous *Mycobacterial* Pulmonary Disease: An Official ATS/ERS/ESCMID/IDSA Clinical Practice Guideline. *Clinical Infectious Diseases*. 2020; 71(4): e1-e36.
- Wallace RJ. Clinical and laboratory features of *Mycobacterium mageritense*. *J Clin Microbiol.* 2002; 40(8): 2930-5.
- Lapinel NC. Prevalence of non-tuberculous mycobacteria in HIV-infected patients admitted to hospital with pneumonia. *Int J Tuberc Lung Dis.* 2019; 23(4): 491-497.
- Domenech P. *Mycobacterium mageritense* sp. nov. *Int J Syst Bacteriol.* 1997; 47(2): 535-40.
- Niitsu T. Pleural Effusion Caused by *Mycobacterium mageritense* in an Immunocompetent Host: A Case Report. *Frontiers in Medicine*, 2021; 8.
- Wang Y. Isolation and identification of mycobacteria from soils at an illegal dumping site and landfills in Japan. *Microbiol Immunol.* 2006;

- 50(7): 513-24.
10. Koyama T. Device-related *Mycobacterium mageritense* Infection in a Patient Treated with Nivolumab for Metastatic Breast Cancer. *Intern Med.* 2021; 60(21): 3485-3488.
 11. Hirabayashi R. A case of pleural effusion caused by *Mycobacterium fortuitum* and *Mycobacterium mageritense* coinfection. *BMC Infect Dis.* 2019; 19(1): 720.
 12. Nguyen DC. A Novel Rapidly Growing Mycobacteria (RGM) Species Causing Soft Tissue and Orthopedic Hardware Infection After Trauma. *Open Forum Infectious Diseases.* 2019; S492-S492.
 13. Gordon Huth R, BA Brown-Elliott, RJ Wallace. *Mycobacterium mageritense* pulmonary disease in patient with compromised immune system. *Emerg Infect Dis.* 2011; 17(3): 556-8.
 14. Etesami I. *Mycobacterium mageritense* subcutaneous infection following cryopreserved facial fat injection: A report of 2 cases. *JAAD Case Reports.* 2022; 22: 78-81.v
 15. McMullen AR. Brown-Pigmented *Mycobacterium mageritense* as a Cause of Prosthetic Valve Endocarditis and Bloodstream Infection. *J Clin Microbiol.* 2015; 53(8): 2777-80.
 16. Munoz-Sanza A. *Mycobacterium mageritense* meningitis in an immunocompetent patient with an intrathecal catheter. *Enfermedades Infecciosas y Microbiología Clínica.* 2013; 31(1): 59-60.
 17. Caravedo Martinez MA. LS Blanton, *Mycobacterium mageritense* Prosthetic Joint Infection. *Case Rep Infect Dis.* 2020; 8845430.
 18. Phair J. The risk of *Pneumocystis carinii* pneumonia among men infected with human immunodeficiency virus type 1. Multicenter AIDS Cohort Study Group. *N Engl J Med.* 1990; 322(3): 161-5.
 19. Wang HW. Mortality predictors of *Pneumocystis jirovecii* pneumonia in human immunodeficiency virus-infected patients at presentation: Experience in a tertiary care hospital of northern Taiwan. *J Microbiol Immunol Infect.* 2011; 44(4): 274-81.
 20. Vargas Barahona L. Previous corticosteroid exposure associates with an increased *Pneumocystis jirovecii* pneumonia mortality among HIV-negative patients: a global research network with a follow-up multicenter case-control study. *Ther Adv Infect Dis.* 2023; 10: 20499361231159481.
 21. Hadfield NJ, S Selvendran, M P Johnston. Fatal *Pneumocystis jirovecii* pneumonia in a non-immunocompromised patient with alcohol-related liver cirrhosis. *Scottish Medical Journal.* 2019; 64(4): 148-153.
 22. Bonnet P. *Pneumocystis jirovecii* in Patients with Cystic Fibrosis: A Review. *Front Cell Infect Microbiol.* 2020; 10: 571253.
 23. Jundt MC. Idiopathic CD4 Lymphocytopenia with Fulminant *Pneumocystis jirovecii* Pneumonia. *American Journal of Respiratory and Critical Care Medicine.* 2018; 199(8): e35-e36.
 24. Mori S, M Sugimoto. *Pneumocystis jirovecii* Pneumonia in Rheumatoid Arthritis Patients: Risks and Prophylaxis Recommendations. *Clin Med Insights Circ Respir Pulm Med.* 2015; 9: 29-40.
 25. Tiantian C. *Pneumocystis jirovecii* pneumonia in a patient receiving chemotherapy for advanced prostatic cancer: a case report. *J Int Med Res.* 2022; 50(6): 3000605221105358.
 26. Rottman M. Importance of T Cells, Gamma Interferon, and Tumor Necrosis Factor in Immune Control of the Rapid Grower *Mycobacterium abscessus* in C57BL/6 Mice. *Infection and Immunity.* 2007; 75(12): 5898-5907.
 27. Parti RPS. Murine infection model for *Mycobacterium fortuitum*. *Microbes and Infection.* 2005; 7(3): 349-355.
 28. Nightingale SD. Incidence of *Mycobacterium avium*-intracellulare complex bacteremia in human immunodeficiency virus-positive patients. *J Infect Dis.* 1992; 165(6): 1082-5.
 29. Corbett EL. Risk factors for pulmonary mycobacterial disease in South African gold miners. A case-control study. *Am J Respir Crit Care Med.* 1999; 159(1): 94-9.
 30. Pereira AC. Non-Tuberculous Mycobacteria: Molecular and Physiological Bases of Virulence and Adaptation to Ecological Niches. *Microorganisms.* 2020; 8(9).
 31. Kim Y. Gastroesophageal Reflux Disease Increases Susceptibility to Nontuberculous Mycobacterial Pulmonary Disease. *Chest.* 2023; 163(2): 270-280.
 32. Sexton P, AC Harrison. Susceptibility to nontuberculous mycobacterial lung disease. *Eur Respir J.* 2008; 31(6): 1322-33.
 33. Gira AK. Furunculosis due to *Mycobacterium mageritense* associated with footbaths at a nail salon. *J Clin Microbiol.* 2004; 42(4): 1813-7.
 34. Appeltgren P. Late-onset posttraumatic skin and soft-tissue infections caused by rapid-growing mycobacteria in tsunami survivors. *Clin Infect Dis.* 2008; 47(2): 11-6.
 35. Okabe T. *Mycobacterium mageritense* Parotitis in an Immunocompetent Adult. *Indian J Microbiol.* 2018; 58(1): 28-32.