Annals of Clinical and Medical Case Reports

Case Report

ISSN 2639-8109 | Volume 13

Metastatic Paraganglioma with Fumarate Hydratase Missense Mutation

Winn SP[1], Bhasin PG[2] and Huang YJ[2]

[1]Department of Internal Medicine, Maimonides Medical Center, Brooklyn, NY, USA

[2]Department of Hematology/Oncology, Maimonides Cancer Center, Brooklyn, NY, USA

***Corresponding author:**

Soe P Winn,
Department of Internal Medicine, Maimonides Medical Center, Brooklyn, NY, USA

Received: 26 Feb 2024
Accepted: 06 Apr 2024
Published: 12 Apr 2024
J Short Name: ACMCR

Copyright:

©2024 Winn SP. This is an open access article distributed under the terms of the Creative Commons Attribution License, which permits unrestricted use, distribution, and build upon your work non-commercially

Citation:

Winn SP, Metastatic Paraganglioma with Fumarate Hydratase Missense Mutation. Ann Clin Med Case Rep. 2024; V13(10): 1-5

1. Abstract

1.1. Background: Majority of Pheochromocytoma (PCC) and paraganglioma (PGL) cases are benign without malignant potential but genetic assessment is recommended for all PCC/PGL patients, because of the associated with ig hereditary germline mutations which play a vital role in pathogenesis of tumorigenesis and metastasis.

1.2. Case: This case showed a previously localized pheochromocytoma and right adrenal resection three years prior to presentation as a metastatic paraganglioma with spinal cord compression at C7, extensive osseous involvement, liver metastases, and the patient has been found to harbor a fumarate hydratase (FH) missense mutation (c.934T>C; p.Phe312Leu).

1.3. Discussion: Disruption of the normal FH gene function is linked to the impaired degradation of hypoxia-inducible factor-alpha (HIF-α), and T cell suppression leading to evolution, and maintenance of the tumor microenvironment. FH gene mutation is associated with Hereditary Leiomyomatosis and Renal Cell Cancer (HLRCC), isolated leiomyomas, renal cell carcinoma (RCC), and uterine leiomyosarcoma (ULMS).

1.4. Conclusion: Our case highlights the importance of genetic assessment for hereditary germline mutations in all cases of PCC/PGLs and presents a unique occurrence of metastatic pheochromocytoma with a rare FH gene mutation.

2. Introduction

Pheochromocytoma (PCC) and paraganglioma (PGL) are uncommon neuroendocrine tumors that originate from chromaffin cells in the adrenal medulla and paraganglia, respectively [1]. Paragangliomas can be categorized as sympathetic or parasympathetic. Sympathetic paragangliomas develop from chromaffin cells situated along the sympathetic chain in the chest, abdomen, and pelvis. On the other hand, parasympathetic paragangliomas arise from parasympathetic nerves in the neck, base of the skull, and, in some instances, the mediastinum. Norepinephrine, epinephrine, and, in certain cases, dopamine is typically produced by PCC and sympathetic PGL, leading to symptoms such as hypertension, intermittent headaches, sweating, palpitations, nausea, vomiting, and tremors. Conversely, parasympathetic PGLs are often non-functional, with symptoms primarily attributed to their mass effect. The majority of PCC/PGL cases are benign, with an estimated malignancy rate of approximately 10 to 15%, influenced by patient demographics, tumor count, and histopathological characteristics [2], [3]. Certain studies suggest that larger tumor size, extra-adrenal location, and the presence of necrosis on pathology slides correlate with malignant PCC/PGL and an unfavorable prognosis [46]. The Pheochromocytoma of the Adrenal gland Scales score is a recognized tool for predicting malignant transformation. However, no definitive consensus exists for predicting metastatic potential or poor prognosis, with diagnosis only possible upon identification of chromaffin tumor cells in distant sites like the liver, bone, lung, and lymph nodes [7], [8]. As such, genetic assessment is recommended for all PCC/PGL patients, given that over 35% of cases are associated with hereditary germline mutations [9]. Among the several germline mutations linked to PCC/PGL, mutations in genes like VHL, succinate dehydrogenase (SDH)-related genes, NF1, and

RET proto-oncogenes are common, and they tend to be more prevalent in extra-adrenal tumors than adrenal sources [10], [11]. Other gene mutations, such as fumarate hydratase (FH) and isocitrate dehydrogenase (IDH1), have garnered less attention in the literature due to their lower incidence rates. These mitochondrial enzymes play a pivotal role in cellular respiration, particularly in the electron transport chain and the Krebs' citric acid cycle. Several loss-of-function anomalies in SDH, IDH, and FH have been identified and implicated in developmental malformations during embryogenesis, as well as in tumorigenesis, progression, and metastasis [12-14]. These mitochondrial enzyme mutations have been associated with various conditions, including hereditary leiomyomatosis and renal cell cancer (HLRCC), hereditary PCC, PGL, gastrointestinal stromal tumors (GISTs), pituitary tumors, ovarian cancer, and renal cell carcinoma (RCC). In this context, we present a case of metastatic pheochromocytoma with a history of localized pheochromocytoma and previous right adrenal resection three years prior to presentation. The patient is now afflicted with spinal cord compression at C7, extensive osseous involvement, liver metastases, and has been found to harbor a fumarate hydratase missense mutation (c.934T>C; p.Phe312Leu).

3. Case Presentation

A 59-year-old male presented with a 5-week history of right shoulder and neck pain. The pain was rated at 5-7/10, described as shooting in character, and radiated to the right arm. He reported gradual onset numbness and fine motor movement difficulties in his right ring and little fingers. The pain and numbness intensified with head movement but improved with rest. Notably, these symptoms were not associated with wrist pain, wrist or hand joint stiffness, or any warmth or swelling in the upper extremities. Initially managed conservatively with physical therapy, his pain worsened over time. The patient's medical history included hypertension and a previous diagnosis of right adrenal pheochromocytoma. He underwent right adrenal resection in September 2020. He was a lifelong non-smoker, abstained from alcohol and illicit drugs, and had no family history of congenital disorders or malignancies. His only medications were nifedipine and metoprolol; he did not use any herbal supplements or over-the-counter medications. On physical examination, his vital signs were stable with a normal heart rate of 70 bpm and oxygen saturation of 98% on room air. The patient was alert, oriented, and cardiovascular, respiratory, and abdominal examinations were unremarkable. Musculoskeletal examination revealed mild pain and numbness in his right ring and little fingers, diffuse tenderness in his neck and right shoulder, and no sensory deficits or muscle wasting in the hand.

Initial laboratory results, including CBC, CMP, and coagulation studies, were mostly within normal ranges, except for an elevated BUN of 24 and creatinine of 1.6. A Computed Tomography (CT) scan of the spine demonstrated a destructive enhancing mass in the C7 vertebral body invading the right pedicle, causing a C7 compression fracture, moderate to severe cord compression, and right neural foraminal stenosis. Additionally, a lytic lesion in the L1 vertebral body without fracture was observed, and a CT of the chest, abdomen, and pelvis with IV contrast revealed multiple small enhancing lesions in the liver up to 1.0 cm in diameter, along with extensive retroperitoneal lymphadenopathy. Follow-up labs indicated a normal normetanephrine level of 87, elevated metanephrine of 4497 (reference range: 0-244 pg/ml), elevated serotonin of 572 (reference range: <330 ng/ml), chromogranin of 1376 (reference range: 0-101.8 ng/ml), and CEA of 4.5 (reference range: 0.3-2.5 ng/ml). The patient received a posterior spinal instrumentation and fusion (PSIF) of C4-T2 and C6-7 laminectomy, along with a biopsy of the C7 vertebral body. The C7 biopsy yielded fragments of fibroadipose tissue, skeletal muscle, and bone with crushing artifact, lacking malignancy confirmation. Subsequently, a CT-guided L1 lesion biopsy revealed scanty fragments of a metastatic neuroendocrine tumor or paraganglioma. The biopsy was positive for synaptophysin, chromogranin, and GATA3, with a Ki67 of 5-10%, while being negative for AE1/AE3, CAM5.2, CK7, CK20, S100, CDX2. Few cells exhibited weak positivity for TTF-1. The patient was prescribed calcium, vitamin D, and denosumab, and underwent post-operative radiation therapy (30 grays in 10 fractions) targeting the surgical sites of the spine. Upon referral to an endocrinologist, the patient's treatment regimen was adjusted to include phenoxybenzamine instead of metoprolol. A 68Ga-DOTATE PET/CT scan demonstrated widespread metastatic bone disease expressing SSTR2, involving vertebral bodies and ribs, with liver segment 4 metastasis. Genetic testing identified a pathologic variant of the fumarate hydratase missense mutation (c.934T>C; p.Phe312Leu), alongside other genes (EGLN1, K1F1b, MAX, MEN1, NF1, RET, SDHA, SDHAF2, SDHB, SDHC, SDHD, TEME127, VHL). Genetic counseling was offered to both the patient and family members. Treatment recommendations included initiation of Lu-177 DOTATATE radioisotope therapy or 131-I MIBG treatment (Figure 1 and 2).

Figure 1: CT (spine) sagittal view showing C7 compression fracture (yellow arrow) and L1 vertebral body lytic lesion (blue arrow)

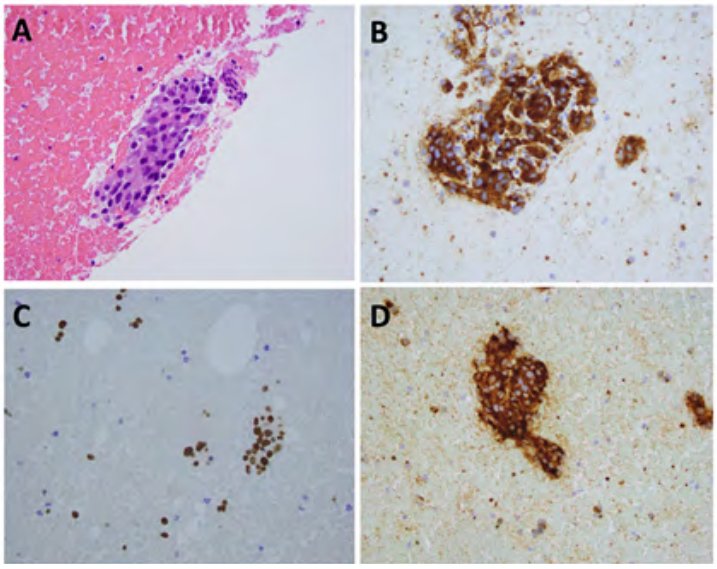

Figure 2: Needle biopsy of the L1 vertebral body showing clusters of tumor cells with abundant eosinophilic or amphiphilic cytoplasm and nuclei with fine chromatin (A 400x). IHC studies showing tumor cells positive for synaptophysin (B 400x), GATA3 (C 400x) and chromogranin (D 400x).

4. Discussion

Fumarate hydratase is a critical component of human energy production, recognized later for its pivotal role as a tumor suppressor gene within our biological framework [12]. The FH gene is located at chromosome 1q43 and encompasses 10 exons. Predominantly, missense mutations (57%) constitute the most common form of FH gene mutations, followed by frameshifts and nonsense mutations [15]. At present, the clinical variant database lists 196 pathogenic variants within the FH gene [16]. An analysis of FH gene mutation literature suggests a strong association with Hereditary Leiomyomatosis and Renal Cell Cancer (HLRCC), isolated leiomyomas, renal cell carcinoma (RCC), and uterine leiomyosarcoma (ULMS). However, recent research by Shirin et al. underscores that specific FH variants may predispose individuals to an increased risk of PCC/PGLs, challenging the conventional HLRCC paradigm [17].

In our patient's case, a FH missense mutation involving c.934T>C (p.Phe312Leu) (dbSNP: rs863224000) results in a single nucleotide polymorphism, replacing Phenylalanine with Leucine at codon 312 of the FH gene. Although not present in population databases, this mutation is expected to disrupt FH protein function, thus carrying clinical significance for pathogenic conditions such as HLRCC, PCC, and PGLs. The pathogenesis of PCC/PGLs associated with VHL, NF-1, SDH, FH, and ICH mutations involves the regulation of hypoxia-inducible factor-alpha (HIF-α), activation of the RAS/RAF/MAPK kinase pathway, and modulation of innate

immune tolerance. The regulation of HIF genes serves as the cornerstone for cellular differentiation and angiogenesis under conditions of low oxygen levels attributed to mitochondrial enzyme defects. Discovered in 1995, the role of HIF-1 in tumorigenesis and angiogenesis has since become apparent. Instances of hypoxia or oxygen deprivation impede HIF-α degradation, facilitating HIF-α nuclear translocation and heterodimerization. The process requires tight control of prolyl hydroxylase domain (PHD) proteins, which also serve as HIF hydroxylase enzymes for ubiquitination and proteasomal degradation of HIF-α [10], [13], [18]. Failure of HIF-α degradation and its subsequent upregulation are responsible for suppressing T cell function through the activation of iNOS and arginase. This immune modulation prompts innate immune response tolerance, and the release of chemokines fosters angiogenesis, immune evasion, tumor progression, and maintenance of the tumor microenvironment [19]–[22]. Remarkably, studies have correlated high-altitude living and co-morbidities such as cyanotic congenital heart disease and chronic obstructive lung disease with paraganglioma occurrence [23]. Management of PCC/PGLs involves initial biochemical testing for tumor secretory function, imaging studies to detect localizing and metastatic disease, and symptom-associated treatments such as hypertension management, biopsy, and genetic counseling [24]. Given the tumor microenvironmental alterations, all PCC/PGL patients should undergo genetic work-ups and counseling to identify germline or sporadic genetic mutations fueling tumorigenesis [11, 25].

Biochemical testing entails measuring plasma free metanephrines and urinary fractionated metanephrines levels. Imaging studies encompass MIBG scans, 18F-fludeoxyglucose (FDG) or gallium Ga-68 DOTATATE PET/CT scans. Pre-operative alpha-1 adrenergic receptor blockade is recommended for patients with resectable tumors to manage blood pressure. Surgical options include laparoscopic adrenalectomy or open resection for tumors larger than 6 cm for pheochromocytomas, and open/laparoscopic resection for paragangliomas [26]. Patients with localized unresectable or metastatic disease may continue alpha blockade, and asymptomatic patients should be observed. Somatostatin analogs like Octreotide or Lanreotide are suitable for managing secretory tumors. Systemic chemotherapy with CVD (Cyclophosphamide, Vincristine, Dacarbazine)/Temozolamide or oral anti-VEGF tyrosine kinase inhibitors (Sunitinib, Lenvatinib, Pazopanib) can be considered for progressive disease [11], [27-30]. If metastasis emerges during treatment, options include high-specific-activity (HSA) iobenguane I-131 or other iodine-131-MIBG therapy (if MIBG scan positive), PRRT with 177Lu-DOTATATE (if SSTR positive), or palliative radiation therapy (for bone metastases) [31-33]. Targeting HIF also holds promise for improved outcomes, with Belzutifan currently in phase 2 trials for PCC/PGLs showing favorable results [34].

5. Conclusion

In conclusion, our case presents a unique occurrence of metastatic paraganglioma, surfacing three years after the initial diagnosis of localized pheochromocytoma and subsequent resection. This exceptional case is further distinguished by its association with a rare missense mutation in the FH gene. Metastatic cases of PCC/PGLs are infrequent and may be linked to genetic mutations in approximately one-third of instances. While FH missense mutations are known culprits in hereditary PCC/PGLs and HLRCC, the specific variant observed in this case is less common compared to more prevalent genetic abnormalities such as those affecting the SDH, VHL, NF1, and MEN1 genes.

References

1. Withey SJ. Imaging Features of Succinate Dehydrogenase–deficient Pheochromocytoma-Paraganglioma Syndromes," RadioGraphics. 2019; 39(5): 1393–1410.
2. Berends AMA. Incidence of pheochromocytoma and sympathetic paraganglioma in the Netherlands: A nationwide study and systematic review. Eur. J. Intern. Med. 2018; 51: 68–73.
3. Beard CM, Sheps SG, Kurland LT, Carney JA, Lie JT. Occurrence of pheochromocytoma in Rochester, Minnesota, 1950 through 1979," Mayo Clin. Proc. 1983; 58(12): 802–804.
4. Zelinka T. Metastatic pheochromocytoma: clinical, genetic, and histopathologic characteristics. Eur. J. Clin. Invest. 2011; 41(10): 1121–1128.
5. Kimura N, Watanabe T, Noshiro T, Shizawa S, Miura Y. Histological grading of adrenal and extra-adrenal pheochromocytomas and relationship to prognosis: a clinicopathological analysis of 116 adrenal pheochromocytomas and 30 extra-adrenal sympathetic paragangliomas including 38 malignant tumors. Endocr. Pathol. 2005; 16(1): 23–32.
6. Linnoila RI, Keiser HR, Steinberg SM, Lack EE. Histopathology of benign versus malignant sympathoadrenal paragangliomas: clinicopathologic study of 120 cases including unusual histologic features. Hum. Pathol. 1990; 21(11): 1168–1180.
7. Size of the tumor and pheochromocytoma of the adrenal gland scaled score (PASS): can they predict malignancy? - PubMed.
8. Wu D. Observer variation in the application of the Pheochromocytoma of the Adrenal Gland Scaled Score. Am. J. Surg. Pathol. 2009; 33(4): 599–608.
9. Neumann HP. 65 Years of The Double Helix: Genetics informs precision practice in the diagnosis and management of pheochromocytoma. Endocr. Relat. Cancer. 2018; 25(8): T201–T219.
10. Welander J, Söderkvist P, Gimm O. Genetics and clinical characteristics of hereditary pheochromocytomas and paragangliomas," Endocr. Relat. Cancer. 2011; 18(6): R253–R276.
11. Else T, Greenberg S, Fishbein L. Hereditary Paraganglioma-Pheochromocytoma Syndromes, in GeneReviews®, M. P. Adam, G. M.

Mirzaa, R. A. Pagon, S. E. Wallace, L. J. Bean, K. W. Gripp, and A. Amemiya, Eds., Seattle (WA): University of Washington, Seattle, 1993.

12. King A, Selak MA, Gottlieb E. Succinate dehydrogenase and fumarate hydratase: linking mitochondrial dysfunction and cancer. Oncogene. 2006; 25(34).
13. Bardella C, Pollard PJ, Tomlinson I. SDH mutations in cancer," Biochim. Biophys. Acta BBA - Bioenerg. 1807; 11: 1432–1443.
14. Gupta S. Incidence of succinate dehydrogenase and fumarate hydratase-deficient renal cell carcinoma based on immunohistochemical screening with SDHA/SDHB and FH/2SC. Hum. Pathol. 2019; 91: 114–122.
15. Picaud S. Structural basis of fumarate hydratase deficiency. J. Inherit. Metab. Dis. 2011; 34(3): 671–676.
16. List of variants in gene FH reported as likely pathogenic - ClinVar Miner."
17. Zavoshi S. Fumarate Hydratase Variants and Their Association with Paraganglioma/Pheochromocytoma. Urology. 2023; 176: 106–114.
18. Fong GH, Takeda K. Role and regulation of prolyl hydroxylase domain proteins. Cell Death Differ. 2008; 15(4).
19. Facciabene A. Tumour hypoxia promotes tolerance and angiogenesis via CCL28 and T(reg) cells. Nature. 2011; 475(7355): 226–230.
20. Corzo CA. HIF-1α regulates function and differentiation of myeloid-derived suppressor cells in the tumor microenvironment. J. Exp. Med. 2010; 207(11): 2439–2453.
21. Doedens AL. Macrophage Expression of HIF-1α Suppresses T cell Function and Promotes Tumor Progression. Cancer Res. 2010; 70(19): 7465–7475.
22. Huang Y, Lin D, Taniguchi CM. Hypoxia inducible factor (HIF) in the tumor microenvironment: friend or foe?. Sci. China Life Sci. 2017; 60(10): 1114–1124.
23. Rodríguez-Cuevas S, López-Garza J, Labastida-Almendaro S. Carotid body tumors in inhabitants of altitudes higher than 2000 meters above sea level. Head Neck. 1998; 205: 374–378.
24. Lenders JWM. Pheochromocytoma and paraganglioma: an endocrine society clinical practice guideline. J. Clin. Endocrinol. Metab. 2014; 99(6): 1915–1942.
25. Fishbein L, Merrill S, Fraker DL, Cohen DL, Nathanson KL. Inherited mutations in pheochromocytoma and paraganglioma: why all patients should be offered genetic testing," Ann. Surg. Oncol. 2013; 20(5): 1444–1450.
26. Conzo G. Laparoscopic adrenalectomy, a safe procedure for pheochromocytoma. A retrospective review of clinical series. Int. J. Surg. Lond. Engl. 2013; 11(2): 152–156.
27. Tanabe A, Naruse M, Nomura K, Tsuiki M, Tsumagari A, Ichihara A, et al. Combination chemotherapy with cyclophosphamide, vincristine, and dacarbazine in patients with malignant pheochromocytoma and paraganglioma," Horm. Cancer. 2013; 4(2): 103–110.
28. Ayala-Ramirez M. Treatment with Sunitinib for Patients with Progressive Metastatic Pheochromocytomas and Sympathetic Paragangliomas," J. Clin. Endocrinol. Metab. 2012; 97(11): 4040–4050.
29. Jasim S, Chintakuntlawar A, Bible KC. Durable response to lenvatinib in progressive, therapy-refractory, metastatic paraganglioma. Int. J. Endocr. Oncol. 2016; 3(4): 285–289.
30. Patel S. Favorable and Durable Response to Pazopanib in Metastatic Refractory Paraganglioma. J. Oncol. Pract. 2017; 13(12): 840–842.
31. Pryma D. Azedra (iobenguane I 131) in patients with malignant, recurrent and/or unresectable pheochromocytoma or paraganglioma (PPGL): Updated efficacy and safety results from a multi-center, open-label, pivotal phase 2 study. J. Clin. Oncol. 2018; 36(15_suppl): 4005–4005.
32. Satapathy S, Mittal BR, Bhansali A. Peptide receptor radionuclide therapy in the management of advanced pheochromocytoma and paraganglioma: A systematic review and meta-analysis. Clin. Endocrinol. (Oxf.). 2019; 91(6): 718–727.
33. Van Essen M. Effects of therapy with [177Lu-DOTA0, Tyr3] octreotate in patients with paraganglioma, meningioma, small cell lung carcinoma, and melanoma. J. Nucl. Med. Off. Publ. Soc. Nucl. Med. 2006; 47(10): 1599–1606.
34. Fallah J. FDA Approval Summary: Belzutifan for von Hippel-Lindau Disease–Associated Tumors," Clin. Cancer Res. 2022; 28(22): 4843–4848.