

Ramsay Hunt Syndrome with Chickenpox: A Case Report in Elder Woman

Ma MX, Zhang XH, Li YQ, Wu SQ, Lang N*, Jian-Xun Ren*

Xiyuan Hospital of China Academy of Chinese Medical Sciences, China

*Corresponding author:

Na Lang,
Department of Dermatology, Xiyuan Hospital of China
Academy of Chinese Medical Sciences, BeiJing,
China, Tel: +86-628352089;
E-mail: langna96@126.com
Jian-Xun Ren,
Experimental center, Xiyuan Hospital of China
Academy of Chinese Medical Sciences, BeiJing,
China, Tel: +86-62835608; E-mail: rjx131@sina.com

Received: 05 Oct 2022
Accepted: 17 Oct 2022
Published: 21 Oct 2022
J Short Name: ACMCR

Copyright:

©2022 Lang N, Jian-Xun Ren. This is an open access article distributed under the terms of the Creative Commons Attribution License, which permits unrestricted use, distribution, and build upon your work non-commercially

Citation:

Jian-Xun Ren, Ramsay Hunt Syndrome with Chickenpox: A Case Report in Elder Woman. *Ann Clin Med Case Rep.* 2022; V10(3): 1-4

Keywords:

Ramsay Hunt syndrome; Herpes zoster; Varicella; Chickenpox

1. Abstract

Ramsay Hunt syndrome (RHS) is an infectious disease characterized by delayed activation of latent herpes zoster virus in the geniculate ganglion and subsequent spread to cranial nerve. Although herpesvirus can also cause chickenpox and herpes zoster, the delayed chickenpox is a rare presentation of RHS. We present the case of a 76-year-old female patient with Alzheimer's disease appeared unstable gait for 2 days. The patient had left facial palsy with concomitant skin lesions in the left external auditory canal. After exclusion of ischemic cerebrovascular diseases, the patient was diagnosed with RHS by typical symptoms. Subsequently, the typical chickenpox broke out on the right auricle during hospitalization. After antiviral and hormone therapy, the patient's RHS-associated symptoms were relieved. Early diagnosis of RHS, and the use of acyclovir-corticosteroid to relieve inflammation and injury of nerves can bring a crucial effect on prognosis of cranial nerve damage.

2. Introduction

Ramsay Hunt syndrome (RHS) is a complication of varicella-zoster virus infection with involvement of the seventh and eighth cranial nerves. The clinical symptoms are characterized by acute facial palsy and vestibulocochlear injury with a herpes eruption on the external auricular [1]. RHS was first described by J. Ramsay Hunt in 1907. RHS is a special form of herpes zoster caused by reactivation and replication of varicella zoster virus (VZV) in the

geniculate ganglion of the facial nerve, and less than 1% of zoster cases involve the facial nerve result as RHS [2]. VZV belongs to human herpes viruses α subfamily, which are double-stranded DNA viruses that transmissible via respiratory droplets. After primary varicella infection, the VZV persists in the spinal and cranial nerve ganglia over lifetime, and the overwhelming majority of infected individuals have no symptoms. Reactivation of latent VZV is triggered at a later stage in a state of compromised immune to present as herpes zoster. Although RHS is frequent in adults and increases with age due to primary exposure to the virus in childhood, the disease is rare in older individuals.

After reactivation and replication, the viruses travel through the sensory fibers of facial nerve into the dermatome associated with the involved ganglion around the auricular and external auditory meatus, which induces the typical clinical characteristics of pain and rash in herpetiform distribution. Beyond the dermatological manifestations, reactivated VZV also stimulate the adjacent motor branches of the facial nerve, which leads to facial muscle paresis and balance disorders, as well as lacrimal and nasal secretion. Some people infected with VZV can cause chickenpox at the time of viruses first attack, however, VZV reactivation can produce a variety of chronically neurological damage with or without rash on the ear or in the mouth, and rarely, with chickenpox. The diagnosis is mainly based on the typical clinical manifestations. The appropriate corticosteroids and antiviral therapy resulted in a

good prognosis. But there is lack of data on long-term outcomes. Here, we report the case of an elder patient suffered from RHS with chickenpox, which shows the early diagnostic challenges of this syndrome.

The early diagnosis of Ramsay Hunt syndrome is essential, as prognosis of cranial nerve damage depends on the time at which corticosteroid-based therapy is started.

3. Case Report

A 76-year-old female patient had exhibited unsteady gait for 2 days with left-sided facial weakness. She reported no vertigo, tinnitus, nausea, and vomiting. One week ago, before she presented to our hospital, she was found rash appeared on her left ear. The patient had suffered from Alzheimer's disease for more than 5 years and prescribed memantine hydrochloride tablets (10 mg QD) and donepezil hydrochloride tablets (10 mg QN) for the past year. She had no history of underlying diseases. To further confirm whether the cerebral disease existed, she took Cranial CT and MRI which revealed no obvious abnormalities.

Physical examination revealed a drunken gait and facial paralysis of the left side was found. The facial voluntary movement was evaluated with the House-Brackmann grading system, and the peripheral facial paralysis was belonged to be House-Brackmann grade III. There are many purulent secretions in the left ear (Figure 1), however, no rash was observed on the right ear, trunk, and limbs. The patient had hearing loss and was unable to cooperate with pure tone audiometry. We also found that the left forehead wrinkles disappeared, the left nasolabial groove became shallow in this patient (Figure 2).

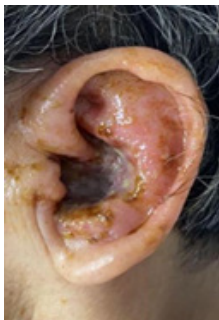

Figure 1: Left ear of the patient: white pus with paste of Chinese medicine (yellow part).

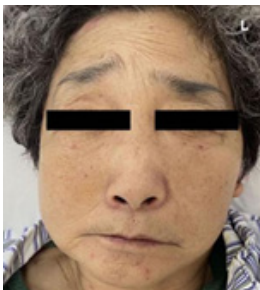

Figure 2: The patient's left facial muscle was weak and appeared flaccid.

Based on the clinical signs and symptoms that mainly manifest she was diagnosed the RHS. Antiviral therapy with famciclovir tablets and prednisone acetate tablets was begun at a dosage of 0.75 g/d and 10 mg/d, respectively.

During admission, new herpes focus appeared on the patient's trunk. On examination, red herpes, as a typical chickenpox were seen in the skin of the chest and back. The herpes blisters were the size of soybeans with uniform shape, and there was no halo around them. The blister wall was thin, and the blister fluid was clear. The herpes itched, some of them were scratched up and ulcerated (Figure 3).

After 3 days of treatment, the patient was able to walk normally and there was still some new chickenpox left on the trunk. Since her main complaint was resolved, she was discharged from hospital, and advised to maintain the current treatment and to be vigilant about protection in others.

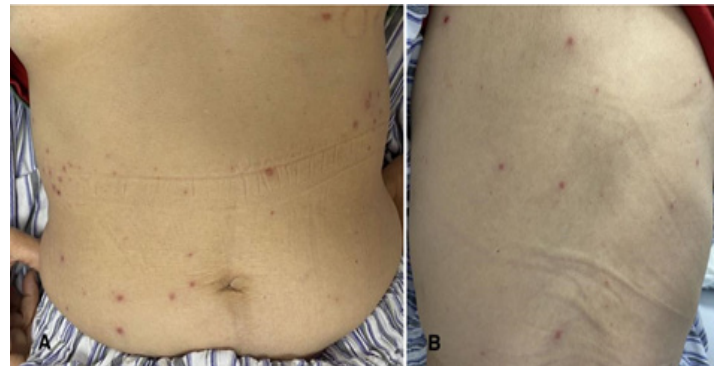


Figure 3: The patient's trunk was covered with small blisters, and some of the blisters had been broken.

4. Discussion

Acute facial paralysis in elder can be caused by a range of disorders, including ischemic cerebrovascular diseases, trauma, infection, metabolic and neoplastic factors. In elderly patients with sudden gait unsteadiness and facial paralysis, acute cerebral infarction is more prone to be considered and the possibility of RHS could be ignored. RHS usually is diagnosed on a clinical basis, as laboratory testing is often slow or impractical. In definition, RHS is characterized by combination of acute facial nerve palsy and vesicular eruption of the skin of pinna and external auditory canal caused by VZV. VZV is present worldwide and 98% of the adult population in the United States is seropositive for VZV [3]. Two clinical studies demonstrated that RHS was the cause of facial palsy in 16.7% of children, and 18.1% of adult [4-5], respectively. The prevalence of facial paralysis induced by VZV reactivation in adult was significantly higher than children, which reflect an underlying immunocompromised status with advanced age. Multiple cranial nerve ganglia, including geniculate ganglion and peripheral ganglia of cranial nerves VIII, IX and X involvement frequently occurred in RHS [6]. Pathophysiological characteristics of multiple cranial nerve involvement associated with RHS still remains

unclear. Hunt et al suggested that adjacent gasserian, petrous, accessory, jugular, plexiform, the second, and the third cervical dorsal root ganglia may form chain allowing the extension of the ganglionitis [7]. The perineural spread of the reactivated VZV can travel through the small branches of the infected carotid artery, middle meningeal artery, and ascending pharyngeal artery that supply blood to cranial nerves V, VII, IX, X, XI and XII cranial nerves. In this patient, VZV had gradual progressive involvement of lower cranial nerves VII, VIII, IX and X associated with herpetic eruptions on the outer aspect of the ear. Thus, the combination dysfunction of motor and sensory involvement leads to motor weakness, muscular spasm or in the form of concomitant motor movements. Clinical symptoms presented in this case as balance dysfunction, which is typical symptoms in RHS and blame to the cochlear nerve lesions [8]. The geniculate ganglion sits between the cochlea and the tympanic cavity, there are many reasons to explain how VZV infect the cochlear nerve [9].

Firstly, the vestibular nerve and can be transmitted directly through neurons, previously studies have confirmed that VZV can be transmitted through axons [10]. Besides, VZV can be transmitted through the blood, Topographically, the geniculate ganglion is nearby cochlear nerve and origin from the posterior circulation so that VZV can travel from the geniculate ganglion to the cochlear nerve. Another important point is that VZV was also found in the spirochetes and vestibular ganglion of some individuals without clinical manifestations in early studies [11], which means virus could latent directly in the vestibular ganglion.

Up to now, the strict definition of the RHS is peripheral facial nerve palsy accompanied by an erythematous vesicular rash on the ear (zoster oticus). But Some patients develop peripheral facial paralysis without rash which is really difficult to distinguish clinically from Bell palsy. Murakami et al. identified RHS zoster sine herpete in six (19%) of the patients in a study of 32 patients with isolated peripheral facial palsy [12].

RHS has an incidence of about 5 per 100,000 people per year [13], while RHS combined with chickenpox is quite rare for most herpes patients. During an episode of zoster, vesicular rashes tend to appear within a single dermatome [14]. In this case, the patient varicella spread over trunk, displayed VZV infected multiple spinal ganglia.

VZV infection causes primary varicella (chickenpox). Varicella-zoster virus is highly contagious and is transmitted through airborne droplets or direct contact with vesicular fluid. After primary chickenpox, chickenpox is usually seen in susceptible unvaccinated individuals, but can also present in individuals who had been previously vaccinated [15]. Therefore, the susceptible immunocompromise is a key factor in RHS with chickenpox. Although VZV as a DNA virus is more conservative than RNA virus, many mutations of VZV have still found [16]. The gene fragment encoding glycoprotein E could have a base mutation at a single site,

which resulted to amino acid changes. After mutation, the infectivity of VZV may change, and the infected strain of this patient may be mutated [17]. Acyclovir is the first-line treatment option for RHS to prevent disease progression regardless of immune status or disease severity.

5. Conclusion

This case demonstrates an elder RHS patient which means VZV had infected and reactivated, it is possible that chickenpox presentation is now so uncommon in clinical practice that it is more difficult to identify. Complications of chickenpox can present in immunodeficient individuals, or in healthy adults. Advanced age can be an important factor to chickenpox, especially in high-risk individuals. Early recognition of RHS with chickenpox is also important to prevent transmission to others, especially to those at increased risk of complications, including susceptible adults, and susceptible immunocompromised individuals.

References

1. Khan YMT, Fatema N. Ramsay Hunt syndrome. *Pan Afr Med J*. 2019; 34: 201.
2. Sommer T, Karsy M, Driscoll MJ, et al. Varicella-Zoster Virus Infection and Osteomyelitis of the Skull. *World Neurosurg*. 2018; 115: 297-300.
3. Schmid DS, Jumaan AO. Impact of varicella vaccine on varicella-zoster virus dynamics. *Clin Microbiol Rev*. 2010; 23(1): 202-17.
4. Yeo SW, Lee DH, Jun BC, et al. Analysis of prognostic factors in Bell's palsy and Ramsay Hunt syndrome. *Auris Nasus Larynx*. 2007; 34(2): 159-64.
5. Hato N, Kisaki H, Honda N, Gyo K, et al. Ramsay Hunt syndrome in children. *Ann Neurol*. 2000; 48(2): 254-6.
6. Nonnekes J, Růžička E, Serranová T, et al. Functional gait disorders: A sign-based approach. *Neurology*. 2020; 94(24): 1093-1099.
7. Kuhweide R, Van de Steene V, Vlaminck S, et al. Ramsay Hunt syndrome: pathophysiology of cochleovestibular symptoms. *J Laryngol Otol*. 2002; 116(10): 844-8.
8. Tsau PW, Liao MF, Hsu JL, et al. Clinical Presentations and Outcome Studies of Cranial Nerve Involvement in Herpes Zoster Infection: A Retrospective Single-Center Analysis. *J Clin Med*. 2020; 9(4): 946.
9. de Castro DC, Marrone LC. *Neuroanatomy, Geniculate Ganglion*. 2021.
10. Mayberg M, Langer RS, Zervas NT, et al. Perivascular meningeal projections from cat trigeminal ganglia: possible pathway for vascular headaches in man[J]. *Science*. 1981; 213: 228-230.
11. Furuta Y, Takasu T, Suzuki S, et al. Detection of latent varicella-zoster virus infection in human vestibular and spiral ganglia. *J Med Virol*. 1997; 51: 214-16.
12. Murakami S, Honda N, Mizobuchi M, et al. Rapid diagnosis of varicella zoster virus infection in acute facial palsy, *Neurology*. 1998; 51(4): 1202-1205.
13. Crouch AE, Hohman MH, Andaloro C. Ramsay Hunt Syndrome.

- 2022 May 1. In: StatPearls [Internet]. Treasure Island (FL): StatPearls. 2022.
14. Crouch AE, Hohman MH, Andaloro C. Ramsay Hunt Syndrome. 2022.
 15. Andrei G, Snoeck R. Advances and Perspectives in the Management of Varicella-Zoster Virus Infections. *Molecules*. 2021; 26(4): 1132.
 16. Kennedy PGE, Mogensen TH, Cohrs RJ. Recent Issues in Varicella-Zoster Virus Latency. *Viruses*. 2021; 13(10): 2018.
 17. Harbecke R, Cohen JI, Oxman MN. Herpes Zoster Vaccines. *J Infect Dis*. 2021; 224(12 Suppl 2): S429-S442.