

## Successful Treatment of *Acinetobacter Baumannii* Infection in Burn Child with Avibactam/Sulbactam: A Case Report

Ghunaim AH<sup>1,2\*</sup>, Alghamdi AM<sup>1,2</sup>, Alghamdi EM<sup>2,3</sup> and Aldabbagh M<sup>1,2,4</sup>

<sup>1</sup>Department of Pediatrics, King Abdulaziz Medical City, Jeddah, Saudi Arabia

<sup>2</sup>King Abdullah International Medical Research Centre, Jeddah, Saudi Arabia

<sup>3</sup>Department of Emergency Medicine, King Abdulaziz Medical City, Jeddah, Saudi Arabia

<sup>4</sup>King Saud bin Abdulaziz University for Health Sciences, Jeddah, 21556, Saudi Arabia

### \*Corresponding author:

Afaf Hasan Ghunaim,  
Department of Pediatrics, King Abdullah International  
Medical Research Centre, King Abdulaziz Medical  
City, Jeddah, Saudi Arabia,  
E-mail: afaf.ghuniam@gmail.com

Received: 07 Jun 2022

Accepted: 16 Jun 2022

Published: 22 Jun 2022

J Short Name: ACMCR

### Copyright:

©2022 Ghunaim AH. This is an open access article distributed under the terms of the Creative Commons Attribution License, which permits unrestricted use, distribution, and build upon your work non-commercially.

### Citation:

Ghunaim AH, Successful Treatment of *Acinetobacter Baumannii* Infection in Burn Child with Avibactam/Sulbactam: A Case Report. *Ann Clin Med Case Rep.* 2022; V9(8): 1-4

### Keywords:

Multi-drug resistant; Nosocomial infection;  
*Acinetobacter baumannii*; Case report;  
Avibactam/sulbactam

## 1. Abstract

Infection with multi-drug resistant bacteria is an uprising clinical problem that requires the development of new antimicrobial agents. Sulbactam/avibactam increases sulbactam activity against multi-drug resistant *Acinetobacter baumannii* in vitro; however, it has not been tested clinically yet. Moreover, data about its use in children is limited. A 29-month-old boy was referred with a 40% burn. The patient was on colistin and tigecycline for *A. baumannii* wound infection. Meropenem was added for *Serratia marcescens* septicemia. However, repeated tissue culture revealed MDR *A. baumannii*, which was only sensitive to trimethoprim-sulfamethoxazole (bactrim). The patient had meropenem infusion in addition to Bactrim for three weeks. Unfortunately, the meropenem and bactrim were halted because of treatment failure. Treatment was changed to ceftazidime/avibactam and aztreonam. The patient deteriorated clinically after two days of this regimen; therefore, colistin was added empirically. After one week of persistent fever and elevated inflammatory markers, ceftazidime/avibactam and ampicillin/sulbactam were started. The fever subsided in 48 hours, and the inflammatory markers trended down with laboratory evidence of organism clearance after two weeks. This case showed that avibactam/sulbactam could be an option for managing MDR *A. baumannii* nosocomial infection in children.

## 2. Introduction

Nosocomial infection with antimicrobial-resistant *Acinetobacter*

*baumannii* (*A. baumannii*) is an increasingly recognized problem [1]. The European and United States Centers for Disease Control and Prevention (ECDC and CDC) classified *A. baumannii* resistance into three classes; multidrug-resistance (MDR), extensive drug resistance (XDR), and Pan Drug-Resistant (PDR) [2]. Nosocomial infections caused by *A. baumannii* are present in 13.6% of the culture-positive nosocomial infection, and 20.9% are due to Carbapenem-Resistant *A. Baumannii* (CRAB) [3]. According to the CDC, CRAB healthcare-associated infections are considered the highest resistance pathogens, with an estimated prevalence of 8500 cases per year [4]. Treatment of MDR acinetobacter is challenging, and there is no standard of care antibiotic regimen to compare the results of other regimens to it [5]. The World Health Organization (WHO) recognized *A. baumannii* resistance strains as a critical issue in healthcare and needs new antibiotics urgently [6]. The main treatment agents are carbapenems (particularly meropenem), administered alone or with amikacin. The principal alternatives are ampicillin/sulbactam, tigecycline, and colistin, especially in CRAB infection [5]. Furthermore, managing such severe infections in children is complex and rarely documented in the literature. The combination of sulbactam/avibactam increases sulbactam activity against CRAB in vitro studies [7]. However, the combination has not been tested clinically yet. We present a case of a child infected with a multi-drug-resistant *A. baumannii* and successfully treated with sulbactam/avibactam combination therapy.

### 3. Case Presentation

A 29-month-old male child was referred to our institution with 40% burn involving the lower limb and abdomen. One month before referral, the patient had multiple debridement procedures and auto skin grafting; however, skin grafting was not successful. The wound grew *A. baumannii* and was treated with colistin, tigecycline, and fluconazole.

The patient presented mechanically ventilated with septic shock and disseminated intravascular coagulopathy. The patient was started empirically on meropenem and vancomycin, plus colistin, tigecycline, and fluconazole. Blood, respiratory, and tissue cultures revealed *Serratia marcescens*, which was pan sensitive, and we continued the same management regimen.

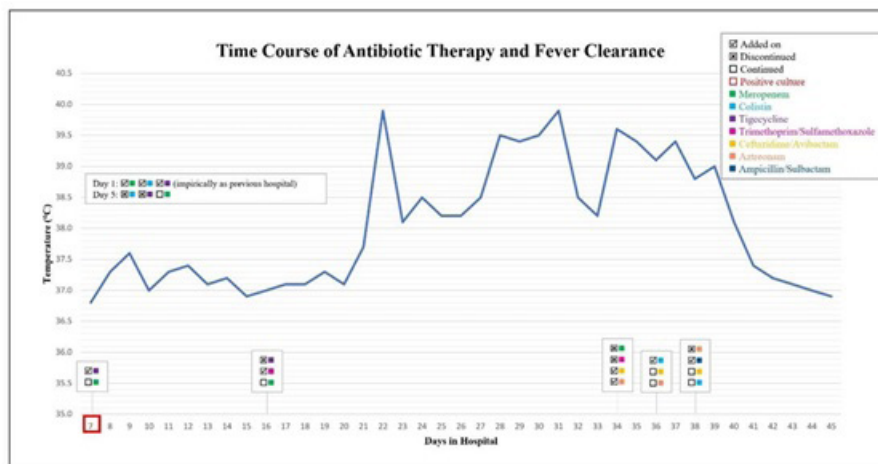
The patient underwent wound irrigation and debridement in the operating room. Colistin and tigecycline were stopped after completing the course. Afterward, the patient was treated for *Serratia* septicemia with meropenem for 14 days. The patient had respiratory symptoms and infiltration in chest X-ray. Respiratory culture revealed MDR *A. baumannii*, which was only sensitive to trimethoprim-sulfamethoxazole, with intermediate sensitivity to tigecycline. The isolate was resistant to other antibiotics, includ-

ing ampicillin/sulbactam, carbapenem, piperacillin/tazobactam, ceftazidime/avibactam, and fluoroquinolones. Therefore, the pediatric Infectious disease team prescribed tigecycline, meropenem prolonged infusion, vancomycin, and bactrim. The patient continued tigecycline for ten days and meropenem infusion with bactrim for three weeks. However, the meropenem and bactrim were halted because of treatment failure.

The multi-disciplinary team decided to start the patient on ceftazidime/avibactam and aztreonam, and suspected gene resistance was sent for analysis. The patient deteriorated clinically after two days of this regimen; therefore, colistin was added empirically. After one week of treatment, the patient remained clinically sick, with a high fever and increasing inflammatory markers. The tested CRAB NDM, IPM and OXA48 genes came back negative.

The pediatric Infectious disease team decided to start ceftazidime/avibactam and ampicillin/sulbactam based on a report of a successful in vitro study [7]. Surprisingly, the fever subsided in 48 hours, and the inflammatory markers trended down with laboratory evidence of organism clearance after two weeks (Figure 1).

The patient received the treatment regimen for three weeks with complete resolution of infection and no sequelae. He was discharged home in good condition after completion of the treatment.



**Figure 1:** The course of antibiotic therapy and fever

### 4. Discussion

Nosocomial infection with MDR *A. baumannii* is associated with high mortality, up to 40% [8]. We reported a single case of a burn patient who had wound and respiratory infections caused by MDR *A. baumannii*. The standard management of *A. baumannii* infections includes broad-spectrum cephalosporins, carbapenems, or a combination of  $\beta$ -lactam/ $\beta$ -lactamase inhibitors [9]. However, there is a need for new treatment options with the emergence of resistant strains. Several studies were conducted to determine if a combination of treatments is superior to monotherapy or might be more effective in treating infections caused by MDR [5]. The majority of the therapeutic options are based on in vitro or observational studies, and a small number of studies evaluated the clinical

efficacy and safety of the treatment regimens [7]. The antimicrobial combination is more favorable to be used over monotherapy to benefit from the synergistic effect [5]. In our case, *A. baumannii* isolate was susceptible to trimethoprim/sulfamethoxazole only and resistant to all other antimicrobial agents.  $\beta$ -lactam antibiotics are preferred to co-administer with  $\beta$ -lactamase inhibitors to inactivate  $\beta$ -lactamase enzymes, which aid in preventing resistance.

Colistin was used for the management of *A. baumannii* infection. Shi and colleagues compare colistin monotherapy versus colistin plus carbapenem to manage CRAB [9]. They found no mortality benefits for the combination therapy, and the effectiveness of treatment was related to the APACHE II score. On the other hand, Aydemir and associates found that colistin combination with ri-

fampicin decreased mortality compared to colistin monotherapy in CRAB infections [10].

Tigecycline monotherapy or combination regimens were reported to treat *A. baumannii* infections. Tigecycline-containing therapy is an alternative therapy for *A. baumannii* infections, particularly in individuals susceptible to colistin-associated nephrotoxicity [11]. However, according to Kengkla and colleagues [12], it possesses a remarkably lower cure rate than other management options. Although tigecycline use in the pediatric population is not commonly recommended by FDA as the clinical efficacy and safety data is limited, Zeng and associates [13] found that tigecycline treatment (1 mg/kg every 12 hours with no loading dose) of an infant with XDR bacteremia was very effective. Moreover, Iosifidis and coworkers [14] reported 13 pediatric cases with lower respiratory or bloodstream infections caused by gram-negative bacteria (8/13 with *A. baumannii*) treated successfully with tigecycline; the dose ranged between 1-3.2 mg/kg with no loading dose. In our case, we could not use tigecycline alone as *A. baumannii* isolate was not sensitive to it. Infectious Disease Society of America guidelines stated that tigecycline could be used as a monotherapy in mild infection and in combination with other antibiotics in moderate and severe infection. Additionally, high dose tigecycline can be considered in moderate and severe infections [15].

Sulbactam is a  $\beta$ -lactamase inhibitor that exhibits an intracellular activity against *A. baumannii* infections. The combination of sulbactam with ampicillin was a useful therapy in treating post neurosurgical meningitis and ventriculitis caused by *A. baumannii*, as sulbactam exhibits the ability to pass through the blood-brain barrier [15]. A recent study conducted by Wareham and associates [16] showed increased in-vitro activity of sulbactam when combined with cefepime against carbapenem-resistant *A. baumannii*, with a significant reduction in minimal inhibitory concentration. A study performed by Assimakopoulos and coworkers [17] showed that a triple therapy of intravenous ampicillin/sulbactam, colistin plus tigecycline, co-administered with aerosol colistin form in patients with ventilator-associated pneumonia caused by carbapenem- and colistin-resistant *A. baumannii* strains was a successful treatment. However, in this study, the mean duration of the therapy was higher (13 days) than the current recommended duration. Another study that compared ampicillin/sulbactam, doripenem, and tigecycline monotherapy and two-drug combinations showed that ampicillin/sulbactam plus tigecycline had a better activity in-vitro than ampicillin/sulbactam alone; however, all the regimens showed microbiological regrowth after 24 hours [18].

The combination of aztreonam/avibactam was used successfully against Metallo- $\beta$ -Lactamase (MBL) producer *Klebsiella pneumoniae* and Enterobacterales. MBL does not affect aztreonam, and avibactam can inactivate other  $\beta$ -lactamase enzymes like OXA-48 and NDM-1 [19]. Nevertheless, it was not active against CRAB infections. In our case, the patient was started on a combination of

ceftazidime/avibactam plus aztreonam after the failure of the previous regimen. However, this combination was ineffective against MDR *A. baumannii*, and aztreonam was discontinued as OXA and NDM were not detected.

A recently published in-vitro study found that a combination of avibactam/sulbactam is an effective therapy for MDR *A. baumannii*. It showed a cutback in minimal inhibitory concentration compared to avibactam or sulbactam alone [7, 20]. A combination of avibactam/sulbactam is usually achieved by administering ceftazidime/avibactam concomitantly with ampicillin/sulbactam. This combination was a successful treatment in our case, where the patient experienced clinical improvement after 48 hours and laboratory eradication after two weeks of administration.

To our knowledge, this is the first case that showed the successful clinical treatment of *A. baumannii* infection in a child with avibactam/sulbactam. A larger clinical trial is recommended to confirm our findings and thoroughly evaluate the therapeutic benefits of avibactam/sulbactam in MDR *A. baumannii* and the associated adverse events.

## 5. Conclusions

Avibactam/sulbactam could be beneficial for managing nosocomial infection caused by MDR *A. baumannii* in children.

## References

1. Ibrahim ME. Prevalence of *Acinetobacter baumannii* in Saudi Arabia: risk factors, antimicrobial resistance patterns and mechanisms of carbapenem resistance. *Ann Clin Microbiol Antimicrob*. 2019; 18(1): 1.
2. Magiorakos A-P, Srinivasan A, Carey RB, Carmeli Y, Falagas ME, Giske CG, et al. Multidrug-resistant, extensively drug-resistant and pandrug-resistant bacteria: an international expert proposal for interim standard definitions for acquired resistance. *Clin Microbiol Infect Off Publ Eur Soc Clin Microbiol Infect Dis*. 2012; 18(3): 268-81.
3. Ayobami O, Willrich N, Harder T, Okeke IN, Eckmanns T, Markwart R. The incidence and prevalence of hospital-acquired (carbapenem-resistant) *Acinetobacter baumannii* in Europe, Eastern Mediterranean and Africa: a systematic review and meta-analysis. *Emerg Microbes Infect*. 2019; 8(1): 1747-59.
4. *Acinetobacter in Healthcare Settings | HAI | CDC* [Internet]. [cited 2022].
5. Tamma PD, Aitken SL, Bonomo RA, Mathers AJ, van Duin D, Clancy CJ. Infectious Diseases Society of America Guidance on the Treatment of AmpC  $\beta$ -lactamase-Producing Enterobacterales, Carbapenem-Resistant *Acinetobacter baumannii*, and *Stenotrophomonas maltophilia* Infections. *Clin Infect Dis an Off Publ Infect Dis Soc Am*. 2021.
6. WHO publishes list of bacteria for which new antibiotics are urgently needed [Internet]. [cited 2022].
7. Pasteran F, Cedano J, Baez M, Albornoz E, Rapoport M, Osteria J, et al. A New Twist: The Combination of Sulbactam/Avibactam En-

- hances Sulbactam Activity against Carbapenem-Resistant *Acinetobacter baumannii* (CRAB) Isolates. *Antibiot (Basel, Switzerland)*. 2021; 10(5).
8. Nasir N, Mahmood SF. Mortality In Patients With Respiratory And Nonrespiratory Carbapenem Resistant-Multidrug Resistant *Acinetobacter* Infections. *J Ayub Med Coll Abbottabad*. 2017; 29(3): 511-3.
  9. Shi H, Lee JS, Park SY, Ko Y, Eom JS. Colistin Plus Carbapenem versus Colistin Monotherapy in the Treatment of Carbapenem-Resistant *Acinetobacter baumannii* Pneumonia. *Infect Drug Resist*. 2019; 12: 3925-34.
  10. Aydemir H, Akduman D, Piskin N, Comert F, Horuz E, Terzi A, et al. Colistin vs. the combination of colistin and rifampicin for the treatment of carbapenem-resistant *Acinetobacter baumannii* ventilator-associated pneumonia. *Epidemiol Infect*. 2013; 141(6): 1214-22.
  11. O'Donnell JN, Putra V, Lodise TP. Treatment of patients with serious infections due to carbapenem-resistant *Acinetobacter baumannii*: How viable are the current options? *Pharmacotherapy*. 2021; 41(9): 762-80.
  12. Kengkla K, Kongpakwattana K, Saokaew S, Apisarntharak A, Chaiyakunapruk N. Comparative efficacy and safety of treatment options for MDR and XDR *Acinetobacter baumannii* infections: a systematic review and network meta-analysis. *J Antimicrob Chemother*. 2018; 73(1): 22-32.
  13. Zeng J, Zhang L, Gao M, Wu J, Wu H, Chen J, et al. Tigecycline treatment in an infant with extensively drug-resistant *Acinetobacter baumannii* bacteremia. *Int J Infect Dis IJID Off Publ Int Soc Infect Dis*. 2017; 61: 23-6.
  14. Iosifidis E, Violaki A, Michalopoulou E, Volakli E, Diamanti E, Koliouskas D, et al. Use of Tigecycline in Pediatric Patients With Infections Predominantly Due to Extensively Drug-Resistant Gram-Negative Bacteria. *J Pediatric Infect Dis Soc*. 2017; 6(2): 123-8.
  15. Demoz GT, Alebachew M, Legesse Y, Ayalneh B. Treatment of ventriculoperitoneal shunt infection and ventriculitis caused by *Acinetobacter baumannii*: a case report. *J Med Case Rep*. 2018; 12(1): 141.
  16. Wareham DW, Momin MHFA, Phee LM, Hornsey M, Standing JF. Cefepime/sulbactam as an enhanced antimicrobial combination therapy for the treatment of MDR Gram-negative infections. *J Antimicrob Chemother*. 2020; 75(1): 135-9.
  17. Assimakopoulos SF, Karamouzos V, Lefkaditi A, Sklavou C, Kolonitsiou F, Christofidou M, et al. Triple combination therapy with high-dose ampicillin/sulbactam, high-dose tigecycline and colistin in the treatment of ventilator-associated pneumonia caused by pan-drug resistant *Acinetobacter baumannii*: a case series study. *Le Infez Med*. 2019; 27(1): 11-6.
  18. Housman ST, Hagihara M, Nicolau DP, Kuti JL. In vitro pharmacodynamics of human-simulated exposures of ampicillin/sulbactam, doripenem and tigecycline alone and in combination against multidrug-resistant *Acinetobacter baumannii*. *J Antimicrob Chemother*. 2013; 68(10): 2296-304.
  19. Karakonstantis S, Kritsotakis EI, Gikas A. Treatment options for *K. pneumoniae*, *P. aeruginosa* and *A. baumannii* co-resistant to carbapenems, aminoglycosides, polymyxins and tigecycline: an approach based on the mechanisms of resistance to carbapenems. *Infection*. 2020; 48(6): 835-51.
  20. Rodriguez CH, Brune A, Nastro M, Vay C, Famiglietti A. In vitro synergistic activity of the sulbactam/avibactam combination against extensively drug-resistant *Acinetobacter baumannii*. *J Med Microbiol*. 2020; 69(7): 928-31.