

Small Cell Carcinoma with Paraneoplastic Cushing's Syndrome in A 23 -Year-Old A New Observation and Literature Review

Feki J¹, Mnif A^{1*}, Saguem MH² and Khanfir A¹

¹Department of Medical Oncology, Habib Bourguiba University Hospita, MedecineFaculty, University of Sfax, Tunisia

²Tunisia Free Practice Pathology Laboratory, Tunisia

*Corresponding author:

Mnif Ahmed,
Department of Medical Oncology, Habib Bourguiba
University Hospita, MedecineFaculty, University of
Sfax, Tunisia, E-mail: dr.mnifahmed@gmail.com

Received: 10 Aug 2021

Accepted: 24 Aug 2021

Published: 31 Aug 2021

Copyright:

©2021 Mnif A. This is an open access article distributed under the terms of the Creative Commons Attribution License, which permits unrestricted use, distribution, and build upon your work non-commercially.

Citation:

Mnif A, Small Cell Carcinoma with Paraneoplastic Cushing's Syndrome in A 23 -Year-Old A New Observation and Literature Review. Ann Clin Med Case Rep. 2021; V7(6): 1-4

Keywords:

Small Cell Lung Cancer; Neuroendocrine Tumor; Pediatric; Lung Cancer; Cortisol; Paraneoplastic; Cushing Syndrome

1. Abstract

A 23 years old girl, without history, consulted for a neck tumefaction appeared 20 days ago, which spread then to the abdomen and lower limbs with Asthenia, dysphagia, abdominal pain, effort dyspnea. Clinical examination revealed an altered general state, obesity with centripetal fat deposition face, supraclavicular and dorsal and cervical fat pads, facial plethora, rounded face, buffalo-hump, face acne, melanodermia, capillary fragility, face, arms and legs hirsutism.

Imaging revealed a voluminous left para-mediastinal Mass. A guided Scan biopsy confirmed the diagnosis of small cell neuroendocrine carcinoma.

The patient had a first line treatment with Etoposide-Carboplatin. Initially the response to the treatment was good with improvement of symptoms. At day 20 of the treatment, the patient had a clinical progression and died after 15 days.

2. Introduction

Adolescent Small Cell Carcinoma is a rare entity. The first case was reported with a 14-year-old boy. It presented 0.2 % of children tumors. These neuroendocrine tumors are associated in 1 to 5% of cases to a paraneoplastic Cushing's syndrome. The second paraneoplastic syndrome in order of frequency is the syndrome of inappropriate secretion of ADH.

Observation

A 23 years old girl, without history, consulted for a neck tumefaction appeared 20 days ago, which spread then to the abdomen and lower limbs with Asthenia, dysphagia, abdominal pain, effort dys-

<http://www.acmcasereport.com/>

pnia. Clinical examination revealed an altered general state, obesity with centripetal fat deposition face, supraclavicular and dorsal and cervical fat pads, facial plethora, rounded face, buffalo-hump, face acne, melanodermia, capillary fragility, face, arms and legs hirsutism (Figure 1-4).

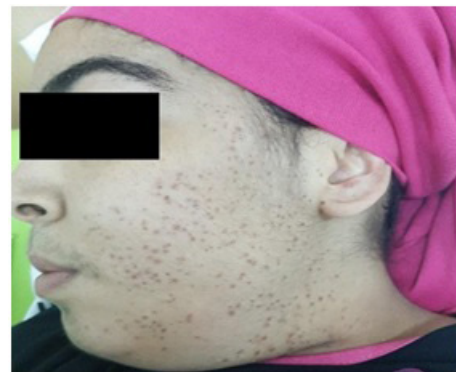

Figure 1: Centripetal fat deposition face, facial plethora, rounded face, buffalo-hump, face acne, Melanodermia

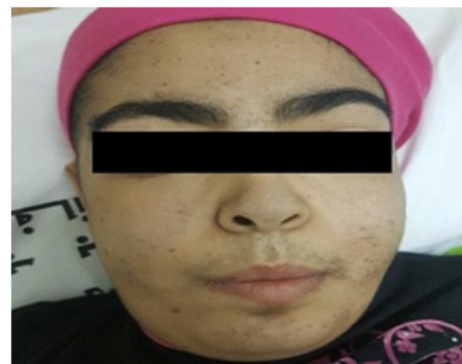

Figure 2: Centripetal fat deposition face, facial plethora, rounded face, buffalo-hump, face acne, Melanodermia

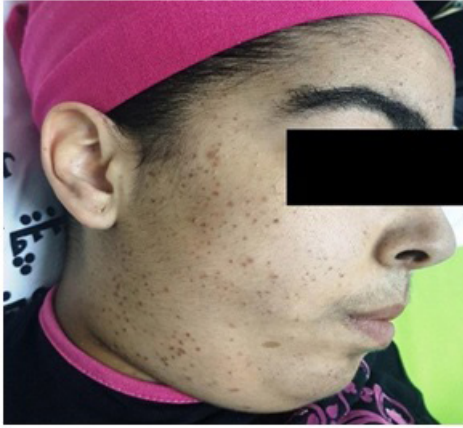

Figure 3: Centripetal fat deposition face, facial plethora, rounded face, buffalo-hump, face acne, melanoderma

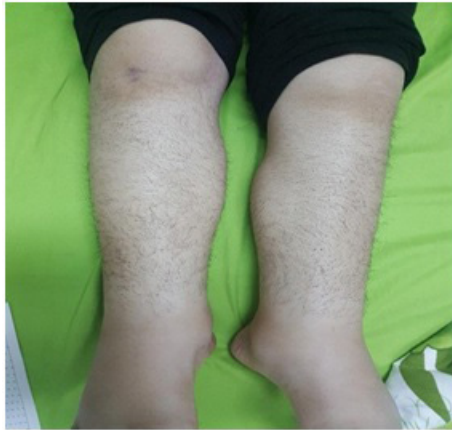

Figure 4: Legs Hirsutism

She had not palpable adenopathy. The abdomen was bloated. She had hepatomegaly with hepatic arrow of 20 centimeter, 2 lower limbs pitting edema. Her blood pressure was 11/9 with oliguria.

Chest radiograph (Figure 5), Cerebral, Thoracic, abdominal and pelvic CT (Figure 6-8) imaging revealed a voluminous left para-mediastinal tumor process, multiple mediastinal lymphadenopathies, many bilateral pulmonary nodules, and hepatomegaly with metastasis.

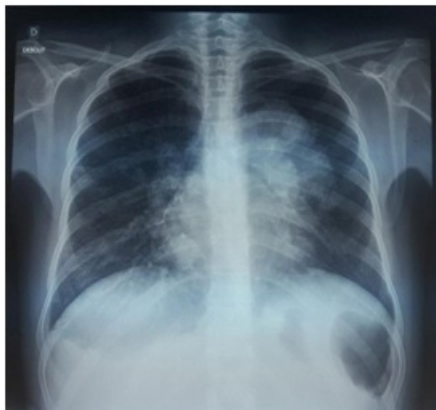

Figure 5: Chest radiograph: left para-mediastinal mass

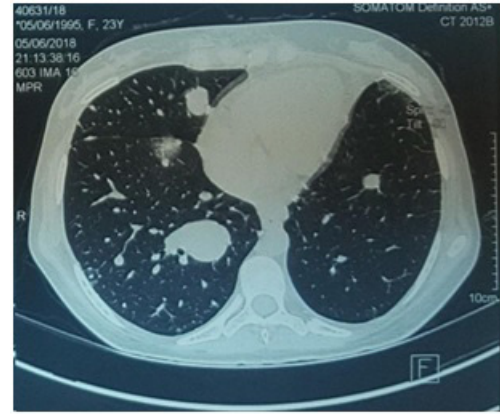

Figure 6: Thoracic CT: left para-mediastinal mass, mediastinal lymphadenopathies, bilateral pulmonary nodules

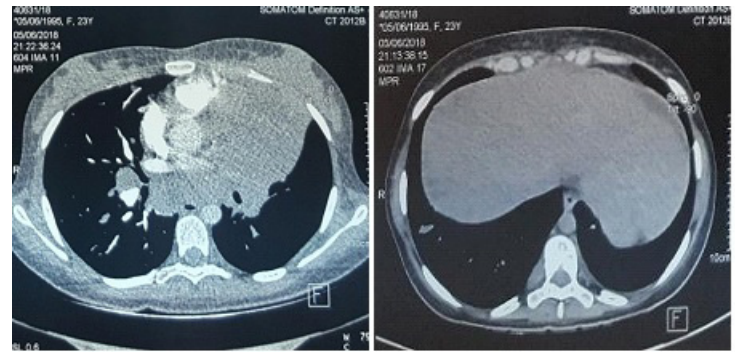


Figure 7: Thoracic CT: left para-mediastinal mass

Figure 8: Abdominal CT: hepatomegaly

A guided Scan biopsy of the mediastinal mass confirmed the diagnosis of a mediastinal localization of small cell neuroendocrine carcinoma confirmed by immunohistochemistry: it shows ovoid small cells undifferentiated carcinoma, with basophilic cytoplasm and dense hyperchromatic nucleus, sometimes downhill with atypia and mitosis (Figure 9). Immunohistochemistry express intense and diffuse manner of chromogranin, synapotphysin and TTF1 (Figure 10).

Laboratory data indicated a disrupted liver status with cytolysis and cholestasis. Plasma protein electrophoresis was normal with negative 24 hours proteinuria. She had hyperglycemia, high cortisol (3 x Normal) and ACTH (6 x Normal). The patient had a first line treatment with Etoposide-Carboplatin. Initially the response to the treatment was good with a slight improvement of the dyspnea, abdominal bloating with a decrease of the edema of the lower limbs. At day 20 of the treatment, the patient had a clinical progression with worsening of the dyspnea, the edema, the abdominal distension and died after 15 days.

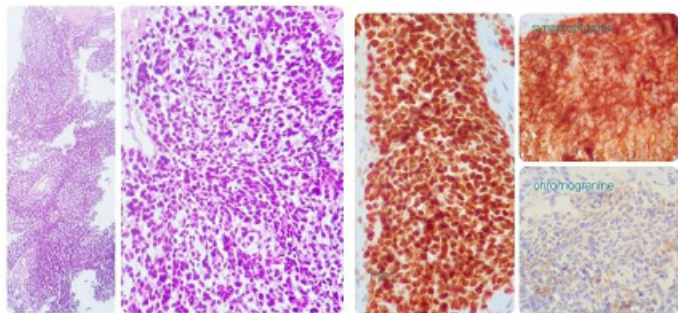


Figure 9: Small undifferentiated cell neuroendocrine diffuse carcinoma: basophilic cytoplasm and dense synaptophysin hyperchromatic nucleus, downhill with atypia and mitosis

Figure 10: Immunohistochemistry: intense and manner of chromogranin and TTF1

3. Discussion

Primary lung cancers are rare in children [1]. It presents 0.16% of all lung cancers occurring in the first decade of life and 0.7% in the second decade [2].

Reported cases of pediatric lung carcinoma in literature are most commonly undifferentiated carcinoma, followed by adenocarcinoma and squamous cell carcinoma.

There was some historical cases of undifferentiated carcinoma truly represent small cell carcinoma or perhaps atypical carcinoid tumors in literature.

In pediatric population, most common benign lung tumor is

inflammatory myofibroblastic tumor (52%), and the most common cancer are carcinoid tumor and pleuropulmonary blastoma [3]. Trachea, bronchus, and lungs cancers represent 0.2% of all children cancers [4]. Eighteen to thirty years old patients with lung cancer have a high incidence of female sex, there is no association with smoking, and favorable prognosis [5].

In 2000, Kim et al published the first case of a 14-year-old boy with Small cell lung cancer. Surveillance Epidemiology and End Results review during twenty one years reported 7 cases of pediatric small cell lung cancer, when Children’s Hospital Boston found 1 case whereas a 90-year review [6-12]. They had the worst prognosis in pediatric lung cancer with median survival less than 5 months. The overall survival was generally poor, and the majority dies with disease recurrence. Two-year survival in patients with extensive stage was 4.6%, and five-year survival of patients with limited stage was 10%. First-line chemotherapy was four to six cycles of Etoposide-Cisplatin. Eighty per cent of limited stage patients and all extensive patients relapse within the first year after initial treatment. In recurrent disease, median survival was 2 to 3 months.

A literature review by PubMed was done by using search terms “small cell lung cancer” and “neuroendocrine carcinoma lung,” and “neuroendocrine tumor lung.” The search was limited to articles describing patients 14 to 18 years old. Six cases were reported (Table 1).

Table 1. Characteristics, Treatment, and Outcome of Small Cell Lung Carcinoma

	Sex	Age	Presenting Symptoms	Smoke Exposure	Stage	Treatment	Outcome
Yonemori et al ⁽¹⁵⁾	F	18	Hemoptysis, fever, and Cough	No	Limited	chemotherapy (ETOPOSIDE and CDDP), pneumonectomy, mediastinal node dissection and radiation	Local recurrence 19 months after.
Tronnes et al ⁻¹⁴	F	14	Left upper quadrant pain, cough, sweats, extremity pain and night, Fever	Unknown	Limited	Chemotherapy (ETOPOSIDE and CARBO) followed by Lobectomy with mediastinal lymph node dissection and radiation	Died of brain metastasis 21 months after diagnosis
Robinet et al ⁽²¹⁾	M	17	Left shoulder Pain	No	Limited	Chemotherapy (DOXO, CPM, ETOP) followed by thoracotomy and radiation	Died 34 months after diagnosis
Post et al ⁽²²⁾	F	16	decreased appetite and weight loss, chest pain, Cough and fatigue,	No	Extensive	Chemotherapy IFOS, CPM, CARBO, VCR, ETOP TOPO) with no response.	Died 6 months
Kim et al ⁽¹¹⁾		14	No symptoms	No	Limited	chemotherapy (CDDP, ETOP) and radiation	Unknown
Barbour M et Al ⁽²³⁾	M	15	chest pain, weight fatigue and dyspnea	No	Extensive	Chemotherapy CDDP and ETOPOSIDE 2 cycles (decrease disease). 8 cycles of GEMCITABINE (decrease disease) then follow up	

CARBO: carboplatin; CDDP: cisplatin; CPM: cyclophosphamide; DOXO: Doxorubicin; ; GMZ: Gemcitabine; IFOS: ifosfamide; TOPO: topotecan; VCR: vincristine.

Median age was 15 years old (range, 14 to 18) and only two patient had a metastatic disease [13]. Five patients had no smoke exposure. Five patients received systemic chemotherapy with platinum-based regimen.

One case of small cell cancer treated with gemcitabine. Only patients with limited stage cancer received radiation therapy [16]. Death is reported in four cases. Outcome is not known for 2 of the

patients with limited stage disease.

Ectopic corticotropin syndrome or Cushing’s syndrome is present in 2–5% of patients with small-cell lung cancer at the time of presentation [17]. In this literature review, no patients had a cushing paraneoplastic syndrome as our case.

Treatment of ectopic corticotropin production need a reduction of cortisol synthesis by an adrenal enzyme inhibitor such as ke-

toconazole [18] as well as treatment of primary tumor. Jeong et al. suggested achieving longer survival may be attended with controlling the high cortisol level by administering systemic chemotherapy [19]. Associated with systemic chemotherapy, ketoconazole (strong inhibitor of cytochrome P450), metyrapone, etomidate, mitotane, and mifepristone can be used to reduce circulating glucocorticoids [15].

4. Conclusion

Small cell cancer, high grade neuroendocrine lung cancer is extremely rare in adolescent population. Few cases were reported in literature, rarer those associated to paraneoplastic syndrome. Patients with an extensive stage tumor have a bad prognosis with 2 year survival less the 5 %.

References

- Dishop MK, Kuruvilla S. Primary and Metastatic Lung Tumors in the Pediatric Population: A Review and 25- Year Experience at a Large Children's Hospital. *Arch Pathol Lab Med.* 2008; 132: 25.
- Fontenelle LJ. Primary adenocarcinoma of lung in a child: review of the literature. *Am Surg.* 1976; 42(4): 296-9.
- Hancock BJ, Di Lorenzo M, Youssef S, Yazbeck S, Marcotte JE, Collin PP. Childhood primary pulmonary neoplasms. *J Pediatr Surg.* 1993; 28(9): 1133-6.
- Tischer W, Reddemann H, Herzog P, Gdanietz K, Witt J, Wurnig P, et al. Experience in surgical treatment of pulmonary and bronchial tumours in childhood. *Prog Pediatr Surg.* 1987; 21: 118-35.
- Neville HL, Hogan AR, Zhuge Y, Perez EA, Cheung MC, Koniaris LG, et al. Incidence and outcomes of malignant pediatric lung neoplasms. *J Surg Res.* 2009; 156: 224-30.
- Dishop MK, Kuruvilla S. Primary and metastatic lung tumors in the pediatric population: a review and 25-year experience at a large children's hospital. *Arch Pathol Lab Med.* 2008; 132: 1079-103.
- Altekruse SF. SEER Stat Fact Sheets: Lung and Bronchus [Surveillance Epidemiology and End Results Web site]. 2011.
- Jackman DM, Johnson BE. Small-cell lung cancer. *Lancet.* 2005; 366: 1385-96.
- Govindan R, Page N, Morgensztern D, Read W, Tierney R, Vlahiotis A, et al. Changing epidemiology of small-cell lung cancer in the United States over the last 30 years: analysis of the surveillance, epidemiologic, and end results database. *J Clin Oncol.* 2006; 24: 4539-44.
- Kim CK, Chung CY, Koh YY. Primary small cell bronchogenic carcinoma in a 14-year-old boy. *Pediatr Pulmonol.* 2000; 29: 317-20.
- Yu DC, Grabowski MJ, Kozakewich HP, et al. Primary lung tumors in children and adolescents: a 90-year experience. *J Pediatr Surg.* 2010; 45: 1090-5.
- Kim CK, Chung CY, Post GR, Lewis JA, Hudspeth MP, et al. Disseminated neuroendocrine carcinoma in a pediatric patient: a rare case and diagnostic challenge. *J Pediatr Hematol Oncol.* 2012; 34: 200-3.
- Koh YY. Primary small cell bronchogenic carcinoma in a 14-year-old boy. *Pediatr Pulmonol.* 2000; 29: 317-20.
- Tronnes H, Haugland HK, Bekassy AN, Helle SI, Sorbye H. Small cell lung cancer in a 14-year-old girl. *J Pediatr Hematol Oncol.* 2012; 34: e868.
- Yonemori K, Kunitoh H, Sekine I. Small-cell lung cancer with lymphadenopathy in an 18-year-old female nonsmoker. *Nat Clin Pract Oncol.* 2006; 3: 399-403.
- Jett JR, Schild SE, Kesler KA, Kalemkerian GP. Treatment of small cell lung cancer: diagnosis and management of lung cancer, 3rd ed: American College of Chest Physicians evidence-based clinical practice guidelines. *Chest.* 2013; 143: e400S-19S.
- Shepherd FA, Laskey J, Evans WK, Goss PE, Johansen E, Khamsi F. Cushing's syndrome associated with ectopic corticotropin production and small-cell lung cancer. *J Clin Oncol.* 1992; 10: 21-7.
- Winquist EW, Laskey J, Crump M, Khamsi F, Shepherd FA. Ketoconazole in the management of paraneoplastic Cushing's syndrome secondary to ectopic adrenocorticotropin production. *J Clin Oncol.* 1995; 13(1): 157-64.
- Toi-Scott M, Jones CL, Kane MA. Clinical correlates of bombesin-like peptide receptor subtype expression in human lung cancer cells. *Lung Cancer.* 1996; 15: 341-54.
- Kanaji N, Watanabe N, Kita N, et al. Paraneoplastic syndromes associated with lung cancer. *World J Clin Oncol.* 2014; 5: 197-23.
- G R, S G, N LR, Jp L, E B, J C. [Small Cell Bronchial Cancer in a 17-year-old Young Man]. *Rev Mal Respir.* 1994; 11(6): 607-9.
- Post GR, Lewis JA, Hudspeth MP, Caplan MJ, Lazarchick J. Disseminated neuroendocrine carcinoma in a pediatric patient: a rare case and diagnostic challenge. *J Pediatr Hematol Oncol.* 2012; 34: 200-3.
- Barbour M, Bujold KE, Tjarks BJ, Jassim AD. A Case of Small Cell Lung Carcinoma in a 15-Year-Old Boy and Literature Review: *J Pediatr Hematol Oncol.* 2018; 40(7): 563-6.