

Neurocysticercosis in an Immigrant, A Case Report from a Tertiary Hospital in Uganda

Langoya OD^{1*}, Bongomin F^{1,2}, Musubire AK^{1,3} and Kaddumukasa M¹

¹Department of Medicine, School of Medicine, College of Health Sciences, Makerere University, Kampala, Uganda

²Department of Medical Microbiology & Immunology, Faculty of Medicine, Gulu University, Gulu, Uganda

³Department of Neurology, Kirru National Referral Hospital, Kampala, Uganda

*Corresponding author:

Oriba Dan Langoya,
Department of Medicine, School of
Medicine, College of Health Sciences,
Makerere University, Kampala, Uganda,
E-mail: oribadanlangoya@yahoo.com

Received: 02 May 2021

Accepted: 17 May 2021

Published: 24 May 2021

Copyright:

©2021 Langoya OD. This is an open access article distributed under the terms of the Creative Commons Attribution License, which permits unrestricted use, distribution, and build upon your work non-commercially.

Citation:

Langoya OD. Neurocysticercosis in an Immigrant, A Case Report from a Tertiary Hospital in Uganda. 2021; V6(16): 1-4

Keywords:

Neurocysticercosis, Immigrant, Uganda

1. Abstract

1.1. Introduction: Neurocysticercosis (NCC) is one of the seven neglected endemic zoonoses targeted for elimination by the World Health Organization. NCC is a common primary cause of preventable epilepsy in many developing countries caused by the platyhelminth *Taenia solium* and yet the clinical diagnosis is often difficult as neurological presentation is non-specific. Herein, a case of NCC initially misdiagnosed as cerebral malaria in an immigrant is present.

1.2. Case Report: We present a 20-years old male, a Congolese refugee who presented to our neurology unit at Kiruddu National Referral Hospital, Uganda with a two weeks history of fever and focal convulsions. He was initially managed for cerebral malaria without any notable clinical improvement. He had no known illness, including human immunodeficiency virus infection. Brain computed tomography scan showed multiple calcified lesions in both cerebral hemispheres consistent with a diagnosis of NCC. We also discuss the diagnostic difficulties of neurocysticercosis, lifecycle along with potential sources of infection in this patient. Finally, we discuss the different ways of classifying NCC on current literature review.

1.3. Conclusion: This case report highlights a classical presentation of NCC along with importance of detailed history especially in areas of personal hygiene, food handling/cooking. In addition, we highlight neuroimaging findings, clinical management of a

life-threatening complication of NCC like Status epilepticus and Aspiration pneumonia with a resultant dramatic response to therapy.

2. Introduction

Neurocysticercosis (NCC), the most frequent parasitic disease of the central nervous system (CNS) in the world is caused by the larvae of the cestode *Taenia solium* which is endemic in many low and middle-income countries of the world [1] and is one of the seven neglected endemic zoonoses targeted for elimination by the world health organization (WHO), [2]. NCC is the leading cause of secondary epilepsy in NCC endemic regions worldwide [3] and in a recent systematic review and meta-analysis, the prevalence of NCC among persons living with epilepsy was estimated at 22%, Southern and Eastern Africa sub-region accounting for 45 % and 25 % of the cases, respectively [4]. NCC is a pleomorphic disease with a diverse array of clinical manifestations and the infection is dependent on a complex range of interconnecting factors, including number and size of the cysticerci, their stage of development and localization within the brain with resulting difficulties in accurate diagnosis and staging of the disease [5]. Therefore, diagnosis of NCC is often challenging, requiring a high index of suspicion especially in individuals with known epidemiologic risk factors. Herein, we present a case of NCC diagnosed in a young immigrant presenting with an index seizure episode.

3. Case Report

A 20-year-old male Congolese person of concern from a refugee settlement camp in Uganda, who presented to our neurology unit in Kiruddu National Referral Hospital (KNRH), Kampala, Uganda, with a 2 weeks history of high-grade fevers associated with rigors, severe generalized headache. He came in as a referral from a district hospital where he was being managed for a clinical diagnosis of a severe cerebral malaria with no improvement. Prior to his referral, he had a new onset multiple episode of initially focal convulsions starting from the right upper limb with secondarily generalized tonic-clonic convulsions each lasting 3 to 4 minutes without regaining consciousness in between. Upon arrival at the emergency unit at KNRH, he was still actively convulsing. Initial management with two doses of intravenous diazepam followed by intravenous phenobarbitone and supplemental oxygen 100% by nasal prongs was commenced. Post-ictally, he was drowsy, aphasic and had multiple tongue bites wounds. He had no known history of chronic illness or head injuries but parents reported occasional

history of moderate alcohol use. He is 6 months in Uganda and working casually as a car washer in a nearby swamp and family has a long-standing history of pork consumption.

On physical examination at admission, he was significant for wasting with a body mass index of 17Kg/m² (Weight of 43 kg, and Height of 1.58m), axillary temperature of 38.2°C and a tachycardia of 118 beats per minute. Glasgow coma scale of 8/15 (eye opening 1, Verbal response=02 and motor response M=06). His pupils were accommodative, equal 3mm but sluggishly reactive to light doll's eye absent. Neck was stiff, kerning's sign positive, he had generalized hypertonia in the right upper limbs, with brisk ankle tendon reflexes. Respiratory examination was notable for tachypnea and a diffuse bilateral crepitations. The remainder of the examination was noncontributory. An urgent brain computed tomography (CT) scan revealed multiple calcific cysts with surrounding areas of cerebral edema but no features of increased intracranial pressure like loss of grey-matter differentiation, brain herniation, effacement of the ventricles, basal cisterns and other CSF spaces (Figure 1).

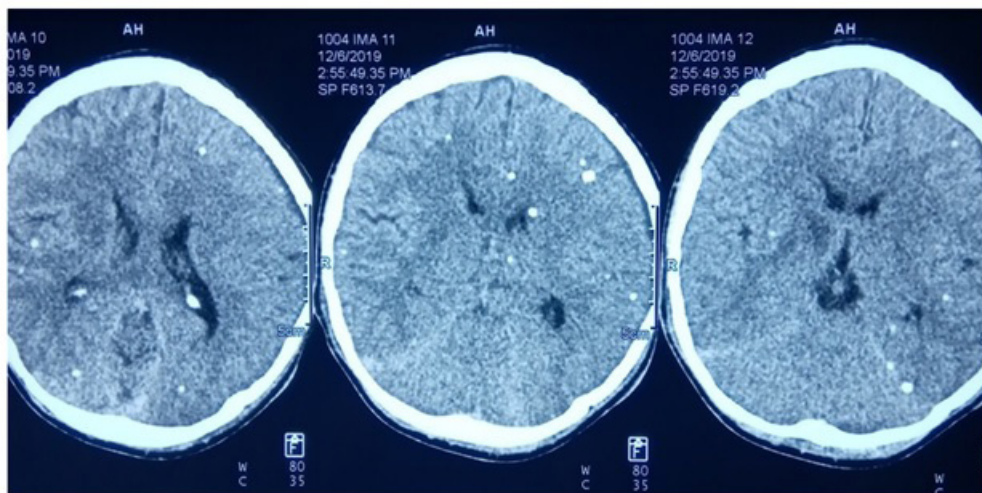


Figure 1

CT image of the head showing calcific cerebral cysticerci and lesion was surrounded by parenchymal edema, reflecting degenerative changes.

Lumbar puncture was performed, opening pressure was 15cmH₂O, the patient's cerebrospinal fluid (CSF) was devoid of white cells (<5), contained normal levels of glucose, 3.7g/l compared to 4.4g/l in serum and total protein of 0.22g/l. A complete blood count was unremarkable, with normal levels of eosinophils. Serum electrolytes revealed mild Hypochloremia of 95mmol and dilutional Hyponatremia of 130mmol/l which was managed conservatively with fluid restriction. Liver chemistry is significant for aspartate aminotransferases (AST)/alanine aminotransferase (ALT) ratio of 1.5, a raised gamma glutamyl transferase of 70U/l and mild hypoalbuminemia of 31g/l. Stool specimen examination for *T. solium* eggs by microscopy was negative. HIV serology, toxoplasma titres, serum and CSF cryptococcal antigen test, urine lipoarabinomannan

and Hepatitis B surface antibody were all negative

A diagnosis of NCC was made complicated by status epilepticus and aspiration pneumonitis. He was commenced on phenytoin for seizure control and then switched to sodium valproate, intravenous dexamethasone 4mg once a day for 1 week then switched to oral prednisolone 20mg for another week. Oral albendazole was initially started at 400mg twice daily for 2 weeks which was de-escalated to 400mg once daily for 6 months at discharge. While on treatment from ward, GCS steadily increased from 8/15 to 15/15 by day 7 of treatment. Patient was discharged on day 13 of admission however repeat brain CT-scan was not done due to financial constraints.

4. Case Discussion

We have presented a 20-year-old male that was initially treated for malaria but eventually diagnosed with Neurocysticercosis. NCC is estimated to be the most common parasitic infection of the brain and of adult-onset epilepsy worldwide [3]. The recognition and

clinical suspicion for NCC is of paramount importance in acute care and especially in resource constraint settings because of its pleomorphic clinical presentation and latent period after exposure, which can persist for years.

This patient was a person of concern from Democratic Republic of Congo for which is an endemic area of for *T. solium* cysticercosis with an estimated prevalence of 22% as measured with an antigen-ELISA [6]. Patient was living in a displaced camp in Uganda for 6 months, a crowded environment with reportedly poor access to clean water services, history of pork consumption and on and off alcohol intake. This patient probably presented with reactivation of a remote exposure rather than a new infection. We hereby highlight the significance of a thorough history and physical examination with particular attention to exposure and clinical presentation to increase the suspicion of possible NCC.

Clinically patients present with Seizures, headaches and intracranial hypertension. In endemic settings, [7]. Seizures are usually focal with generalization or generalized are by far the most common manifestation and in a large majority, this represent the most common or sole presentation of the disease in 70% of patients and are due to degenerating cysts or calcified granulomas, more rarely by infarcts in patients with subarachnoid involvement [8]. However, the signs and symptoms of NCC are particularly diverse and depend upon the number, location, growth, stage of degeneration and inflammation, host factors [8]. This patient of concern presented with multiple parenchymal degenerative/calcific cysts with surrounding cerebral edema on brain CT- scan. It was not clear on imaging whether this patient had viable parenchymal cysts but clinically, the most severe presentation of status epilepticus, prompted us to start him on intravenous corticosteroids to control the brain inflammation and then antihelminth therapy.

The diagnosis of neurocysticercosis rests on a constellation of findings including epidemiology, symptoms, signs, serology, brain imaging. Initial evaluation should include careful history and physical examination, and neuroimaging studies [9]. According to the 2017 Clinical Practice Guidelines by the Infectious Diseases Society of America (IDSA) and the American Society of Tropical Medicine and Hygiene (ASTMH), serologic testing with enzyme-linked immunotransfer blot (EITB) should be used as a confirmatory test in patients with suspected NCC rather than Enzyme-linked immunosorbent assay (ELISA) tests using crude antigens [9]. This test was not performed in this patient due to financial constraints. However, we also emphasize that much as enzyme-linked immunotransfer blot is the serological test of choice, and because there is no single definitive test, a high level of suspicion should be maintained for NCC if warranted by the clinical context [10]. Neuroimaging is the preferred method for NCC diagnosis, using CT and MRI scans it is possible to visualize infecting cysticerci and assess their number and location within the CNS. evolutionary

stages further support the diagnosis of NCC (Nash et al. 2005).

In resource-poor settings mainly CT is used, if available. MRI enables clinicians to perform a more precise disease staging and case follow-up. It also shows higher sensitivity in detection of obscure lesions, such as the recognition of perilesional oedema or gliosis and degenerative changes of the parasite, as well as small cysts that may be located in the brain stem, cerebellum and cerebral ventricles [11].

The heterogeneity of clinical presentations of NCC not only complicates the diagnostic procedure but also affects the management plan for the disease; there can be no single, standard therapeutic approach when so many interconnecting factors must be considered [5]. Treatment depends upon the acuteness and severity of presentation, types and degree of involvement, stage of cyst degeneration and accompanying inflammation, and potential for future complications [8]. Treatment includes immediate measures to prevent undo morbidity or death, surgical procedures, anti-epileptic drugs (AED) to prevent or decrease the severity and number of seizures, corticosteroids to decrease or prevent the inflammatory reaction, and anthelmintic medications to kill cysts [8,12]. The use of cysticidal drugs in the treatment of NCC has attracted controversy, as the use of such drugs may pose more risk to the patient than benefit, due mostly to the extensive inflammatory response that can be stimulated in response to the mass death of cysts within the CNS [12] however, several studies have shown that cysticidal drugs do have a positive effect in reducing symptoms such as seizures and headaches, and hasten the resolution of parenchymal lesions; this argument is strengthened by many clinicians' apprehensions over allowing a live parasite to continue its development in the brain without challenge [12,13] and the anthelmintic drug of choice is Albendazole with better penetration into the central nervous system, greater cysticidal effect, less interaction with other drugs [11]. Administration of steroids is a vital step in the regulation of NCC-related inflammation in the CNS to control the acute inflammatory process that occurs following degradation of viable cysts. Prednisolone or dexamethasone are commonly used as adjuncts to cysticidal therapy [5].

References

1. Fabiani S, Bruschi F. Acta Tropica Neurocysticercosis in Europe : Still a public health concern not only for imported cases. *Acta Trop*. 2013; 128(1): 18-26.
2. Rizvi SAA, Saleh AM, Frimpong H, Mohiy HMA, Ahmed J, Edwards RD, et al. Asian Pacific Journal of Tropical Medicine Neurocysticercosis : A case report and brief review. *Asian Pac J Trop Med*. 2016; 9(1): 100-102. doi:10.1016/j.apjtm.2015.12.020
3. Hector H. Garcia RHG. Hunter's Tropical Medicine and Emerging Infectious Disease. 10th ed. (Edward T. Ryan, David R. Hill, Tom Solomon, Naomi E. Aronson, Timothy P. Endy, ed.). Canada: Elsevier; 2019.

4. Femi L, Adamu B, Muhammed A, Desola S, Isa A, Daiyyabu I. Seizure : European Journal of Epilepsy Neurocysticercosis in people with epilepsy in Sub-Saharan Africa : A systematic review and meta-analysis of the prevalence and strength of association. *Seizure Eur J Epilepsy*. 2020; 76(September 2019): 1-11. doi:10.1016/j.seizure.2020.01.005
5. Gripper LB, Welburn SC. *Acta Tropica* Neurocysticercosis infection and disease – A review. *Acta Trop*. 2017; 166: 218-224. doi:10.1016/j.actatropica.2016.11.015.
6. Kanobana K, Praet N, Kabwe C, Dorny P, Lukanu P, Madinga J, et al. High prevalence of *Taenia solium* cysticercosis in a village community of Bas-Congo, Democratic Republic of Congo. *Int J Parasitol*. 2011; 41(10): 1015-1018. doi:10.1016/j.ijpara.2011.06.004
7. WHO. *Taenia Solium Taeniasis / Cysticercosis Diagnostic Tools*. 2015; (December): 1-26.
8. Nash TE, Garcia HH. UKPMC Funders Group Diagnosis and Treatment of Neurocysticercosis. 2012; 7(10): 584-594. doi:10.1038/nrneurol.2011.135.Diagnosis
9. White AC, Coyle CM, Rajshekhar V, Singh G, Hauser WA, Mohanty A, et al. Guidelines Diagnosis and Treatment of Neurocysticercosis : 2017 Clinical Practice Guidelines by the Infectious Diseases Society of America (IDSA) and the American Society of Tropical Medicine and Hygiene (ASTMH). 2018; 98(4): 945-966. doi:10.4269/ajtmh.18-88751
10. Bock M, Garcia HH, Chin-hong P, Baxi SM. Under seize : neurocysticercosis in an immigrant woman and review of a growing neglected disease. 2015: 1-5. doi:10.1136/bcr-2015-212839
11. Landscape analysis : management of neurocysticercosis with an emphasis on low- and middle-income countries.
12. Sinha S, Sharma BS. Neurocysticercosis: A review of current status and management. *J Clin Neurosci*. 2009; 16(7): 867-76. doi:10.1016/j.jocn.2008.10.030
13. Jr ACW, Coyle CM, Rajshekhar V, Singh G, Hauser WA, Mohanty A, et al. Diagnosis and Treatment of Neurocysticercosis : 2017 Clinical Practice Guidelines by the Infectious Diseases Society of America (IDSA) and the American Society of Tropical Medicine and Hygiene (ASTMH). 2018;66(8). doi:10.1093/cid/cix1084