

One Stage Operation in Bilateral Pulmonary and Spleen Hydatid Cyst in Uncommon Localization

Aghajanzadeh M¹, Pourahmadi Y^{2*}, Rimaz S⁴, Jafarnegad A³, Tangestaninejad A³, Fomani AA³, Ashoobi MT², Habibzadeh² and Hossini M²

¹Department of Thoracic Surgery, Guilan University of Medical Sciences, Rasht, Iran

²Department of General Surgery, Guilan University of Medical Sciences, Rasht, Iran

³Department of pulmonology, Guilan University of Medical Sciences, Rasht, Iran

⁴Department of Anesthesiology, Inflammatory Lung Diseases Research Center, Guilan University of Medical Science, Rasht, Iran

*Corresponding author:

Yousha Pourahmadi,
Department of General Surgery, Guilan University
of Medical Sciences, Rasht, Iran,
E-mail: maghajanazadeh2003@yahoo.com

Received: 11 Apr 2021

Accepted: 03 May 2021

Published: 08 May 2021

Copyright:

©2021 Ozrudi MF. This is an open access article distributed under the terms of the Creative Commons Attribution License, which permits unrestricted use, distribution, and build upon your work non-commercially.

Citation:

Ozrudi MF. One Stage Operation in Bilateral Pulmonary and Spleen Hydatid Cyst in Uncommon Localization. *Ann Clin Med Case Rep.* 2021; V6(14): 1-5

Keywords:

Abdominal; Echinococcus granulosus; Hydatidosis

1. Abstract

The lung is the second most commonly organ which affected after liver chyst by echinococoss, and the bilateral involvement of lung is rare and Primary spleen hydatid cysts are very rare seen even in endemic country. We report the case of a 32-year-old man who presented with left thoracic and left upper abdominal pain and dry cough evolving for four months. Thoracic CT scan after injection of the contrast media revealed two homogeneous, rounded cystic lesions enhancing, located in the lower lobes of right and left lung. An abdominal CT scan was performed for liver hydatid cyst and revealed a cystic formation of the spleen. The diagnosis of bilateral hydatid pulmonary cyst associated with hydatid spleen location was then made. The patient underwent one stage bilateral antero-lateral thoracic surgery with tans -diaphragm for three cyst of two lung and splee. The postoperative course was uneventful. Management of bilateral pulmonary hydatid cyst is controversial. Some authors recommend operating bilateral cysts in two-stage surgery, with an interval of three to four weeks between procedures. Some authors recommended one stage with antero-lateral thoracotomy The involvement of the spleen is rare and is generally secondary to the rupture of, hepatic cysts.

1.1. Conclusion: Bilateral pulmonary hydatidosis associated with hydatid cyst of the spleen is rare. Imaging investigations and especially CT scan are the best tool for diagnosis. Surgery remains to be the treatment modality of choice.

2. Introduction

Hydatid cys (HC) is a serious health problem in some countries of world and is endemic in central Asia, Mediterranean regions, Middle East, Australia, New Zealand, South America [2, 3]. (HC) is endemic in Iran [1] HC is an anthroozoonosis due to the development of the larval form of taenia Echinococcus granulosus in humans [1].

HC involves liver in 65 to 75%, lung in 27%, kidney in 3%, and brain in 1 to 2% [1]. The disease occurs less frequently in other organs as spleen, pancreas, heart, adrenal and muscles, soft tissue rib and mediastinum [1,5]. Concomitant pulmonary and spleen hydatid cyst is very rare [3,4]. Involvement of hydatid cyst in the spleen is rare, especially when the spleen is the primary and isolated organ affected and infected by Echinococcus disease [7]- Bilateral pulmonary hydatidosis accounts for 4%-26.7% of all cases of pulmonary hydatidosis. Bilateral pulmonary hydatidosis accounts for 4% to 26.7% in of all cases [1,3] and multiple pulmonary hy-

datid cysts occur in 30% of cases [3,4] exceptional (4). We report the case of an unusual presentation of bilateral pulmonary hydatid cyst associated with spleen location and the surgical management of this case and our experience.

3. Case presentation

A 29-year-old man building worker presented with right, left thoracic, left upper quadrant pain and dry cough for four months duration without fever. Past medical history of patient was negative, Physical examination revealed slight decrease of breath sound in the basithoracic. The patient had no history of close contact with dogs or other animals. A chest X-ray showed opacities or cystic lesions with very limited water tones in the right and left side of two lungs (Figure 1). A further CT-scan of chest revealed the presence homogeneous, rounded fluid formations with regular, thin-walled, contours after injection of the contrast media, right and left side of two lesions was enhance. The cystic lesions locations were in the lateral basal segments of the lower lobes. The size of cyst in right side was 88×98 mm on the left side was 10×82 mm, without any complications as rupture or abscess formation (Figure 2). An abdominal CT scan was performed in for to rule out the cause of left upper quadrant pain and hepatic l hydatid cyst Abdominal CT scan show a homogeneous cystic formation of the spleen. The had

an oval shape with regular contours and with enhancing after injection of the intra venous contrast media. The size of spleen cyst was $10 \times 6 \times 7$ mm and presents a close contact with the left hemidiaphragm (Figure 3,4). The diagnosis was mad by CT-sca and CXR, bilateral hydatid cyst of pulmonary associated with hydatid cyst of spleen location. Because of good condition of patient(power and young) , Our Surgical management was one stage for this case As: patient putt in Simi supine position on the left side and start with and particularly with the left side which is the site of the largest cyst of right side , right lateral thoracotomy in the sixth intercostal space with cystectomy, peri-cystectomy and captinnage for obliteration of remnant cavity (Figure 5,6,7) then the pherintomy was performed and evacuation of spleen cyst and omentoplasty for obliterating of remnant cavity, splnectom not performed because 80% of spleen was intact, diaphragm was close with nylon sutures .Chest Tube placed in left pleural space and ches wall closed The patient putt in supine position next surgical procedure was right antero-lateral thoracotomy in the sixth intercostal space with cystectomy, peri-cystectomy and captinnage for obliteration of remnant cavity as by the same procedure on the left side .. The patient was discharged six-day post operation with good condition on oral albendazole 800 mg per day for three course with 14 day interval (Figure 8) post- operative CXR.

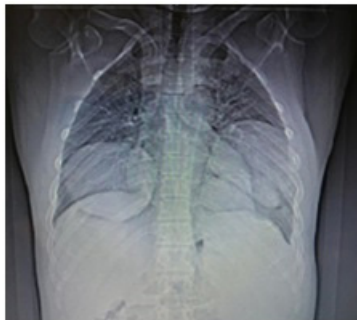

Figure 1: Show CXR with billateral cystic mass of two lung.

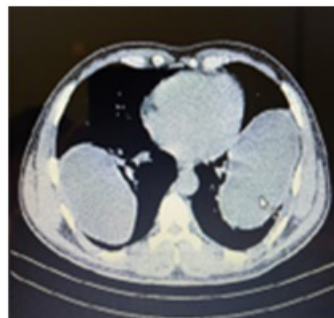


Figure 2: Show CT-scn of chest with billateral cystic mass of two lung.

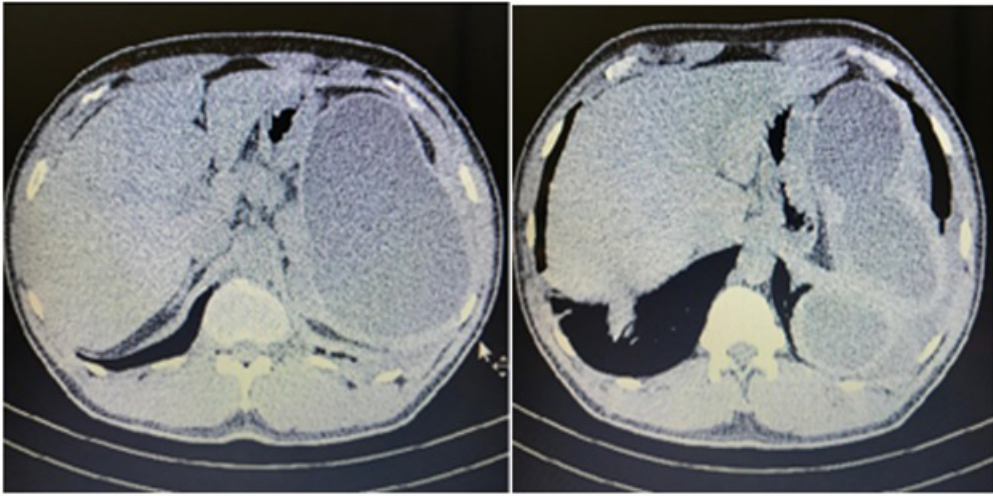


Figure 3 and 4: Show CT-sca of abdoman with cystic mass of spleen.

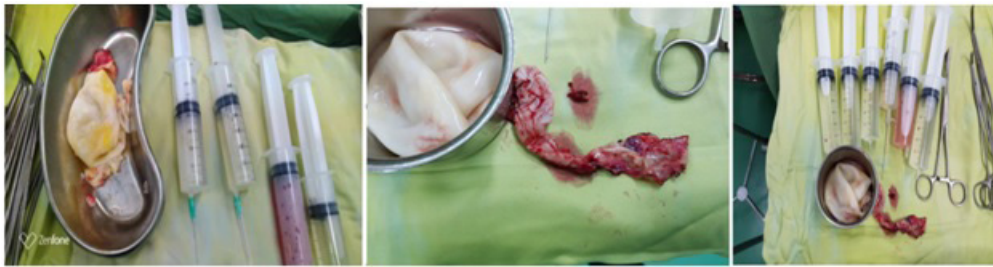

Figure 5,6,7: Show laminatted membran .pricyst and fluid of cysts after aspiration.

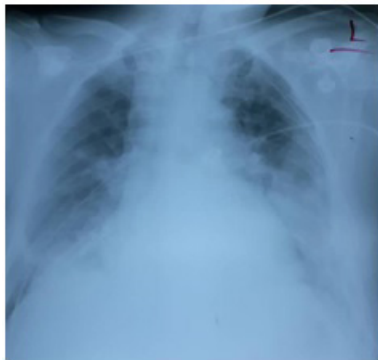

Figure 8: Show postoperative CXR.

4. Discussion

Hydatid (HC) has a worldwide distribution and it is a serious health problem in endemic areas such as Mediterranean countries. Hydatid cyst (HC) is endemic in central Asia, Mediterranean regions, Middle East, Australia, New Zealand, South America [2,3]. (HC) is endemic in Iran too [1]. HC is an anthroponosis due to the development of the larval form of taenia Echinococcus granulosus in humans [1].

Human infected by the larval stage of Echinococcus granulosus, secondary to the ingestion of taenia eggs which defecated by dogs [1]. After ingestion of eggs especially from vegetable, in the stomach the eggs lose their cutting cover of eggs and conversion to larvae stage. Larvae penetrate the mucosa of the proximal portion of jejunum and may reach through the venous system and lymphat-

ic channels, first organ which involve is liver and second organ which infected by larvae is larvae lung and next larvae reach to any region of the body and then to transform into cysts form [6]. In literatures It is well known that the lung is the second most common organ which affected after the liver [2]. HC of Lung localization usually is unilateral. The bilateral involvement of lung is unusual with a prevalence ranging from 4% to 26.7% in endemic areas [7]. Clinically, intact HC OF lung, are usually without any symptoms and diagnosis made incidentally. In some cases, as in our case, the patient may present with dry cough and chest pain. Radiological investigations are the first method for diagnosis. The diagnosis of pulmonary HC is Chest radiograph and Computed tomography (CT) of chest and are the imaging modalities of choice. The chest x-ray is considered to be the initial diagnostic tool in pulmonary hydatid cyst with a sensibility of 90%. Computed tomography (of

chest CT -sca) is useful for evaluating HC especially complicated or uncomplicated cyst and help for differential diagnoses of others cystic lesion of chest [8]. hydatid cyst in the spleen is rare, especially when the spleen is the primary and isolated organ infected by hydatid disease [7- 9]. The range of involvement is about 2% of cases of hydatid cyst of spleen and occurs when the leave escape from liver and lung filters [7-9]. Clinically, nearly 30% of the patients with splenic hydatid cysts are asymptomatic [13]. Splenomegaly is the most frequent finding, [13,15]. [13]. The symptoms are few and non-specific which comprises mainly an abdominal mass that mostly located in the left hypochondrium and less frequently in the epigastrium, and a pain that is usually a dull A pain in the lumbar, and dyspnea due to pushing up of the left diaphragm [1,2,8,10]. In our study group, two patients had stomach ache and two had left upper quadrant pain, rash and pruritus, and one case had dyspeptic complaints. U&S and CT scans, alone or in combination, can help a definite diagnosis of splenic hydatid cysts in almost all cases [13].

Surgery is still the unique therapeutic modality for pulmonary hydatid cyst. The aim is to remove the entire cyst with preservation of the maximum of lung parenchyma. Management of bilateral pulmonary hydatid cysts controversial. Some authors recommend operating bilateral cysts in two-stage surgery, with an interval of three to four weeks between procedures [9]. Other authors demonstrated that one-stage surgery is superior to a classic two-stage operation as it decreases the morbidity, hospital stay, and cost [11]. The one-step surgery can be performed either through double antero-lateral thoracotomy or median sternotomy to reduce the cost of the intervention and avoid second general anaesthesia. In our practice we use on stage antero-lateral thoracotomy. It is mainly indicated for young, good health patient as our case [10]. Involvement of spleen is generally secondary to the rupture of hepatic ,renal or interapritonal hydatid cysts. Generally, the diagnosis of hydatid cyst of the psoas muscle is delayed as the latter is most of the time asymptomatic, but enlarged cysts may compress the adjacent organs like ureter, kidney, or vertebra; then it becomes symptomatic [13]. In our case, the patient was symptomatic. Surgery is the only curative treatment modality for spleen hydatid cyst. It can be performed either through the laparotomy and splenectomy or preservation of spleen in small cyst. Total cystectomy is not possible in most of the case, because of the adhesions between the cyst and its neighboring organs [15]. In our case, surgery was performed in one stage. In stage one left side with antero-lateral thoracotomy evacuation and pricystectomy and capitonage was performed, after this procedure left hemi diaphragm was opened because splenic localization was just to the diaphragm. aspiration, evacuation, pricystetomy and omentoplasty was performed. After chest tube insertion diaphragm and chest wall was closed. The position of patient change to supine and surgery of right lung cyst performed as left lung. One stage procedure was performed because the patient

was young and power full. For prevention rupture of cysts medical treatment has limited indication [16]. Patient discharged on six day post operative in good condition with Albendaso 800 mg daily for three course of 28 days with 14 day intervals.

5. Conclusion

Bilateral pulmonary hydatid cyst associated with hydatid cyst of the spleen is a rare entity. Radiological investigations and especially CT scan and Ultrasonography for splenic are the mainstay of diagnosis. Surgery is to be the treatment modality of choice. We conclude one stage surgery for bilateral hydatid cyst of lung with liver and spleen cysts in some patients may be a good procedure.

References

1. Aghjanzadeh M, Safarpour F, Amani H. One-Stage Procedure for Lung and Liver Hydatid Cysts. *Asian cardiovasc thorac ann.* 2008; 16(5): 392-5.
2. McManus DP, Zhang, Li WJ, Bartley PB. Echinococcosis. *Lancet.* 2003; 362(9392): 1295-1304.
3. Yaghoobi MH, Sabahi MM and Zibaei M. Imaging features of the lungs hydatid cyst disseminated into the brain and spleen. *Radiol Case Rep.* 2019; 14(8): 903-905.
4. Ismail IB, Zenaidei H, Rebi S, Zoghiami A. Primary hydatid cyst of the fallopian tube. *IDCases.* 2020; 20: e00790.
5. Agha RA, Borrelli MR, Farwana R, Koshy K, Fowler A, Orgill DP, et al. The SCARE 2018 statement: updating consensus Surgical CAse REport (SCARE) guidelines, *Int J Surg.* 2018; 60: 132-136.
6. Sarkar M, Pathania R, Jhobta A, Thakur BR, Chopra R. Cystic pulmonary hydatidosis. *Lung India.* 2016; 33: 179-191.
7. Hasdiraz L, Onal O, Oguzkaya F. Bilateral staged thoracotomy for multiple lung hydatidosis. *J Cardiothorac. Surg.* 2013; 8: 121.
8. Aghajanzadeh M, Asgary MR, Hemmati H, Delshad MSE, Samidost P, Mosaffaei O. Multiple and bilaterally pulmonary hydatid cystic and liver mimicking metastatic lesion from ovarian malignancy. *J Liver Res. Disord Ther.* 2018; 4 (2): 76-78.
9. Aghajanzadeh M, Asgary MR, Foumani AA, Alavi SE, Rimaz S, Banihashemi Z, Hajipoor E and Massahnia S. Management of pleural Complications of Lung and Liver Hydatid Cysts in 34 Patients. *Int J Life Scie.* 2018; 8(4): 15-19. PMID: 25191430.
10. Aghajanzadeh M, Aghajanzadeh G, Ebrahimi H, Jahromi SK, Maafi AA, and Massahnia S. One Stage Operation for Five Giant Hydatid Cysts of Both Lungs and Liver in a 20-Year-Old Female. *Tanaffos.* 2012; 11(3): 52-54.
11. Aghajanzadeh M, Kiaabadi AR, Mohtasham B, Saravi MK, Mosafai O, Ghotbi F. One-staged anterolateral thoracotomy for bilateral lung hydatid cysts. *Ann Trop Med Public Health.* 2017; 10: 1601-6.
12. Delshad MSE, Aghajanzadeh M, Hemmati H, Rimaz S and Shojaee R. Complicated primary Hydatid Cyst in brachioradialis An extremely unusual site. *Merit Research Journal of Medicine and Medical Sciences.* 2016; 4(2): 076-078.

13. Messaoudi H, Zayène B, Ismail IB, Lajm M, Lahdhili H, Hachicha S, et al. Bilateral pulmonary hydatidosis associated with uncommon muscular localization. *Int J Surg Case Rep.* 2020; 76: 130-133.
14. Aghajanzadeh M, Jalal SA, Saffar MR, Youseffi S, Mousavi MS and Habibzadeh K. Reports of Symptoms, Diagnosis and Management of Eight Cases of Primary and Isolated Splenic Hydatid Cyst. *JSM Clinical Cytology and Pathology.* 2019; 4: 5.
15. Angulo JC, Granell J, Muguera J, Sanchez-Chapado M. Primary bilateral hydatidosis of the psoas muscle, *J Urol.* 1999; 161: 1557-1558.
16. Maoulik K, Lokesh S, Uma D, Shayeri R, Vikas B. Bilateral pulmonary hydatid cyst in an 11year boy: a case report. *Arch Clin Med Case Rep.* 2020; 4(3).