

## Clinical and Genetic Analysis of Multi-System Pseudohypoaldosteronism Type 1 Caused by a Novel Splice Site Mutation of the Beta Subunit Gene of Epithelial Sodium Channel (Enac)

Hu S, Yang H, Li C, Jiang Q, Qiao L, Hu C and Li T\*

Department of Paediatric Endocrinology and Metabolism, Qingdao Women and Children's Hospital, Shandong, 266000, China

### \*Corresponding author:

Tang Li,  
Department of Paediatric Endocrinology and  
Metabolism, Qingdao Women and Children's  
Hospital, Shandong, 266000, China,  
E-mail: drlitang@hotmail.com

Received: 22 Mar 2021

Accepted: 08 Apr 2021

Published: 13 Apr 2021

### Copyright:

©2021 Li T. This is an open access article distributed under the terms of the Creative Commons Attribution License, which permits unrestricted use, distribution, and build upon your work non-commercially.

### Author Contribution:

Hu S, Yang H, Li C, Jiang Q, Qiao L, Hu C and Li T. these authors are contributed equally to this article.

### Keywords:

Electrolyte disturbance; Cholestasis; Rash; Elevated plasma aldosterone; Renin activity; Metabolic acidosis

### Citation:

Li T. Clinical and Genetic Analysis of Multi-System Pseudohypoaldosteronism Type 1 Caused by a Novel Splice Site Mutation of the Beta Subunit Gene of Epithelial Sodium Channel (Enac). *Ann Clin Med Case Rep.* 2021; V6(11): 1-6.

## 1. Abstract

**1.1. Background:** This article aims to provide a comprehensive review of the clinical features and genetics basis of multi-system pseudohypoaldosteronism type 1 caused by *SCNN1B* gene mutations.

**1.2. Methods:** To diagnosis a Chinese child with severe multi-system pseudohypoaldosteronism type 1 (sPHA1) definitely, whole-exome sequencing (WES) was performed on the child and parents. The clinical and genetic data of the Chinese boy with hyperkalemia, hyponatremia, elevated plasma aldosterone and plasma renin activity, high testosterone, hypercortisolism and metabolic acidosis were analyzed. Literatures on sPHA1 published up to November 2020 were identified from PubMed, ClinVar, Online Mendelian Inheritance in Man (OMIM), Human Gene Mutation Database (HGMD), Wan Fang databases and China National Knowledge Infrastructure using the keywords "multi-system pseudohypoaldosteronism type 1", "ENaC" and "*SCNN1B*".

**1.3. Results:** The patient had electrolyte disturbance, Cholestasis, rash, cardiac arrhythmias, acute renal failure, elevated plasma aldosterone and plasma renin activity, high testosterone, hypercortisolism and metabolic acidosis. A novel homozygous splicing site

mutation c.1270+2T>C of *SCNN1B* was found in this patient. The parents were carriers, but had no symptoms.

**1.4. Conclusion:** The patient's clinical phenotype and laboratory results were consistent with sPHA1. The novel homozygous mutation c.1270+2T>C of *SCNN1B* was its pathogenic mutation, which has not been reported in HGMD and ClinVar databases.

## 2. Introduction

Pseudohypoaldosteronism (PHA) is a rare heterogeneous disease, also known as aldosterone resistance, characterized by potassium and sodium imbalances incorrectly attributed to a defect in aldosterone production (Casas-Alba et al., 2017) [1]. Three different forms of PHA have been described: type 1 PHA (PHA1) characterized by severe dehydration accompanied by hyperkalemia, hyponatremia and metabolic acidosis with paradoxically increased serum aldosterone concentration (Amin et al., 2013) [2]. PHA1 was first reported in an infant by Cheek & Perry in 1958, which was clinically subdivided into two forms: PHA1a, an autosomal dominant renal form and PHA1b, an autosomal recessive systemic form, also known as sPHA1 (GopalKothandapani et al., 2019) [3]. Type 2 PHA (PHA2) also known as Gordon syndrome or familial hyperkalemic hypertension, characterized by hypertension, hyperkalemia,

hyperchloremic acidosis. Type 3 PHA(PHA3) or transient PHA characterized by a diminished glomerular filtration rate (GFR), secondary to several renal pathologies, such as obstructive uropathy, sickle cell and lead nephropathy, amyloidosis, and urinary tract infections (Bonny, Knoers, Monnens & Rossier 2002) [4].

sPHA1 appears in newborn infants with vomiting, apathy, dehydration, metabolic acidosis, hyperkalemia and hyponatremia combined with high plasma renin and aldosterone concentrations. Inactivating mutations in the amiloride-sensitive epithelial sodium channel (ENaC) is the cause of sPHA1, which consists of  $\alpha$ ,  $\beta$  and  $\gamma$  subunits encoded by the non-voltage-gated 1  $\alpha$  gene (SCNN1A), non-voltage-gated 1  $\beta$  gene (SCNN1B) and non-voltage-gated 1  $\gamma$  gene (SCNN1G), located on chromosome 12p13.1, 16p12.2 and 16p13.11, respectively (Strautnieks et al., 1996) [5]. The ENaC is a membrane bound ion channel that is involved primarily in the reabsorption of sodium ions at the collecting ducts of nephrons to maintain sodium homeostasis (Wang et al., 2013) [6]. The ENaC channel exists in aldosterone-sensitive target organs including distal convoluted tubule, connecting tubule and collecting duct of the kidney, distal colon, salivary, sweat glands and lung (Tajima, Morikawa, & Nakamura, 2017) [7]. So sPHA1 not only shows salt wasting syndrome but also shows recurrent upper and lower respiratory tract infection, cholelithiasis, skin rashes. Patients with sPHA1 have a severe clinical manifestation with recurrent life-threatening episodes of salt loss and hyperkalemia, who require high salt supplementation and potassium binding resins to redress their hyponatremia and hyperkalemia, relieve their symptoms and avoid serious complications or death. The clinical signs improve with age, whilst, that may recur during periods of salt restriction diet (Casas-Alba et al., 2017; Kino & Chrousos, 2011) [8,1]. Adachi et al found that the urine Na-Cl- cotransporter (NCC) expression increased in a patient with the sPHA1 compared with healthy individuals. Based on the major finding, they speculated that the increase of NCC expression can make up for the loss-of-function of ENaC. Therefore, this mechanism might be responsible for the improvement of sPHA1 patients with advancing age (Gopal-Kothandapani et al., 2019; Adachi et al., 2001) [3,9].

Though some cases of patients with sPHA1 have previously been reported, the majority of presented mutations are in the subunit of  $\alpha$ -ENaC, however, mutations in  $\gamma$ - and  $\beta$ - ENaC are rarely described (Nobel et al., 2016) [10]. We present a case of a patient with one novel homozygous SCNN1B mutations resulting in severe hyperkalemia and hyponatremia due to sPHA1, who was admitted to Qingdao Women and Children Hospital, in September 2019. The current pertinent literatures about the clinical features and molecular basis of sPHA1 caused by SCNN1B mutations were reviewed.

### 3. Patient and Methods

We reviewed the clinical features, biochemical and hormonal char-

acters, and molecular genetic analysis results of one patient from a non-consanguineous family.

### 4. Case Presentation

The male patient was born by spontaneous vaginal delivery at full term, had a birth weight of 3,240 g and normal Apgar score. He is the first child of a non-consanguineous couple (The patient's mother had two times of gestation and one time of parturition). Family history was non-contributory. He was transferred to our neonatal intensive care unit from maternity ward several hours after birth due to neonatal jaundice. Physical examination revealed skin yellowness and severe eczema like rashes. No skin hyperpigmentation was observed, normal male external genitalia and other system examinations were normal. On the 3rd day after admission, he was noted to be dyspneic and presented decreased activity, and then put on noninvasive continuous positive end expiratory pressure ventilation. Emergency laboratory evaluation showed marked hyponatremia (Na<sup>+</sup> 119 mmol/l), hyperkalemia (K<sup>+</sup> 10.4 mmol/l), diminished GFR (creatinine 111  $\mu$ mol/l and blood urea nitrogen 16.8 mmol/l, the reexamination was normal after 2 days). Following the collection of critical blood samples, treatment for adrenal salt wasting crisis was initiated, including fluid resuscitation, hydrocortisone, fludrocortisone. Anti-potassium therapies used insulin and glucose infusion, calcium gluconate and peritoneal dialysis. Elevated plasma adrenocorticotrophic hormone (ACTH) and cortisol ruled out the diagnosis of congenital adrenal cortical hyperplasia (CAH). Computed tomography scan of the adrenal glands showed normal adrenal gland with no hyperplasia. The results of the patient's newborn screening test and tandem mass spectra were normal. Elevated urinary sodium excretion, and reduced urinary potassium excretion with normal blood pressure and elevated plasma renin activity and aldosterone levels suggested a diagnosis of PHA. Secondary PHA was excluded since renal ultrasound, urinalysis, and urine culture were normal. Hydrocortisone and fludrocortisone therapies were stopped. He was discharged at the age of 1 month with sodium polystyrene sulfonate 56 ml/day, sodium chloride 3.5 g/day, which normalized his serum potassium and sodium levels. During a 13-month follow-up period, four salt wasting crises occurred due to poor feeding, vomiting, and hospitalization for bronchopneumonia was at 6 months old. Routine laboratory examination was done on 6 months old, no specific abnormality was noted. The results of laboratory evaluation are shown in Table 1.

### 5. Ethical approval

The research related to human use complied with all the relevant national regulations, institutional policies and is in accordance with the tenets of the Helsinki Declaration, and has been approved by the Ethics Committee of Qingdao Women and Children's Hospital.

**Table 1:** The results of laboratory evaluation

Laboratory test	Value	Reference range
Initial presentation		
Sodium	119	135-145 mmol/l
Potassium	10.4	3.5-5.5mmol/l
24-h urine sodium	185	35-210 mmol/l
Aldosterone	342.01	1-16 ng/dl
Plasma renin activity	1051.01	4-24 ng/l
Bicarbonate	15.9	22-26 mmol/l
Cortisol	>2069.25	118.6-618 nmol/l
ACTH	51	0-46 pg/ml
Dehydroepiandrosterone sulfate	0.86	0.36-4.9ug/ml
Androstenedione	94	16-178ng/dl
17-OH Progesterone	25	4-165ng/dl
Review of abnormal results		
Sodium	140	137-147mmol/l
Potassium	4.9	3.5-5.3mmol/l
Aldosterone	65.12	1-16ng/dl
Plasma renin activity	180.07	4-24ng/l
cortisol	250.2	118.6-618nmol/l
ACTH	28.4	0-46pg/ml

## 6. Methods

Informed consent for genetic analysis was signed by Children's parents. Approximately 2 mL peripheral blood (EDTA anticoagulant) of the proband and her parents were collected, and genomic DNA was extracted using QIAamp Blood Midi Kit (QIAGEN, Germany) according to the instructions.

## 7. Whole exome sequencing

Exome library preparation was accomplished by GenCap custom enrichment kit (MyGenostics, Beijing) following the manufacturer's protocol. The enriched libraries were sequenced on an Illumina NextSeq 500 sequencer (Illumina, San Diego, CA, USA) for paired-end reads of 150 bp.

## 8. Data Analysis

Following sequencing, Low-quality variations were filtered out using a quality score  $\geq 20$  and Burrows-Wheeler Aligner software (BWA) was used to align the clean reads to the reference human genome (hg19). Single-nucleotide polymorphisms (SNPs), insertions or deletions (InDels) were determined using the Genome Analysis Toolkit software (GATK). After above steps, the data would be transformed to VCF format, variants were further annotated by ANNOVAR and associated with multiple databases, such as, 1000 genome, dbSNP, HGMD, ClinVar.

## 9. Validation by Sanger Sequencing

The candidate variable sites were confirmed by Sanger sequencing for their parents. The target sequences were sequenced on ABI 3730 analyzer (Applied Biosystem). Sites of variation were identified through a comparison of DNA sequences with the corresponding Gen Bank reference sequences using the Mutation Surveyor software.

## 10. Protein function prediction

In silico analysis was performed in order to better understand the

possible protein defects generated by the mutation. Three different software programs were used: Mutation Taster, Maxent Scan, Human splicing finder.

## 11. Whole exome sequencing result

we identified a novel c.1270+2T> C homozygous splice site mutation in intron 8 of the  $\beta$  subunit gene of ENaC and the mutation was a splicing mutation. Sanger sequencing was used to verify the mutation in the patient and the parents. The parents showed heterozygosity for this mutation. According to the guidelines of the American Society of Medical Genetics and Genomics (ASMG) in 2015, a splicing mutation is a likely pathogenic mutation (Figure 1).

## 12. Protein function prediction result

The mutation c.1270+2T> C generated a splicing mutation probably leading to the loss of the gene function. The results of the protein function prediction using software Mutation Taster, Maxent Scan, Human splicing finder were pathogenic, pathogenic and pathogenic, respectively.

## 13. Literature retrieval results

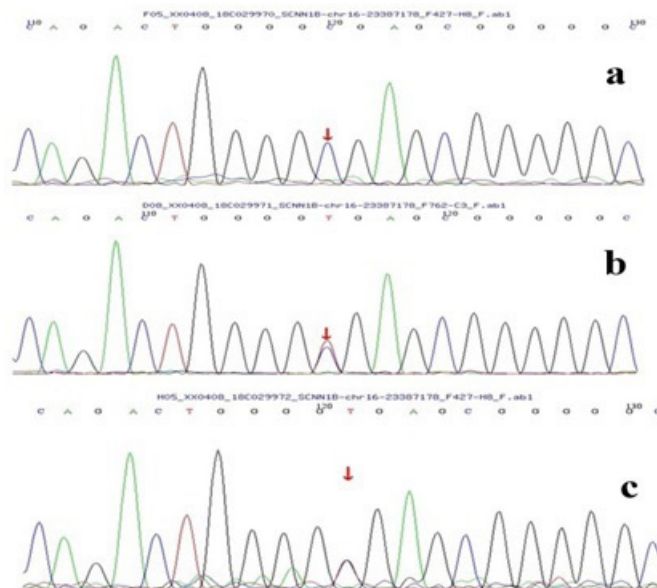
With "multi-system pseudohypoaldosteronism type 1""ENaC" and "SCNN1B" as the search words, data were retrieved from PubMed, ClinVar, Online Mendelian Inheritance in Man (OMIM), Human Gene Mutation Database (HGMD), Wan Fang databases and China National Knowledge Infrastructure before November 2020. A total of eight literatures reported this syndrome. The homozygous mutation of SCNN1B (c.1270+2T>C) in the present case has not been reported in the abovementioned databases. The mutations and clinical features of sPHA1 caused by SCNN1B mutations in literatures are summarized in Table 2.

sPHA1 is an autosomal recessive inherited disease, which is caused by mutations in the ENaC gene subtypes, that encodes ENaC located in lung, sweat glands, kidney and colon. Therefore, it presents systemic symptoms such as severe dehydration, respiratory symptoms in newborns, gallstone, failure to thrive, skin infection and dermatitis (Chang et al., 1999; Furgeson & Linas, 2010) [11, 12]. ENaC is a trimer composed of  $\alpha$ ,  $\beta$  and  $\gamma$  subunits and  $\alpha$  subunits is mainly involved in sodium transport, while  $\beta$  and  $\gamma$  subunits participate in the regulation of transcellular fluid. Each ENaC subunit consists of two transmembrane segments, one is extracellular domain, the other is intracellular N-terminal and C-terminal domain. The ENaC is encoded by genes SCNN1A (sodium channel epithelial 1 alpha subunit, OMIM No. 600228, 12p13.31), SCNN1B (sodium channel epithelial 1 beta subunit, OMIM No. 600760, 16p12.2), and SCNN1G (sodium channel epithelial 1 gamma subunit, OMIM No. 600761, 16p13.1) (Hanukoglu & Hanukoglu, 2016) [13]. The three SCNN1 genes have 13 exons. Exon 2 encodes the N-terminal domain, exon 13 encodes the C-terminal domain and exon 3-12 encodes the extracellular domain of

the protein, in addition, the absence of exons 3-10 and 12 causes function channels not to be expressed (Chang et al.,1999) [11]. Most of the mutations detected in sPHA1 are nonsense, insertion or single-base deletion leading to frameshift or splicing site mutation, which cause truncated ENaC channel protein. Although some patients with PHA1 have previously been reported, most of the reported mutations occur in  $\alpha$ -EnaC subunit, nevertheless,  $\beta$ - and  $\gamma$ -EnaC mutations are rarely described. As far as we know, 14 mutations of  $\beta$ -ENaC gene have been published and this mutation has not been reported in literature until now.

In 2002 Christie et al. reported a 4-day- old male patient with marked dehydration, metabolic acidosis, hyponatremia and severe hyperkalemia. While, their study confirm that patient has a homozygous deletion mutation that includes the 5'end of SCNN1B that is at least 1,300 bp in length. In 2012 Cagla et al reported a 3-day-old male patient with poor feeding, vomiting, lethargy and severe dehydration. The birth history is normal and his parents and siblings were healthy. Molecular genetic analysis identified a novel c.1266-1G>C homozygous splice site mutation in intron 8 of the SCNN1B gene. The patient's parents are carriers. In 2016 Yael et al reported a 32-year-old female who experienced severe body aches, with pain limiting her motion and no relief to multiple analgesic medications. She also noted heart palpitations and frequent episodes of hidradenitis suppurativa. The patient had a his-

tory of multi-organ dysfunction at 2–3 weeks of age and recurrent episodes of chronic bronchitis during childhood. Genetic analysis revealed the presence of two novel heterozygous mutations in the SCNN1B gene: c.1288delC, a one-base deletion that generates a frameshift mutation, and c.1466+1G>A, an intronic base substitution that leads to a splice site mutation. In 2018 Atilla et al reported a 9-day-old male patient with vomiting, discomfort, poor feeding and skin rash. Though the family history was unremarkable, he was born to first cousin parents. Molecular genetic analysis revealed a novel compound heterozygous [c.87C>A(p.Tyr29\*)/c.1346+1G>A] mutation in the SCNN1B gene. The variants were inherited from the unaffected parents (the mother was heterozygote for c.87C>A(p.Tyr29\*), while the father was heterozygote for c.1346+1G>A variants). In 2019 Yang et al reported a 4-year-old girl with recurrent shock, electrolyte imbalance, rash, pneumonia for 4 years. The results of gene sequencing showed that there was a c.118C>T missense mutation in the exon2 and a c.776+1G>A missense mutation in the 4 intron of the SCNN1B gene. All patients had typical clinical and laboratory characteristics, including poor eating, vomiting, dehydration, weight loss, polyuria, diarrhea, growth retardation, recurrent pulmonary infection, dermatitis and life-threatening hyperkalemia, hyponatremia, metabolic acidosis. The Analysis of more SCNN1B mutations involved sPHA1, especially, the establishment of a correlation between genotype and phenotype, should contribute to a better understand the disease.



- (a) A homozygous mutation (c.1270+2T>C) in *SCNN1B* was detected in the child.  
 (b) heterozygous mutation in *SCNN1B* were detected in the father of the child.  
 (c) heterozygous mutation in *SCNN1B* were detected in the mother of the child.

**Table2** The mutations and clinical features of sPHA1 caused by *SCNN1B* mutations in literatures

Patient	1	2	3	4	5	6	7	8	9	10
Gender	M	M	F	F	M	F	M	F	M	M
Birth(B)	Term	Term	n/a	31+4 weeks	Term	n/a	n/a	Term	n/a	Term
B.weight(kg)	2.9	3	n/a	2.17	3.2	n/a	n/a	n/a	n/a	3.3
consanguinity	Yes	No	n/a	Yes	Yes	n/a	n/a	No	No	Yes
Day of onset	9	2	14-21	1	8	n/a	n/a	7	42	4
Genetics	Compound heterozygous Nonsense/splice site [c.87C>A(p.Tyr29*)]/[c.1346+1G>A (IVS9+1G>A)]	homozygous splice site mutation in intron 8 (c.1266-1G >C)	Compound heterozygous frameshift/splice site mutation (c.1288delC /c.1466+1G >A)	Donor splice site mutation in intron 12 (c.1542 +1G > A)	17-bp frame shift deletion in exon 2	Compound heterozygous, insertion/deletion mutation (647insA, T216 fs)/(915delC, D305 fs)	Homozygous missense mutation (G37S)	missense mutation in exon2 and intron 4 (c.118C>T)/(c.776+1G>A)	homozygous mutation of G to A in the first nucleotide at the 5'-splice site of intron 12	a large homozygous deletion (> 1300 bp) in the 5' end of the gene
Sodium (mmol/l)	106	125	135	128	113	n/a	n/a	123.3	118	127
Potassium (mmol/l)	11.8	9	5.1	7.8	11	n/a	n/a	9.92	10.2	10.2
Aldosterone (pg/ml)	3173	946	2800	1795	16650	n/a	n/a	5698.93	>40000	1281
PRA(ng/ml)	98.2	140	190	n/a	n/a	n/a	n/a	19.07	n/a	235.5
Ongoing management	Died at 6 months of age due to salt wasting crisis	NaCl (1.5 g/kg/day) and sodium polystyrene sulfonate (1.5 g/kg/day)	Sodium polystyrene sulfonate (60 ml/day), NaCl (3 g/day) and sodium bicarbonate (950mg/day)	NaCl (22 mmol/kg/d), NaHCO <sub>3</sub> (3 mmol/kg/d), sodium resonium (236 mg/kg/d)	NaCl (6.6 mmol/kg/d), NaHCO <sub>3</sub> (3.5 mmol/kg/d), sodium resonium (500 mg/kg/d)	n/a	n/a	NaCl (1-1.5 g/kg/day) and sodium polystyrene sulfonate	At the age of 6.5 yr he died after cardiac arrest at home	n/a
Literatures	Cayir et al.(2019)	Dogan et al.(2012)	Nobel et al.(2016)	Gopal Kothandapani et al.(2019)	Gopal Kothandapani et al.(2019)	Ekerem et al.(1999)	Gründer et al.(1997)	Hanhua et al.(2019)	Saxena et al.(2002)	Thomas et al.(2002)

In this study, we describe one patient with genetically confirmed sPHA1, which was caused by the mutation of *SCNN1B* gene. This patient has the typical clinical and laboratory features of sPHA1: (1) born with normal pregnancy and normal Apgar score; (2) dyspneic and decreased activity occurred within the first week of life, accompanied by severe dehydration, hyperkalemia, hyponatremia and acidosis; (3) obvious evidence of renal salt loss, but with high levels of aldosterone and renin; (4) successful management of the abnormal metabolism with supplemental NaCl and potassium exchange resins and no improvement in clinical and laboratory results with hydrocortisone and fludrocortisone therapy; (5) Recurrent respiratory diseases in the first year of life. Furthermore, this patient with high serum cortisol level at the initial stage, we reason that hypercortisolism was caused by two mechanisms including aldosterone and cortisol co-secretion and stress response of adrenal gland in critical stage. Mutation Characteristics Molecular genetic analysis of this case revealed a novel homozygous [c.1270+2T>C] mutation in the *SCNN1B* gene. The variants were inherited from the unaffected parents (the parents was heterozygote for c.1270+2T>C). The c.1270+2T>C, an intronic base sub-

stitution located in intron 8, leads to a splice site mutation. According to the ASMG guidelines, the mutation was preliminarily identified as a pathogenic mutation. The mutation meets the criteria for identification as a pathogenic mutation, including PVS1 and PM2. PVS1: The mutation was a zero effect mutation (splicingmutation), which may lead to loss of gene function. PM2: The frequency in the normal population database was negative, and the mutation was a low frequency mutation. The variant has not been previously reported or published in the literature or listed in HGMD and Clinvar database. The mutation probably alters the wild-type splice donor leading to the loss of the domains. Based on the clinical and genetic findings, a diagnosis of sPHA1 was confirmed.

In conclusion, we identified a novel splice site mutation of the *SCNN1B* gene in a Chinese patient with sPHA1. The case presented in this report will expand the mutation database and the literature review may provide a better understand the underlying molecular genetics and phenotype-genotype relationship in sPHA1 caused by *SCNN1B* gene.

## 14. Acknowledgments

This work was supported in part by the National Natural Science Foundation of China (No. 81170762).

## References

- Casas Alba D, Cots JV, Carretero LM, Sampol LM, Zennaro M, Jeunemaitre X, et al. Pseudohypoaldosteronism types I and II: little more than a name in common. *J Pediatr Endocrinol Metab.* 2017; 30: 597-601.
- Amin N, Alvi NS, Barth JH, Field HP, Finlay E, Tyerman T, et al. Pseudohypoaldosteronism type 1: clinical features and management in infancy. *Endocrinol Diabetes Metab.* 2013; 130010.
- Gopal-Kothandapani JS, Doshi AB, Smith K, Christian M, Mushtaq T, Banerjee I, et al. Phenotypic diversity and correlation with the genotypes of pseudohypoaldosteronism type 1. *J Pediatr Endocrinol Metab.* 2019; 32: 959-67.
- Bonny O, Knoers N, Monnens L, Rossier BC. A novel mutation of the epithelial Na<sup>+</sup> channel causes type 1 pseudohypoaldosteronism. *Pediatr Nephrol.* 2002;17: 804-8.
- Strautnieks SS, Thompson RJ, Hanukoglu A, Dillon MJ, Hanukoglu I, Kuhnle U, et al. Localisation of pseudohypoaldosteronism genes to chromosome 16p12.2-13.11 and 12p13.1-pter by homozygosity mapping. *Hum Mol Genet.* 1996; 5: 293-9.
- Wang J, Yu T, Yin L, Li J, Yu L, Shen Y, et al. Novel mutations in the SCNN1A gene causing Pseudohypoaldosteronism type 1. *PloS One.* 2013; 8: e65676.
- Tajima t, Morikawa S, Nakamura A. Clinical features and molecular basis of pseudohypoaldosteronism type 1. *Clin Pediatr Endocrinol.* 2017; 26: 109-17.
- Kino T, Chrousos GP. Glucocorticoid and mineralocorticoid resistance/hypersensitivity syndromes. *J Endocrinol.* 2001; 169: 437-45.
- Adachi M, Tachibana K, Asakura Y, Abe S, Nakae J, Tajima T, et al. (2001). Compound heterozygous mutations in the gamma subunit gene of ENaC (1627delG and 1570-1G-->A) in one sporadic Japanese patient with a systemic form of pseudohypoaldosteronism type 1. *J Clin Endocrinol Metab.* 2001; 86: 9-12.
- Nobel YR, Lodish MB, Raygada M, Rivero JD, Faucz FR, Abraham SB, et al. Pseudohypoaldosteronism type 1 due to novel variants of SCNN1B gene. *Endocrinol Diabetes Metab Case Rep.* 2016;150104.
- Chang SS, Grunder S, Hanukoglu A, Rosler A, Mathew PM, Hanukoglu I, et al. Mutations in subunits of the epithelial sodium channel cause salt wasting with hyperkalaemic acidosis, pseudohypoaldosteronism type 1. *Nat Genet.* 1996; 12: 248-53.
- Furgeson SB, Linas S. Mechanisms of type I and type II pseudohypoaldosteronism. *J Am Soc Nephrol.* 2010; 21: 1842-5.
- Hanukoglu I, Hanukoglu A. Epithelial sodium channel (ENaC) family: Phylogeny, structure-function, tissue distribution, and associated inherited diseases. *Gene.* 2016; 579: 95-132.
- Cayir A, Demirelli Y, Yildiz D, Kahveci H, Yarali O, Kurnaz E, et al. Systemic Pseudohypoaldosteronism Type 1 due to 3 Novel Mutations in SCNN1A and SCNN1B Genes. *Horm Res Paediatr.* 2019; 91: 175-85.
- Dogan CS, Erdem D, Mesut P, Merve A, Sema A, Iffet B, et al. A novel splice site mutation of the beta subunit gene of epithelial sodium channel (ENaC) in one Turkish patient with a systemic form of pseudohypoaldosteronism Type 1. *J Pediatr Endocrinol Metab.* 2012; 25: 1035-9.
- Ekerem E, Bistrizter T, Hanukoglu A, Hofmann T, Zhou Z, Bennett W et al. Pulmonary epithelial sodium-channel dysfunction and excess airway liquid in pseudohypoaldosteronism. *N Engl J Med.* 1999; 341: 156-62.
- Grunder S, Firsov D, Chang SS, Jaege NF, Gautschi I, Schild L, et al. A mutation causing pseudohypoaldosteronism type 1 identifies a conserved glycine that is involved in the gating of the epithelial sodium channel. *EMBO J.* 1997; 16: 899-907.
- Hanhua Y, Lihua W, Lichun X, Qingping L, Lian M. Systemic Pseudohypoaldosteronism type 1 caused by new mutation of SCNN1B gene and literature review. *J Clin Pediatr.* 2019; 37: 605-8.
- Saxena A, Hanukoglu I, Saxena D, Thompson RJ, Gardiner RM, Hanukoglu A. Novel mutations responsible for autosomal recessive multisystem pseudohypoaldosteronism and sequence variants in epithelial sodium channel alpha-, beta-, and gamma-subunit genes. *J Clin Endocrinol Metab.* 2002; 87: 3344-50.
- Thomas CP, Zhou J, Liu KZ, Mick VE, MacLaughlin E, Knowles M. Systemic pseudohypoaldosteronism from deletion of the promoter region of the human Beta epithelial na(+) channel subunit. *Am J Respir Cell Mol Biol.* 2002; 27: 314-9.