

The Intra and Extra Cranial Veins in Relationship with Chronic Migraine: Electroencephalogram Modifications Induced by Balloon Venoplasty

Onorati P^{1,2*}, Toma G^{1,2}, Lupattelli T¹ and Bellagamba G¹

¹Istituto Clinico Casalpallocco GVM Sanità, Roma, Italy

²Dip. Di Fisiologia e Farmacologia “V. Erspamer” Università Degli Studi di Roma - La Sapienza, Italy

* Corresponding author:

Paolo Onorati,
Department of Physiology and Pharmacology,
University of Rome “La Sapienza”, P.le Aldo
Moro, 5, 00185, Rome, Italy,
E-mail: paolo.onorati@uniroma1.it

Received: 05 Mar 2021

Accepted: 24 Mar 2021

Published: 29 Mar 2021

Copyright:

©2021 Onorati P et al., This is an open access article distributed under the terms of the Creative Commons Attribution License, which permits unrestricted use, distribution, and build upon your work non-commercially.

Citation:

Onorati P. The Intra and Extra Cranial Veins in Relationship with Chronic Migraine: Electroencephalogram Modifications Induced by Balloon Venoplasty. *Ann Clin Med Case Rep.* 2021; V6(8): 1-8

Keywords:

EEG; Magnetic resonance imaging; Physiology;
Vascular surgery; Venous flow

1. Abstract

1.1. Objectives: Chronic Migraine (CM) is characterized by recurrent head pain often associated with electroencephalogram (EEG) abnormalities and asymmetry of intracranial venous circulation.

Migraine is a symptom of the Chronic Cerebrospinal Venous Insufficiency (CCSVI).

1.2. Methods: Seven persons with CCSVI and CM, associated or not with other symptoms, underwent Percutaneous Transluminal Angioplasty (PTA) of Internal Jugular Veins (IJVs), performed an intracranial Magnetic Resonance Imaging venography and/or Echo-Colour Doppler (ECD) of IJVs, seven an EEG before and five after PTA. A Pain Scale Assessment for CM was sampled before and after PTA.

1.3. Results: Seven patients show a blood flow improvement of the JVs after PTA.

Before PTA, seven persons showed EEG alterations, after PTA five also showed an improvement of the EEG and all seven showed an improvement in the pain score.

1.4. Conclusions: these preliminary observations suggest a strong association between CM, intra and extra cranial venous anomalies and EEG alterations.

2. Introduction

Migraine is a common disabling primary headache disorder. Previous epidemiological researches documented the prevalence of

socio-economic and personal impacts of Chronic Migraine (CM). In the Global Burden of Disease Study (GBD 2015) [1], CM was ranked the third-highest cause of disability worldwide in both males and females under the age of 50 years. Migraine has two major types: i) migraine without aura, a clinical syndrome characterized by headache with specific features and associated symptoms; ii) migraine with aura, primarily characterized by the transient focal neurological symptoms that usually precede or sometimes accompany the headache. Some patients also experience a prodromal phase, occurring hours or days before the headache, and/or a postdromal phase following headache resolution. Prodromal and postdromal symptoms include hyperactivity, hypoactivity, depression, cravings for particular foods, repetitive yawning, fatigue and neck stiffness and/or pain. Very frequent migraine attacks are defined as CM (HIS 2018) [2].

Migraine is one of the main symptoms of the Chronic Cerebrospinal Venous Insufficiency (CCSVI) that is a syndrome characterized by stenosis of the internal jugular veins (IJVs), with opening of collaterals and insufficient drainage, proved by reduced cerebral blood flow and increased mean transit time in cerebral MRI perfusion studies (Zamboni P et al, 2010) [3].

The Echo-Colour Doppler (ECD) is an ideal tool for assessing cerebral venous return. Given the influence of posture on venous outflow, ECD permits to turn rapidly the subject with the help of a tilt chair during the acquisition of data. The different significance

of the gravitational gradient in ensuring venous return requires investigating the subject with the head, respectively, either at 90° or at 0° (Van den Berg PJ et al, 2012) [4].

Advanced magnetic resonance venographic techniques used in strictly selected subjects disclose Transverse Sinus (TS) asymmetries in many patients with CM, even when mild differences in physiological calibre is excluded (Fofi L et al, 2012; Utriainen D et al, 2012) [5, 6].

To identify the frequency and features of altered TS morphology in CM, we enrolled consecutively patients with CM who fulfilled the diagnostic criteria for headache and acquired TS images with a 3-dimensional MR scanner.

Several authors have reported electroencephalographic abnormalities in migraine during last decades (Sand T., 1991) [7], moreover a recent research used electroencephalogram as a biomarker of brain human health.

We developed a qualitative analysis based on the observation of rest EEG pattern recorded in persons with CM.

This retrospective study arises from the observation of the frequent association between anomalies the intra and extracranial venous circulation and the chronic migraine, with or without aura (Petolicchio B et al, 2016) [8], which improves or regresses after venous angioplasty for CCSVI.

From 2013 to 2019, thirty consecutively persons diagnosed with CCSVI and CM were examined; seven of these underwent jugular balloon Percutaneous Transluminal Angioplasty (PTA) (Lupattelli T. et al, 2013) [9].

3. Methods

3.1. Subjects Clinical Pictures

The study received Institutional Review Board approval and all participants gave their informed consent. All persons were treated in an outpatient basis by a single team made up of neurologist and vascular surgeons (Brain Flow Team). The same physician performed all interventions at the same Institute.

From 2013 to 2019, thirty persons were examined (13 males, 17 females, mean age 43 ys, SD \pm 18.57) diagnosed with CCSVI and CM, seven of these underwent jugular balloon angioplasty. Fifteen performed an intracranial MRI venography and an ECD (Menegatti E et al, 2017) [10] of the IJVs (Zamboni P, 2014) [11] resulting positive for venous anomalies and stenosis; eleven performed an intracranial MRI venography with positive results for venous anomalies; four performed ECD of IJVs, resulting positive for stenosis. Of the people observed, twenty-three are in medical-treatment, and seven underwent jugular balloon angioplasty for CCSVI.

Clinical, venographic, and EEG data have been used in the study of the seven patients who underwent PTA in the Istituto Clinico Casalpallocco (ICC) in Rome.

All data acquisitions have been performed as part of a normal clinical practice protocol and each participant has filled in the informed consent, according to the World Medical Association Code of Medical Ethics (Declaration of Helsinki) and the Institutional Code of Ethics.

All participants have consented to the use of biometric data acquired in the form and manner established by this retrospective cohort study.

The data of this study have been recorded on seven patients (15 to 59 years old) with CCSVI and CM, in particular:

3.1.1. Person 1:

Man 42-year-old, comes to visit for CM diagnosis in the ophthalmic region, matched with Endocranial Hypertension; an angio-MRI revealed moderate stenosis of the right transverse sinus. In July 2017, a previous intracranial angiography and phlebography was carried out which showed "stenosis of the internal jugular vein at C1 level".

An Echo Colour Doppler of the jugular veins revealed alteration of the venous circulation with increased flow velocity in the sitting position. In J1, bilaterally, we observe the blocked flow and sometimes reflux, no acceleration, and the level of stuck leaflets in J1. The valve motility was quite always reduced. We have not recorded the peak velocity.

3.1.2. Person 2:

Adolescent male 17-year-old comes to visit for diagnosis of CM and Cyclical Vomiting Syndrome. An Echo Colour Doppler of the jugular veins revealed alteration of the venous circulation with diagnosis of CCSVI.

Firts intervention of PTA of the jugular veins in February 2017 with significant improvement of the Cyclical Vomiting and CM symptoms (morning or, more rarely, nocturnal; very often linked to sporting activity).

After second PTA in 2018, migraine without aura was further reduced in frequency and intensity.

3.1.3. Person 3:

Woman 46-year-old comes to visit for diagnosis of CM with aura and diffuse rachis pains. Chronic Inflammatory Demyelinating Polyneuropathy (CIDP) was previously diagnosed.

Angio MRI showed a strong asymmetry of the intracranial venous circulation, with prevalence of flow at right (Fig 1), confirmed by an Echo Colour Doppler of the venous neck vessels.

3.1.4. Person 4:

Adolescent female 15-years-old, come to visit for diagnosis of CM and Cyclical Vomiting Syndrome

Episodes of "Projectile Vomiting" without nausea and a drug-resistant headache, every two months on average (in correspondence with the end of the ovarian cycle).

An encephalic MRI with angio-sequences did not show morphological alterations, but an echo- colour- doppler showed a strong asymmetry of the jugular circulation with stenosis.

3.1.5. Person 5:

Man 38-years-old, comes to visit for diagnosis of CM and Meniere's Syndrome. Diagnosis of CCSVI with flow blocked into right internal jugular vein.

Previous severe cranial traumatism with zygomatic and right temporal fracture.

3.1.6. Person 6:

Man 59-years-old, comes to visit for diagnosis of CM and CCSVI.

Angio MRI showed asymmetry of the intracranial venous circulation, with prevalence of flow at right, confirmed by an Echo Colour Doppler of the venous neck vessels.

3.1.7. Person 7

Woman 31-year-old comes to visit for diagnosis of CM and CCSVI.

Angio MRI showed asymmetry of the intracranial venous circulation, with prevalence of flow at left, confirmed by an Echo Colour Doppler of the venous neck vessels.

The inclusion criteria for subjects, who underwent PTA, have been the following: i) CM characterized by recurrent pain involving only one side of the head matched by nausea, vomiting, photo and / or phonophobia, present for at least 15 days / month for more than 3 months [2]; ii) CCSVI diagnosed by a combined route using extra cranial Echo-Colour Doppler (ECD) according to the Zamboni criteria. The adopted selection criteria were a) the blocked blood flow during inspiration, b) the presence of blood flow reflux, c) the frequent presence of abnormal aspect of jugular valve, always confirmed during angioplasty; iii) intracranial MRI venography with positive results for venous anomalies and/or asymmetries; iv) untreated patients or patients undergoing disease-modifying therapies unchanged for at least 6 months.

The exclusion criteria were: i) use of experimental drugs or participation in a clinical trial in the 3 months preceding the screening; ii) contraindications to venography: documented thrombophilia, previous adverse reactions after iodinated contrast medium administration or the presence of pathological conditions possibly conducting to reactions to the introduction of contrast medium, including severe renal, hepatic, or cardiac insufficiency, Wald Enstrom's macroglobulinemia or multiple myeloma; iii) contraindications to MRI and / or its contrast agent; (iv) haemoglobin values

≤ 9 g / dl, leukocytes $> 11,000$ / μ l, platelets $< 70,000$ / μ l; v) prothrombin time values, activated partial thromboplastin time, creatinine outside laboratory reference values; vi) monoclonal gammopathy or hypergammaglobulinemia ($> 21\%$); vii) history of congenital or ischemic heart disease, arrhythmias, conditions that can cause changes in motor and / or visual and / or cognitive

functions; viii) current or previous radiotherapy received for any reason.

We talk of stenosis looking at phlebography and during angioplasty classifying it in light, moderate and severe.

Before answering to your request of subtypes of CCSVI described in the analysis of the Brave Dreams, we'd like to inform that our philosophy from ten years is to have the presence of the medical ultra-sonographer in the theatre during angioplasty, to improve our knowledge and the ability of the diagnosis by means of this double observation. Until now we studied one thousand two hundred patients.

3.2. EEG Recordings (EEG)

EEG data were recorded on individuals in a resting state through 19 electrodes placed on the scalp, according to the international 10/20 system (electrodes: Fp1, Fp2, F7, F3, Fz, F4, F8, T3, C3, Cz, C4, T4, T5, P3, Pz, P4, T6, O1, O2, linked ears as reference). All data were digitized in continuous recording mode (5 min; 256 Hz sampling rate; eyes closed condition). All recordings have been acquired following the protocol of normal clinical practice for patients before and after PTA procedures.

3.3. Cognitive Assessment

Patients have been evaluated with the Mini Mental State Examination (Folstein MF et al, 1975) [12] before and not less than three-months after PTA.

3.4. Pain Scale Assessment for CM

Patients have been validated through the Numerical Rating Scale (Downie WW et al, 1978) [13] before and after PTA.

3.5. Eco-Colour Doppler Data

Expert sonographers acquired intravenous measurement data before and after PTA. For the evaluation of the IJV flow, an Esaote Vinco Myolab ultrasound scanner was used with probes suitable for the type of measurement to be carried out. The survey has been performed to estimate the proposed by Zamboni (Zamboni P et al, 2009b) [14].

3.6. Magnetic Resonance Imaging Data

Intracranial MRI venography was performed with a 3-dimensional MR scanner to detect venous anomaly/asymmetry.

3.7. EEG Data Evaluation

EEG data have been analysed as regards the recordings made before the PTA and three months later.

The ocular, muscular and instrumental artefacts have been previously identified and discarded by means of an automatic computerized procedure (our clinical neurophysiological procedure). Two experimenters independently analysed the EEG segments by expressing a judgment on the characteristic patterns of the signal and on the development of the basic rhythm. In the absence of an agreement in the evaluation, a new data analysis has been carried

out until a final judgment was reached by the examiners.

3.8. Percutaneous Transluminal Angioplasty

Left groin was preferred, when possible, and an 8 or 10 F, 12 cm long sheath (Terumo Medical Corporation, Elkton, Maryland) was introduced under local anaesthesia in the common femoral vein.

Venous puncture was carried out with a standard Seldinger technique. A 6F, 100 cm long, multipurpose catheter (Cordis Co., Miami, FL, USA) was selected first to cannulate both IJVs. The multipurpose catheter was also used for the AZ; in those cases where catheterization of the AZ proved difficult with the multipurpose catheter, a 5 F Cobra C1, 100 cm long (Cordis Co., Miami, FL, USA) was preferred.

Phlebography was carried out at different levels in the IJV in every patient. Specifically, 5 ml of diluted iodine contrast (Visipaque, Amersham Health AS, Oslo, Norway) were injected manually with the tip of the catheter placed 10 cm above the IJV outlet (J2 level) as well as 8-10 cm above it (J3 level).

Antero-posterior and ipsilateral anterior oblique views were obtained for both IJVs in all patients. Two views (left anterior oblique at 30 degree and lateral) were used to visualize the AZ. Angioplasty was carried out at the same time of phlebography. Prior to balloon dilatation the patients were given unfractionated heparin (70 U/Kg). A stenosis greater than 50% was considered the threshold for balloon dilatation. Stenoses and occlusions were treated using high pressure balloons (Conquest PTA Dilatation Catheter, Atlas PTA Balloon Dilatation Catheter; Bard Peripheral Vascular, Tempe, Arizona) and/or standard (low pressure) balloons (Admiral Xtreme™, Invatec, Bethlehem, PA, USA) either in the IJV and AZ. Angioplasty was terminated once all detectable lesions in the three target veins (left and right IJVs and AZ) were treated successfully or after three consecutive failing attempts at meliorating the blood flow through the injured vessel. Manual pressure on the groin was applied for a minimum of 10 minutes in all patients following removal of the introducer sheath. Afterwards, they were sent back to the ward with the recommendation to keep very still in the bed for at least two hours. After further two hours the patients could ambulate under strict observation and leave the hospital if they were clinically stable without any abnormalities of the vital signs.

Postoperative antithrombotic prophylaxis was scheduled as follow: 4000 U of low-molecular-weight heparin every 12 hour for 15 days, 100 mg of mesoglycan (Prisma, Mediolanum Farmaceutici, Milan, Italy) every 12 hour + 100 mg of aspirin daily for the following 3 months. Finally, aspirin 100 mg daily for the following 6 months (Lupattelli T. et al, 2013) [9].

The patients were visited at our Center or alternatively were contacted by phone or by e-mail at 7 and 30 days from the procedure. In case of procedure-related problems, the patients were invited to contact the hospital at any time. All the patients were scheduled to have both clinical and neurological evaluation as well as CDS of

the neck veins at 2, 6, 12 and 18 months at our center.

3.9. Percutaneous Transluminal Angioplasty Data Evaluation

In order to evaluate improvement of blood flow velocity from both the internal jugular veins, two independent experimenters counted the emptying frames recorded during the venography, carried out before and after percutaneous angioplasty. The blood flow variations from both the internal jugular veins were expressed in percentage terms.

In the absence of an agreement in the evaluation, a new data analysis has been carried out until both the examiners reached a final judgment.

4. Results

4.1. Patients and Surgery Outcomes:

Seven patients underwent PTA for CCSVI and CM; five of these patients were characterized by the association of these with other symptoms: one showed increased intracranial pressure, two showed cyclical vomiting, one showed CIDP, one showed Meniere's syndrome.

After PTA procedure, we recognized:

Person 1: improvement of blood flow velocity from the internal jugular veins (IJV left 35,7%, IJV right 19,2%).

Person 2: improvement in blood flow velocity from the internal jugular veins (IJV left 37.5%, IJV right 26.7%)

Person 3: improvement of blood flow velocity from the internal jugular veins (IJV left 30%, IJV right 20%).

Person 4: improvement of blood flow velocity from the internal jugular veins (IJV 23,3%).

Person 5: improvement of blood flow velocity from the internal jugular veins (IJV left 19,2%, IJV right 37,5%).

Person 6: improvement of blood flow velocity from the internal jugular veins (IJV left 26.4%, IJV right 14.3%).

Person 7: improvement of blood flow velocity from the internal jugular veins (IJV left 29.5%, IJV right 29%).

The seven patients show a systematic improvement in the emptying frames of the right and left jugular veins after the PTA intervention, with an average improvement of 28.8% for the JV left and 24.3% in the JV right. (Table 1)

4.2. Pain Score Numerical Rating Scale

Before PTA patients had a mean pain score of 7.7; six of the seven screened persons who underwent surgery, showed a mean pain score of 3.

Although the increased of blood flow from the internal jugular veins, person 1 did not show an improvement in pain.

4.3. Electroencephalogram

Five out of seven persons with chronic migraine, made a post-PTA

control EEG recording.

Except for those with CM and Meniere's syndrome, the patients undergone an EEG control after PTA showed an improvement in the cerebral alpha rhythm after surgery (Figure 2), in particular: i) three persons with CM and Cyclical Vomiting showed an improvement in the alpha rhythm, ii) the person 3 with CM and CIDP

showed an improvement in the alpha rhythm and the reduction of irritative pattern intermingled with the basic one.

The two persons (n.1 and n.6), who did not undergo the EEG control recording after surgery, showed a lower basal rhythm organization as a common element in pre-PTA recordings.

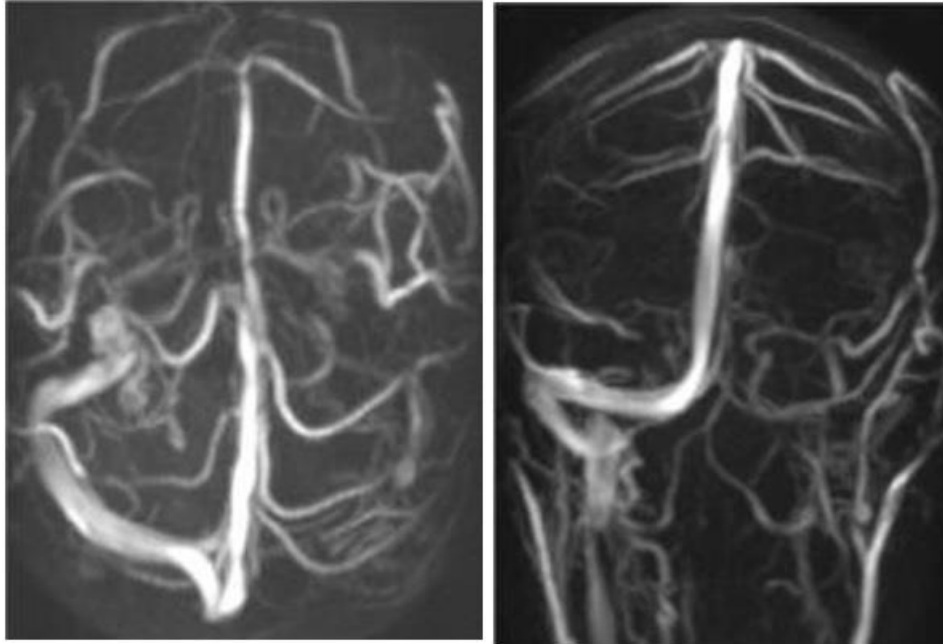


Figure 1: Person 3, Angio MRI showed asymmetry of the intracranial venous circulation, with prevalence of flow at right.

Table 1

NAME	% IMP J.L. POST PTA	% IMP. J.R POST PTA	DIAGNOSIS	NPRS pre PTA	NPRS post PTA	MMSE pre	MMSE post	EEG pre	EEG post
P1	35,7	19,2	CM + EH	7	4	30	30	α An.	N.P.
P2	37,5	26,7	CM+ CVS	8	2	30	30	α An.	α I.
P3	30	20	CM+ CIDP	8	2	30	30	α An.+IP	α I.+IP Red
P4	23,3	23,3	CM+ CVS	7	4	30	30	α An.	α I.
P5	19,2	37,5	CM+ MS	7	2	30	30	α An.	α I.
P6	26,4	14,3	CM	8	3	30	30	α An.	N.P.
P7	29,5	29,5	CM	9	4	30	30	α An.	α I.
Media	28.8	24.3		7,7	3	30	30		

IMP.J L and R= Improvement of jugular blood flow velocity at left and right; **CM=** Chronic Migraine; **EH=** Endocranic Hypertension; **CVS=** Cyclical Vomiting Syndrome; **MS=** Meniere Syndrome; **CIDP=** Chronic Inflammatory Demyelinating Polyneuropathy; **NPRS=** Numeric Pain Rating Scale; **MMSE=** Mini Mental State Examination; **EEG=** elettroencefalogram; **α An** = Alpha rythm Anomalies; **IP=** Irritative pattern; **α I** = Alpha Rhythm Improvement; **IP Red=** Irritative Pattern reduction; **N.P.=** Not Performed.

4.4. Mini Mental State Examination

All patients undergoing PTA showed no differences in the pre and post PTA raw MMSE score.

5. Discussion

A common agreement has been formed in recent years concerning the onset of pain in various form of migraine (Barbanti P et al, 2015) [15].

Previous in vivo studies (Ray BS et al, 1940; McNaughton FL et al, 1997) [16, 17] showed that intracranial structures were sensitive to mechanical and electrical stimuli. Those phenomena occur along the middle meningeal artery and the margins of the dural sinuses. The somatic innervations by the trigeminal is distinct from

those innervating intracranial structures resembling the viscerally originating pains referred to the somatic dermatomes. A “sterile inflammation” (Ramachandran R et al, 2018) [18] in the intracranial meninges, that occurs concomitantly with endogenous or exogenous factors such as chronic stress, diet, hormonal fluctuations, cortical spreading depression, results in the sensitization and activation of trigeminal meningeal nociceptors. The release of neuropeptides (i.e., such as substance P, calcitonin gene related peptide) from the trigeminal innervation, leads to vasodilation, plasma leakage, edema, and mast cell degranulation. This neurogenic inflammatory pattern has been observed and extensively studied in peripheral tissues as well as in the genesis and maintenance of migraine central pain (Tolner E.A. et al, 2019) [19].

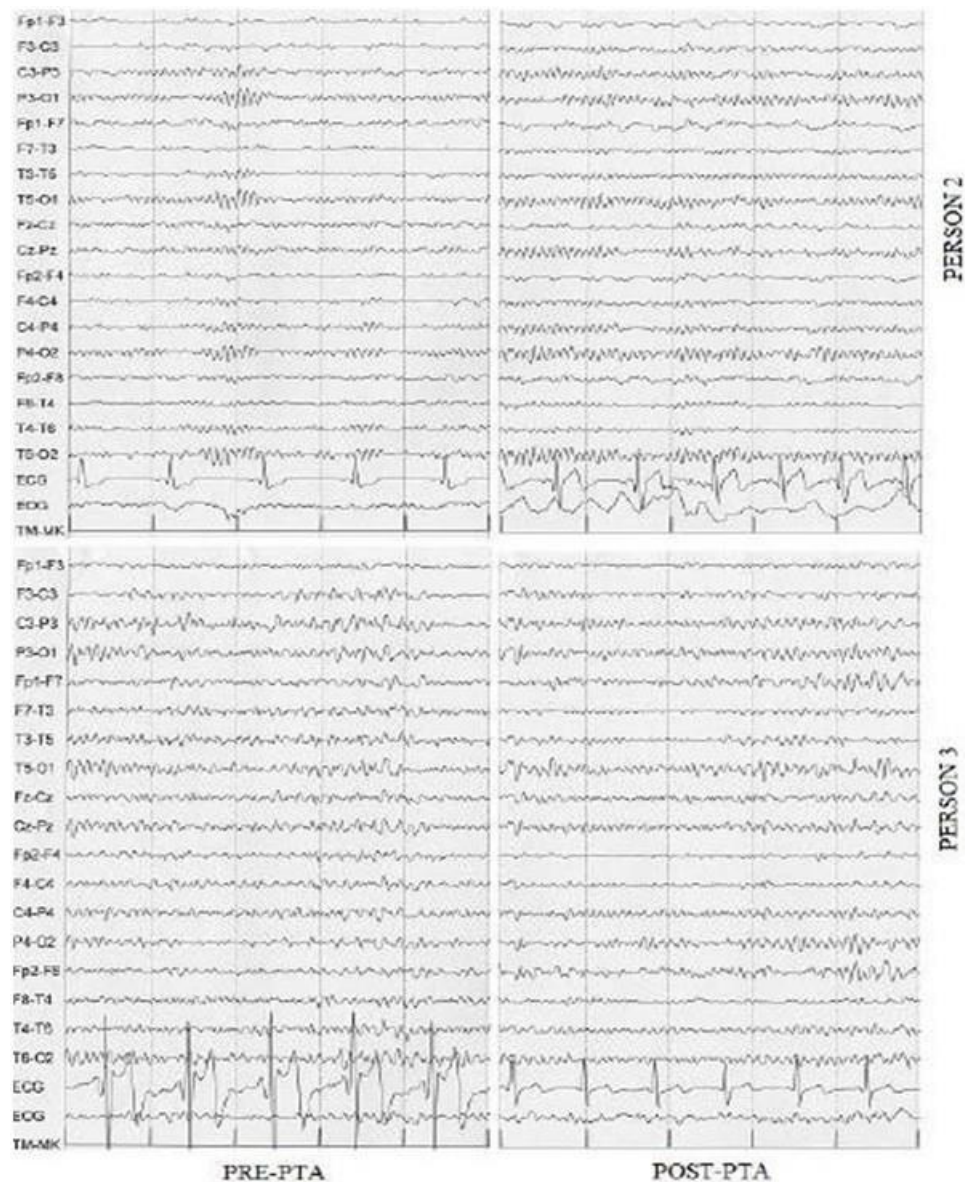


Figure 2: Person 2 diagnosis of CM and Cyclical Vomiting Syndrome; Person 3 diagnosis of CM with aura and Chronic Inflammatory Demyelinating Polyneuropathy (CIDP). The EEG recorders showed an improvement in the cerebral alpha rhythm after surgery in both patients. In the patient with CM and CIDP showed that was also a reduction of irritative pattern intermingled with the basic one.

Brain temperature is meanly correlated with circulating blood volume in the veins, with a 70–80% of the overall cerebral blood flow. Previous papers showed how brain physiology and pathophysiology are finely connected to changes in parenchymal temperature (Wang H. et al, 2014 and 2016) [20, 21]. We agree that Jugular PTA is a modulation of the autonomic nervous system, as described by Stemberg.

Our experience after more than two thousand PTA procedures of the jugular veins showed that almost all post-operated persons had a significant increase in skin temperature on the limbs in the two hours following the intervention.

It is possible to postulate that the center of thermoregulation in the hypothalamus plays a role in the genesis of this phenomenon. In

pre-operative phase, is possible to hypothesize a slight increase in the hypothalamic temperature determined by the reduced blood outflow from the brain. This condition would induce a stable increase in the difference between the temperatures of the skin and the brain; thus, a peripheral vasoconstriction would be established (as in the case of lower external ambient temperature). With PTA procedures of the jugular veins, a greater amount of blood would flow from the cerebral parenchyma towards the heart, causing a small decrease in central temperature. This would lead to peripheral vasodilation (as in the case of an increase in the external ambient temperature). This phenomenon could be determined by a variation in the set point value determined by the decrease/increased blood flow.

The increase of skin temperature after PTA of the JV could be considered an indirect proof of the increased brain temperature before vascular surgery.

Brain temperature fluctuations dramatically change neural function at multiple levels. An increase of temperature in the brain matter altered action potential generation, trans-membrane ionic transport, passive membrane properties, and modify terminal transmitter release and pre-synaptic uptake processes (Katz, B et al, 1965; Lee, J. C 2005) [22, 23].

These observations showed how much a dysregulation of the cerebral parenchymal temperature could be connected to an "aseptic inflammation".

This hypothesis arises from the "qualitative" consideration about the micro-circulatory alterations (Louveau A et al, 2018) [24] that could be triggered by the alterations of the central venous flow capable itself of increasing the parenchymal temperature, modifying not only neuronal functioning, but also the regulation of neuro-inflammatory and neuro-immune processes.

In this research, we use the electroencephalogram as a biomarker of brain function in people with CM. A previous research has used this non-invasive method to define the concept of brain health (Babiloni C, 2016) [25].

The mechanisms that regulate visceral brain pain are modulated by the same vasoactive mediators/substances that regulate the action of the cerebral immune system. In viral pathologies caused by retroviral agents (HIV) for example, the dysregulation of the immune system produces a significant reduction in the alpha basic rhythm [8]. Other clinical conditions, such as hepatitis C, chronic cerebro-vascular suffering, change the basic rhythm inducing strong alterations in brain electrogenesis, in some cases in a characteristic manner (personal observation). From these considerations, the need arises to use an instrument capable of measuring, with an optimal temporal resolution, changes in brain health; for this purpose, we found the electroencephalogram as the best clinical instrument.

Although the assessment carried out in this research is qualitative, given the small and heterogeneous group of people considered, we can notice the systematic improvement of pain along with the electrogenic brain re-modulation occurring after PTA of JV. In this case, it has not been possible to apply a quantified method for the evaluation and analysis of the electroencephalographic signal (quantified-EEG analysis) considering the small number of persons and the age variability of the sample. The experimental approach adopted, which deliberately does not consider all the methods currently used in the deblurring of electroencephalographic data, allows, however, to evaluate all the characteristics of cerebral electrogenesis for each individual subject

The qualitative analysis of electroencephalographic data shows a

global improvement in cerebral electrogenesis with an incremental variation of cerebral venous flow. Therefore, the decrease in cerebral venous outflow can be correlated with the onset of migraine and its chronicity.

More in-depth studies will be possible in the future by expanding the number of participants involved in the research, balancing them by sex, age and homogeneity of clinical pictures.

The evidences deriving from the analysis of the examined persons with CCSVI and CM suggest a strong degree of correlation between the onset of chronic migraine and the presence of anomalies or variants of the intra and extra cranial venous course. It should be remembered that part of the symptoms found in patients suffering from chronic migraine are part of the symptomatic procession described by Zamboni in the work concerning the description of CCSVI (Zamboni et al, 2009b) [3].

We found that a modification of the flow at the level of the can improve, as well to solve, the symptomatology of the patients with CM considered. The reduction of the flow in these cases could be determined by an asymmetry of the intracranial venous circulation as well as by the presence of stenosis at the jugular level or both. Moreover, the increase of the overall venous outflow by an average of 20-30% determines a significant symptomatic improvement.

This paper also provides important suggestions worthy of further study: persons with CCSVI, CM and Meniere's syndrome have found an overall improvement in all symptoms; the same type of improvement occurred in CCSVI and CM suffering from cyclical vomiting or CIDP.

In the last case, there was a significant reduction in the neurological symptomatology characteristic of this type of polyneuropathy, suggesting a possible interference between a dysregulation of the central venous circulation and the more complex mechanisms that regulate immunity at the level of the central and peripheral nervous system.

The emptying frames measuring technique, recorded during the venography carried out before and after percutaneous angioplasty, provides a powerful method of evaluating the effectiveness of the treatment itself, and gives us the chance of quantitatively correlating the variation of the flow with a series of biological parameters or biomarkers sampled during clinical evaluations.

Similarly, in a non-quantitative manner, as far as the electrogenesis of brain activity, is concerned a strong correlation arose between the improvement of pain symptomatology, measured by the NRS, and the jugular veins emptying index. It is also worth to note that non-invasive examinations such as Cerebral Magnetic Resonance Angiography and echo-colour-Doppler of the venous vessels of the neck can be a useful indication for a more invasive procedure such as venography, performed during interventional radiological procedures of jugular veins.

6. Conclusion

These preliminary observations suggest the hypothesis of a possible association between CM and intra and extra cranial venous variances and/or anomalies. In this research group of seven persons who underwent jugulars angioplasty, six had an improvement in their symptoms after PTA.

We could be able to postulate the existence of a mechanism that restoring the correct values of cerebral flow/temperature restores a physiological condition, with the reduction of inflammation, with the remission/improvement of the symptoms discussed so far.

The asymmetry of the cerebral circulation is not related to the onset of migraine symptoms,

but the presence of migraine is almost always concomitant to an asymmetry of the intracranial venous circulation (anatomical asymmetry of the transverse sinuses) as well as extracranial one (stenosis present at JV level).

Further studies will be needed, to verify the efficacy of jugular angioplasty as an additional therapy for CM.

Reference

1. GBD 2015 Mortality and Causes of Death Collaborators. Global, regional, and national life expectancy, all-cause mortality, and cause-specific mortality for 249 causes of death, 1980-2015: a systematic analysis for the Global Burden of Disease Study (GBD) 2015. *Lancet*. 2016; 388(10053):1459-1544.
2. Headache Classification Committee of the International Headache Society HIS. The International Classification of Headache Disorders, 3rd edition. *Cephalalgia*; 2018; 38: 1-211.
3. Zamboni P, Galeotti R. The chronic cerebrospinal venous insufficiency syndrome. *Phlebology*. 2010; 25(6):269-79
4. Van den Berg PJ, et al, Extra- and transcranial echo colour Doppler in the diagnosis of chronic cerebrospinal venous insufficiency. *Phlebology*. 2012; 27(1): 107-13.
5. Fofi L, Giugni E, Vadalà R, Vanacore N, Aurilia C, Egeo G, et al. Cerebral Transverse Sinus Morphology As Detected by MR Venography in Patients With Chronic Migraine. *Headache*. 2012; 52: 1254-1261.
6. Utriainen D, Feng W, Elias S, Latif Z, Hubbard D, Haacke EM. Using magnetic resonance imaging as a means to study chronic cerebral spinal venous insufficiency in multiple sclerosis patients. *Tech Vasc Interv Radiol*. 2012; 15(2): 101-12.
7. Sand T. EEG in migraine: a review of the literature, *Functional Neurol*. 1991; 6(1): 7-22.
8. Petolicchio B, Viganò A, Di Piero V. Cerebral venous hemodynamic abnormalities in episodic and chronic migraine, *Functional Neurology*. 2016; 31(2): 81-6.
9. Lupattelli T, Bellagamba G, Righi E, DonnaVD, Flaishman I, Fazlioli R, et al. Feasibility and safety of endovascular treatment for chronic cerebrospinal venous insufficiency in patients with multiple sclerosis. *J Vasc Surg*. 2013; 58(6): 1609-18.
10. Menegatti E, Tessari M, Vannini ME, et al. High-resolution M-mode evaluation of jugular vein valves in patients with neurological and neurosensory disorders, *Curr Neurovasc Res*. 2017; 14: 316-22.
11. Zamboni P. How to objectively assess jugular primary venous obstruction, *Veins and Lymphatics*. 2014; 3: 4195.
12. Folstein MF, Folstein SE, McHugh PR. "Mini-mental state". A practical method for grading the cognitive state of patients for the clinician, *J Psychiatr Res*. 1975; 12(3): 189-98.
13. Downie WW, Leatham PA, Rhind VM, Wright V, Branco JA, Anderson JA, Studies with pain rating scales, *Ann Rheum Dis*. 1978; 37(4): 378-81.
14. Zamboni P, Menegatti E, Weinstock-Guttman B, et al. The severity of chronic cerebrospinal venous insufficiency in patients with multiple sclerosis is related to altered cerebrospinal fluid dynamics. *Funct Neuro*. 2009; 124: 133-8.
15. Barbanti P, Aurilia C, Egeo G, Fofi L, Piroso S. Chronic migraine: treatability, refractoriness, pseudo-refractoriness, *J Headache Pain* 2015; 16(Suppl 1): A39.
16. Ray BS, Wolff HG. Experimental studies on headache: pain-sensitive structures of the head and their significance in headache, *Arch Surg*. 1940; 41: 813-56.
17. McNaughton FL, Feindel WH. Innervation of intracranial structures: a reappraisal in *Physiological Aspects of Clinical Neurology*, Oxford: Blackwell Scientific Publications. England. 1997; 270-93.
18. Ramachandran R, Neurogenic inflammation and its role in migraine, *Seminars in Immunopathology*. 2018; 40: 301-14.
19. Tolner EA, Chen S, Eikermann-Haerter K. Current understanding of cortical structure and function in migraine. *Cephalalgia* 2019; 39(13): 1683-169.
20. Wang H, et al. Brain temperature and its fundamental properties are view for clinical neuroscientists, *Frontiers in Neuroscience*. 2014; 8: 307.
21. Wang H, et al. Thermal Regulation of the Brain –An Anatomical and Physiological Review for Clinical Neuroscientists. *Frontiers in Neuroscience*. 2016; 9:528.
22. Katz B, Miledi R. The effect of temperature on the synaptic delay at the neuromuscular junction. *J. Physiol*. 1965; 181: 656-70.
23. Lee JC, Callaway JC and Foehring RC. Effects of temperature on calcium transients and Ca²⁺-dependent afterhyperpolarizations in neocortical pyramidal neurons, *J. Neurophysiol*. 2005; 93: 2012-2020.
24. Louveau A, Herz J, Alme MN, et al. CNS lymphatic drainage and neuro-inflammation are regulated by meningeal lymphatic vasculature, *Nat Neuroscience*. 2018; 21: 1380-91.
25. Babiloni C, Pennica A, Onorati P, Noce G, Cordone S, Muratori C, et al. Abnormal cortical sources of resting-state electroencephalographic rhythms in single treatment-naïve HIV individuals: A statistical z-score index, *Clin Neurophysiol*. 2016; 127: 1803-1812.