

A Novel Method of Laparoscopic Approach in a Giant Bladder Diverticulum with Renal Cell Carcinoma "Double Trouble"

Sarmukh S^{1*}, Azhar AH¹, Rahman MNG¹ and Kantha R²

¹Department of Surgery, University Sains Malaysia, Kubang Kerian, Kelantan Malaysia

²Department of Surgery, KPJ Rawang Specialist Hospital, Selangor, Malaysia

*Corresponding author:

Sarmukh Singh,
Department of Surgery, University Sains Malaysia,
Kubang Kerian, Kelantan Malaysia,
E-mail: sarmukh_rao@yahoo.com

Received: 24 Feb 2021

Accepted: 15 Mar 2021

Published: 20 Mar 2021

Copyright:

©2021 Sarmukh S et al., This is an open access article distributed under the terms of the Creative Commons Attribution License, which permits unrestricted use, distribution, and build upon your work non-commercially.

Citation:

Sarmukh S. A Novel Method of Laparoscopic Approach in a Giant Bladder Diverticulum with Renal Cell Carcinoma "Double Trouble". Ann Clin Med Case Rep. 2021; V6(4): 1-4

Keywords:

Giant vesical diverticulum; Extravesical diverticulectomy; Renal cell carcinoma

1. Abstract

Congenital diverticular are rare and caused from weakening of the bladder mucosa with the entire wall of the diverticulum. Giant vesical diverticulum are uncommon and total of 13 cases reported. The gold standard of treatment this bladder diverticulum is with extravesical diverticulectomy approach. We would like to report a case of renal cell carcinoma with concurrent giant bladder diverticulum. This will be the first case report on the laparoscopic extravesicle approach done concurrent in a renal malignancy patient who has proved to be safe, effective, and minimally invasive and therefore superior to open extravesical diverticulectomy which is the gold standard.

2. Introduction

Congenital diverticular are rare and caused from weakening of the bladder mucosa with the entire wall of the diverticulum. Giant vesical diverticulum is uncommon and total of 13 cases reported. A 76 years old Chinese gentleman presented with abdominal distention and lower urinary symptoms. CT renal 4 phases showed right RCC with large urinary bladder diverticulum. We would like to report a case of renal cell carcinoma with concurrent giant bladder diverticulum. This will be the first case report on the laparoscopic extravesicle approach done concurrently in a renal malignancy patient who has proved to be safe, effective, and minimally invasive and therefore superior to open extravesical diverticulectomy which is the gold standard (Figure 1).

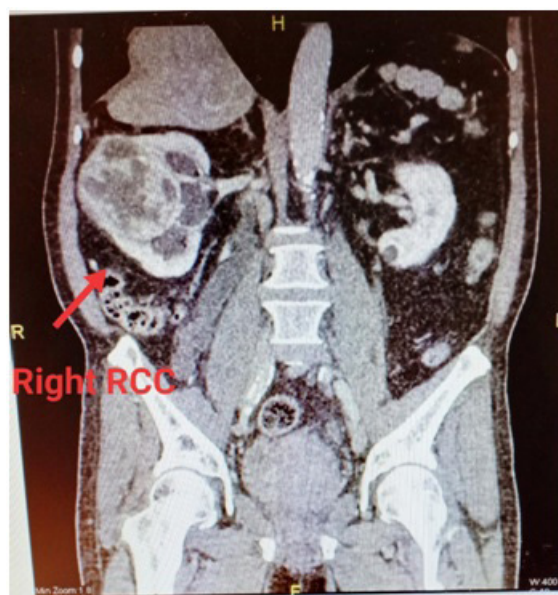


Figure 1: CT renal 4 phase showed a lobulated enhancing mass at interpole of right kidney measuring 8.8 x 6.6 x 8.6 cm suggestive of right renal cell carcinoma

3. Case Report

76 years old Chinese gentleman presented with abdominal distention and pain over the lower quadrant for past 5 months. Patient also had lower urinary symptoms. Per abdomen was distended with a vague mass over the right lower quadrant measuring 15cmx15cm, non tender, non pulsating. Digital rectal examination prostate was enlarged with median sulcus obliterated. No nodule or mass palpable. We proceeded with ultrasound abdomen and showed a highly

vascular right renal mass represents a renal cell carcinoma and a large urinary bladder diverticulum. CT renal 4 phase showed a lobulated enhancing mass at interpole of right kidney with a large well defined hypodense mass of fluid attenuation from superior urinary bladder suggestive of right RCC with giant urinary bladder diverticulum. We proceeded with laparoscopic right nephrectomy with diverticulectomy. The intraoperative finding was multiple nodules at right kidney, giant bladder diverticulum located at lateral part of the bladder wall. Patient had a speedy recovery and was discharge home with Continues bladder catheter after day 10 of post operative. The Histopathology result of bladder wall specimen shows consistent with diverticulum with no evidence of malignancy. The renal specimen shows clear cell renal cell carcinoma with Fuhrman nuclear Grade 2 T1b N0 M0 (Figure 2, 3).

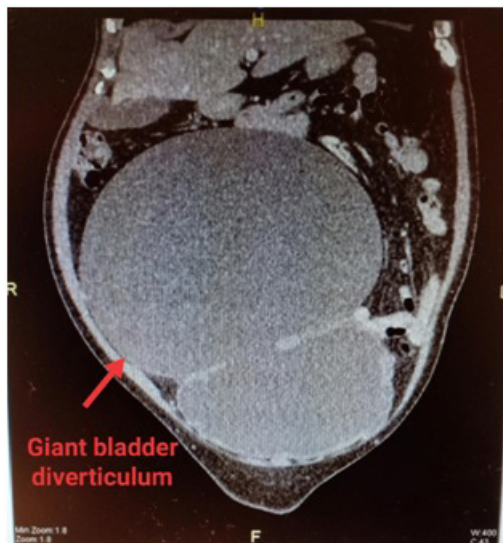


Figure 2: CT renal 4 phase shows a large well defined hypodense mass of fluid attenuation from superior urinary bladder, extend superiorly till L2 level measuring 15.6 x 22.4 x 18.2cm suggestive of giant urinary bladder diverticulum

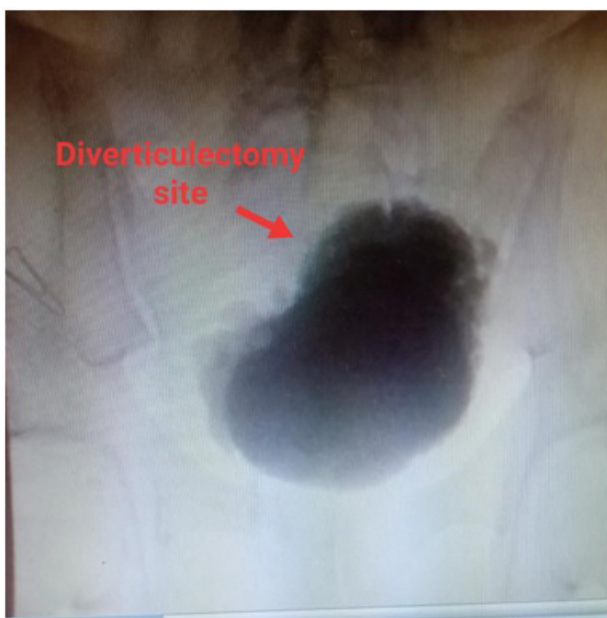

Figure 3: Postoperative Cystogram showed no evidence of contrast leakage from area of diverticulectomy.

4. Discussion

Congenital diverticula usually occur in areas where there is insufficient muscle, typically at the ureterovesical junction, or between bundles of hypertrophied muscle. They are usually asymptomatic and are discovered incidentally. Open extravesical diverticulectomy approach is the conventional surgery performed. However, we performed a laparoscopic transvesical diverticulectomy approach. We would like to describe the surgical approach for a giant vesical diverticulum with concurrent renal cell carcinoma. From our literature search we have found 13 cases of "giant bladder diverticulum". All this giant bladder diverticulum was operated with open extravesical diverticulectomy. We have summarized this 13 cases based on the characteristics such as initial presentation, diagnosis and treatment approach (Table 1).

We would like to discuss the various technique and approach which are available for giant bladder diverticulum. As for most urologists, surgical excision by mean of open surgical technique remains the most common treatment option. Open bladder diverticulectomy can be performed either extravesical, intravesical, or combination approach [14].

However, our patient we have chosen laparoscopic method over open surgery because this patient had right renal cell carcinoma which requiring nephrectomy. Laparoscopic bladder diverticulectomy represents a minimally invasive alternative to the open approach. It can be performed either transperitoneally or extraperitoneally. The principle for laparoscopic diverticulectomy is the same as for open diverticulectomy approach.

Laparoscopic transperitoneal technique for bladder diverticulectomy was described by Gill. This technique involves insertion of four or five transperitoneal laparoscopic ports. Followed by selective distension of the diverticulum. An incision at the peritoneum is made over the diverticulum. A circumscription of the neck and excision of the diverticulum at its ostium. The bladder is closed in two layers [15]. Meanwhile, Laparoscopic extra peritoneal technique for bladder diverticulectomy was first described by Nandler et al. in a patient with a 300 mL diverticulum. The principles of bladder diverticulectomy is the same as, described above. A 2 cm incision is made below the umbilicus, which was used to introduce the surgeon's finger. A self made dilating balloon catheter was used to create a retroperitoneal space. The dilating balloon was inflated with 1000 mL of normal saline to accomplish this. Four laparoscopic ports was then inserted. They dissected the diverticulum emanating just lateral the right ureteral orifice. Since then, only a few other cases using this technique have been reported [17-19].

We have choosen the extravescicle approach instead of intravesicle approach. This was because we wanted to avoid a separate cystotomy incision to inspect the bladder lumen. Beside that this was a renal cell carcinoma patient. This technique allows the urologist

to visualise directly the location of the neck of diverticulum within the bladder lumen. The extravescical approach was described by Nerli et al [20]. We used laparoscopic method to identify the bladder diverticulum. We then inserted a continious bladder drainage to collapse the diverticulum. The neck of diverticulum was identified. The laparoscopic cautery device was then used to score the extravescical surface to mark the site of the incision on the bladder. A circumferentially incision was made around the lesion with a 4-5 cm margin. Followed by making a full-thickness bladder incision using cautery. A complete excision of bladder pathology with a healthy margin of bladder wall is essential in order for a success operation. The advantages of this technique include the lack of a second cystotomy site thus requiring fewer bladder closures and less risk of post-operative urinary leak (Table 1).

However, beside the extravescical approach there is a the intravesical approach which was first described by Mariano and tefilli. They performed a small cystotomy which was made on the bladder dome. With the Foley catheter clamped, the pneumoperitoneum entered the bladder and rapidly distended it. The laparoscope and instruments could then be advanced into the distended bladder. Excision of the bladder lesion was then performed under direct vision through the cystotomy [21]. The advantage of this technique is its simplicity. The disadvantages of this approach was that creating a larger transverse cystotomy defect in order to insert several instruments. This cystotomy itself must be large enough to accommodate them. This may result in difficulty to close the wound and thus a higher risk or post-operative urine leakage.

Table 1: A summary of 13 cases of giant vesical diverticula from year 1957 to 2009.

Ref.	Yr	Age	Sex	Medical history	Initial symptom	Diagnosis	Management
Kauffman et al[4]	1957	70	M	Not available	Constipation	X-ray films, intravenous urography	Diverticulectomy
Taha et al [5]	1987	65 yr	M	Not available	Abdominal distension, slow stream of urine	Intravenous urography, CT	Reduction cystoplasty
Farhi et al [6]	1991	31 yr	F	Recurrent urinary infection	Ovarian cyst	USG, cystogram	Not available
Burrows et al [7]	1998	16 yr	M	EDS type 1	Outflow obstruction	Cystogram	Diverticulectomy
Suzuki et al [8]	2002	84 yr	M	Bladder injury with bullet	Abdominal distension	CT, cystogram	Diverticulectomy
Siddiqui et al [9]	2003	77 yr	M	TURP was performed twice because of urinary retention	Acute urinary retention	Intravenous urography	Diverticulectomy
Shukla et al [10]	2004	11 yr	F	EDS	Infection, incomplete voiding	Cystogram	Diverticulectomy
	2004	4 month	M	No medical	Decreasing urinary	Not available	Not available
	2004	3 yr	M	history of voiding dysfunction	stream and urinary retention	Not available	Not available
Mirow et al [11]	2007	84 yr	M	Sigmoid carcinoma	Abdominal pain, intestinal obstruction	Intraoperative	Diverticulectomy
Shaked et al [12]	2009	76 yr	M	Hypertension, diabetes mellitus	Abdominal pain, constipation	CT	Not available
Akbulut et al [13]	2009	57 yr	M	History of trauma	Abdominal pain, intestinal obstruction	CT	Diverticulectomy

CT: Computed tomography; EDS: Ehlers-Danlos syndrome; TUR-P: Transurethral prostatectomy; USG: Ultrasonography.

5. Conclusion

In our experience, this is the first case report on the laparoscopic extravescical approach was done concurrently in a renal malignancy patient which have proved to be safe, effective, and minimally invasive and therefore superior to open extravescical diverticulectomy which is still the gold standard.

Reference

1. Fox M, Bruce AW, RF Power. Diverticulum of the bladder-presentation and evaluation of treatment of 115 cases. Br J Uro.1962; 34:286-98.
2. McLean. Bladder diverticulum in the male. Brit. J. Urol.1968.
3. Melekos MD, Asbach HW, Barbalias GA. Vesical diverticula: etiology, diagnosis, tumorigenesis, and treatment. Analysis of 74 cases. Urology. 1987; 453-7.
4. Kaufman JJ, Mills H. Giant diverticulum of the bladder with gastrointestinal manifestations. Calif Med. 1957; 86: 331-3.
5. Taha SA, Satti MB, Mitry NF, Al-Idrissi HY, Ibrahim EM. Giant bladder diverticulum: an unusual presentation. Br J Uro. 1987; 59: 189-90.
6. Farhi J, Dicker D, Goldman JA., Giant diverticulum of the bladder

- simulating ovarian cyst. *Int J Gynaecol Obstet.* 1991; 36: 55-7.
7. Burrows NP, Monk BE, Harrison JB, Pope FM. Giant bladder diverticulum in Ehlers-Danlos syndrome type I causing outflow obstruction. *Clin Exp Dermatol.* 1998; 23:109-12.
 8. Suzuki K, Tanaka O, Saito T, Tokue A. Giant bladder diverticulum due to previous bullet injury: findings of gadolinium-enhanced magnetic resonance imaging. *Int J Urol.* 2002; 9: 517-19.
 9. Siddiqui K, Bredin HC. Giant bladder diverticulum causing recurring urinary retention. *Ir Med J.* 2003; 96: 247.
 10. Shukla AR, Bellah RA, Canning DA, Carr MC, Snyder HM, Zderic SA. Giant bladder diverticula causing bladder outlet obstruction in children. *J Urol.* 2004; 172: 1977-79.
 11. Mirow L, Brügge A, Fischer F, Roblick UJ, Durek C, Bürk C, et al. Bruch HP. Giant bladder diverticulum as a rare cause of intestinal obstruction: report of a case. *Surg Today.* 2007; 37: 702-3.
 12. Shaked G, Czeiger D. Distended urinary bladder and diverticulum-a rare cause of large-bowel obstruction. *Am J Surg.* 2009; 197: 23-4.
 13. Akbulut S, Cakabay C, Sezgin A, Senol A. Giant vesical diverticulum: A rare cause of defecation disturbance. *World J Gastroenterol.* 2009; 15: 3957-9.
 14. Clayman RV, Shahin S, Reddy P, Fraley EE. Transurethral treatment of bladder diverticula. Alternative to open diverticulectomy. *Urology.* 1984; 23: 573-7.
 15. Gill IS. Chapter 79 - Laparoscopic Surgery of the Urinary Bladder. In: *Campbell-Walsh Urology*, 9th Edition, 9 ed. Edited by A. J. Wein. Philadelphia: Saunders Elsevier, vol. 3, 2007.
 16. Porpiglia F, Tarabuzzi R, Cossu M, Vocca F, Terrone C, Fiori C, et al. Is laparoscopic bladder diverticulectomy after transurethral resection of the prostate safe and effective? Comparison with open surgery. *J Endourol.* 2004; 18: 73-6.
 17. Fukatsu A, Okamura K, Nishimura T, Ono Y, Ohshima. [Laparoscopic extraperitoneal bladder diverticulectomy: an initial case report]. *Nippon Hinyokika Gakkai Zasshi.* 2001; 92: 636-9.
 18. Shah HN, Shah RH, Hegde SS, Shah JN, Bansal MB. Sequential holmium laser enucleation of the prostate and laparoscopic extraperitoneal bladder diverticulectomy: initial experience and review of literature. *J Endourol.* 2006; 20: 346-50.
 19. Flasko T, Toth G, Benyo, M, Farkas A, Berczi C. A new technical approach for extraperitoneal laparoscopic bladder diverticulectomy. *J Laparoendosc Adv Surg Tech A.* 2007; 17: 659-61.
 20. Nerli RB, Reddy M, Koura AC, Prabha V, Ravish IR. Cystoscopy-assisted laparoscopic partial cystectomy. *J Endourol.* 2008; 22: 83-6.
 21. Mariano MB, Tefilli MV. Laparoscopic partial cystectomy in bladder cancer initial experience. *Int Braz J Urol.* 2004; 30: 192-8.