

Constitutional Symptoms Masking COVID-19 In A Patient with Primary Myelofibrosis

Khan M¹, Schwartz C^{2,*} and Rondelli D²

¹Department of Medicine, University of Illinois at Chicago, Chicago, Illinois, USA

²Division of Hematology and Oncology, Department of Medicine, University of Illinois at Chicago, Chicago, Illinois, USA

Volume 4 Issue 10- 2020

Received Date: 14 Sep 2020

Accepted Date: 24 Sep 2020

Published Date: 28 Sep 2020

2. Keywords

Primary myelofibrosis; Hematopoietic stem cell transplant; COVID-19; Ruxolitinib

1. Abstract

Constitutional symptoms of primary myelofibrosis can mask COVID-19 infection. We present the case of a patient with primary myelofibrosis on ruxolitinib who tested positive for COVID-19 as part of Hematopoietic Stem Cell Transplant (HSCT) workup. The patient was asymptomatic and took over four weeks to develop a negative COVID-19 RT-PCR test. She did not test positive for COVID-19 antibodies. Patients with hematologic malignancies such as primary myelofibrosis or patients taking immunosuppressive therapy, such as ruxolitinib, may not develop infectious symptoms from COVID-19. In addition, they may take longer to test negative and may not develop antibodies to COVID-19. Therefore, these patients may be more vulnerable to re-infection. Although ruxolitinib may contribute to immunosuppression and increased susceptibility to infection, the drug is being studied as a possible treatment for COVID-19. To improve safety and patient outcomes, it is critical to test patients for COVID-19 prior to HSCT as clinicians cannot rely on symptoms to determine infection.

3. Introduction

Primary Myelofibrosis (MF) is a clonal myeloproliferative neoplasm which presents with anemia, splenomegaly, and constitutional symptoms, including severe fatigue and fever [1]. The exact molecular mechanism of MF pathogenesis is not known [2]. This include the envelope, nucleocapsid, RNA-dependent RNA polymerase, non-structural protein 10, and non-structural protein 14 and exoribonuclease [7]. In the bone marrow, clonal proliferation of hematopoietic stem cells is thought to result in cytokine release, myeloid hyperproliferation, and bone marrow fibrosis [3]. Driver mutations of genes including *JAK2*, *CALR*, and *MPL* have been identified [3]. The only curative treatment is hematopoietic stem cell transplant (HSCT) [1]. The mutation-enhanced international prognostic score system for transplantation-age patients (MIPSS70) provides risk stratification to identify appropriate candidates for HSCT, which carries its own significant morbidity [4]. Once a patient is identified for transplant, an extensive examination, including infectious workup, should be pursued.

In the new age of Coronavirus disease 2019 (COVID-19), it is more important than ever to determine if a patient has an infection prior to cancer directed therapy, especially prior to HSCT. COVID-19 is a novel viral respiratory infection that has rapidly caused a global pandemic. The infection has variable presentations in different hosts. Up to 40-45% of COVID-19 cases may be asymptomatic [5]. However, classic symptoms include fever, cough, and dyspnea, an-

osmia, and diarrhea [6].

COVID-19 infection can be diagnosed by reverse transcription polymerase chain reaction (RT-PCR) as well as point-of-care (POC) antigen detection. There are various possible RT-PCR targets in the viral genome, which contains approximately 30,000 nucleotides and 15 genes [7]. These include the envelope, nucleocapsid, RNA-dependent RNA polymerase, non-structural protein 10, and non-structural protein 14, exoribonuclease [7]. Mutations and variations in the sequence can limit this method [7]. Point-of care testing is less sensitive than the RT-PCR, and a negative RT-PCR result does not exclude COVID-19 infection[7].

In addition to initial testing for COVID-19, antibody assays have been developed to detect the immune response to infection. One study of 285 subjects showed 100% of patients tested positive for antiviral immunoglobulin G (IgG) within 19 days of symptom onset [8]. In addition, 7 of 148 close contacts of COVID-19 patients with initial negative RT-PCR tests were found to have positive IgG and/or immunoglobulin M (IgM) antibodies [8]. Another study in Wuhan, China found 55 of 66 confirmed COVID-19 cases to test positive for IgG antibodies [9].

We present the case of a patient with primary MF who was incidentally diagnosed with COVID-19 prior to stem cell transplant and her lack of ability to mount an immuneresponse.

Citation: Khan M, Schwartz C, Rondelli D. Constitutional Symptoms Masking COVID-19 In A Patient with Primary Myelofibrosis. Annals of Clinical and Medical Case Reports. 2020; 4(10): 1-3.

*Corresponding Author (s): Candice Schwartz, Division of Hematology and Oncology 840 S Wood Street Suite 820-E CSB, MC 713, Chicago, Illinois 60612, Tel: 312-996-9424, Fax: 312-413-4131, E-mail: cschw30@uic.edu

4. Case Report

The patient is a 67-year-old woman with high-risk primary MF on ruxolitinib and End-stage Renal Disease (ESRD) who tested positive for COVID-19 the week prior to planned HSCT. The patient was considered high-risk based on MIPSS70 score, mainly driven by anemia, thrombocytopenia, and constitutional symptoms. She had longstanding low-grade fevers for five years that were attributed to MF. As part of standard workup prior to transplant, she tested positive for COVID-19 by RT-PCR in the absence of any symptoms. She specifically denied cough, shortness of breath, sore throat, abdominal pain, and diarrhea prior to diagnosis. She reported social distancing but was in contact with her family who had been asymptomatic.

At time of diagnosis, the patient had a single fever to 39°C which quickly defervesced. She was hemodynamically stable with baseline tachycardia and was not hypoxic on room air. Labs were notable for lymphopenia, thrombocytopenia, and mild coagulopathy (absolute lymphocyte count 0.4 thous/ul, platelets 61 thous/ul, prothrombin time 15.6 sec, partial thromboplastin time 42 sec, international normalized ratio 1.2). Chest radiograph was unremarkable. Other inflammatory markers were not obtained. See (Table 1).

Infectious Disease service was consulted, and the decision was

Table 1. Vital signs and lab data throughout COVID-19 infection monitoring.

| Day | 1* | 18 | 26 | 32 | 39 |
|-----------------------|----------|----------|----------|----------|----------|
| Temperature (°C) | 39 | 36.7 | 37.3 | 37.1 | UNK |
| SpO ₂ | 96 | UNK | UNK | 96 | UNK |
| Oxygen (L/min) | 0 | 0 | 0 | 0 | 0 |
| WBC (thous/ul) | 4.4 | 5.2 | 12.8 | 16.7 | 16 |
| ANC (thous/ul) | 3.8 | 4.3 | 11.6 | 13.5 | 14.7 |
| ALC (thous/ul) | 0.4 | 0.4 | 0.6 | 2.5 | 0.8 |
| Platelets (thous/ul) | 61 | 67 | 84 | 85 | 93 |
| PT (sec) | 15.6 | UNK | UNK | UNK | 17.1 |
| PTT (sec) | 42 | UNK | UNK | UNK | 38 |
| INR | 1.2 | UNK | UNK | UNK | 1.4 |
| Albumin (g/dl) | 4.5 | 4.2 | 4.3 | 4.5 | 4.6 |
| AST u/l | 15 | 10 | 12 | 32 | 15 |
| ALT u/l | 13 | 10 | 14 | 12 | 16 |
| COVID-19 RT-PCR | Positive | Positive | Positive | Negative | Negative |
| COVID-19 IgG Antibody | UNK | UNK | UNK | Negative | UNK |

*Day of COVID-19 diagnosis

UNK: Unknown; WBC: White blood cells; ANC: Absolute neutrophil count; ALC: Absolute lymphocyte count; AST: Aspartate aminotransferase; ALT: Alanine aminotransferase; PT: Prothrombin time; PTT: Partial thromboplastin time; INR: International normalized ratio

made to defer HSCT until resolution of the infection. Therapies directed toward COVID-19 were not recommended given the patient’s asymptomatic presentation, but she was monitored with a low threshold to initiate treatment. Ruxolitinib was continued during this time. She remained stable and was discharged home with intermittent lab checks and repeat COVID-19 testing. On day 18 and day 26 after initial presentation with COVID-19, RT-PCR tests were positive. On day 32, RT-PCR became negative, and a COVID-19 IgG antibody test was also negative. Approximately two months after initial COVID-19 diagnosis and three negative COVID-19 tests, she underwent HSCT. A brief clinical course is outlined in (Figure 1). Her post-transplant course was not complicated by COVID-19.

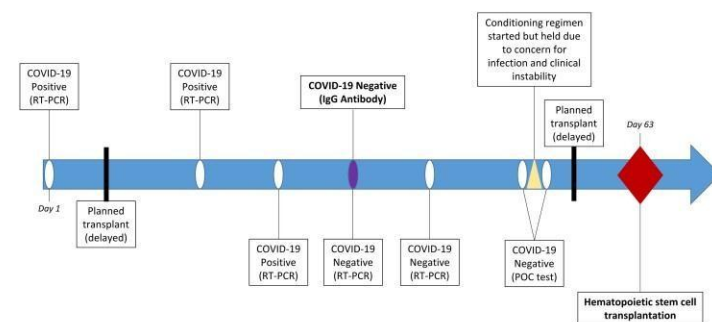


Figure 1. COVID-19 test results and major clinical events.

RT-PCR: Reverse transcriptase polymerase chain reaction; POC: Point-of-care.

5. Discussion

This case describes a patient with primary MF who was incidentally diagnosed with COVID-19. In the setting of chronic constitutional manifestations of MF and the fact that she had been having fevers for months prior to the COVID-19 pandemic, there was no distinct clinical sign of infection. Had she not been tested for COVID-19 prior to transplant, her infection may not have been diagnosed and she may have had a worse outcome. It is now standard of care to test all patients prior to transplant, because it cannot be assumed that an asymptomatic patient is not infected with COVID-19. In addition, resolution of COVID-19 in this patient was determined based on RT-PCR given that her fevers would continue at baseline due to MF.

The patient had negative COVID-19 IgG antibody testing 31 days after initial diagnosis. This is unusual given that Huang et al. observed 100% IgG seroconversion within 19 days [8]. In addition, Ma et al. detected IgG and IgM as early as four days after symptom onset, with IgG sharply increasing on the 12th day. Sensitivity of IgG was reported to be 83.3% [9]. The immunological derangements associated with primary MF, as well as concomitant immunosuppressive treatment with ruxolitinib may have prevented IgG formation.

Our patient was chronically treated with the Janus kinase inhibitor (JAKi) ruxolitinib, and this was continued during COVID-19 infection. The use of ruxolitinib in MF is well established with benefits related to symptoms and overall survival [10]. However, there is also a possibility of increased infectious risk with this immunosuppressive treatment due to effects on cytokine release, T-cells, and natural killer cells [11]. This is complicated by the fact that abrupt cessation of ruxolitinib may lead to severe withdrawal symptoms that include possible hemodynamic compromise and septic shock-like syndrome [12]. One discussion of JAKi use in COVID-19 notes only slightly increased infection rates in JAKi-treated patients and minimal pulmonary toxicities [13]. However, it is noted that cessation of JAKi therapy may be beneficial in COVID-19 infection to avoid suppression of the antiviral response [13]. In addition, JAKis are being studied for their potential use in COVID-19 for symptom reduction in multiple organs through angiotensin II type 1 receptor inhibition. They also may modulate inflammatory cytokines during ARDS and lead to improvement in more severe COVID-19 cases [14].

In the setting of the COVID-19 public health crisis, non-essential treatments have been delayed to prevent viral spread. In addition, we must be extremely cautious in the highly susceptible population undergoing HSCT. The European Society for Blood and Marrow Transplantation has recommended that confirmed COVID-19 cases should have HSCT deferred for 3 months in low-risk disease and until asymptomatic with 3 negative PCR tests at least a week apart in high-risk disease [15].

Several topics discussed in this case require further investigation. Notably, inflammatory markers were not measured throughout our patient's disease course. There is evidence that C-reactive protein, procalcitonin, interleukin 6, and erythrocyte sedimentation rate levels may correlate with disease severity [16]. Obtaining these tests may determine severity of disease and alter the patient's treatment course. In addition, ruxolitinib reduces symptoms of MF which may overlap with COVID-19, and it is unclear whether or not this therapy should be continued after infection. Ongoing research, including the RUXCOVID trial (NCT04362137) will address its potential benefit in COVID-19 illness.

6. Conclusion

Primary MF and immunosuppressive therapies may mask COVID-19 symptoms and prevent or delay seroconversion. Patients with MF, especially when undergoing HSCT, should be screened for COVID-19 and monitored carefully to improve safety. Clinicians cannot rely on symptoms as indicators of COVID-19 infection, particularly in patients with MF.

References

- Jain T, Mesa RA, Palmer JM. Allogeneic Stem Cell Transplantation in Myelofibrosis. *Biol Blood Marrow Transplant.* 2017; 23(9): 1429-1436. doi:10.1016/j.bbmt.2017.05.007.
- Lataillade JJ, Pierre-Louis O, Hasselbalch HC, et al. Does primary myelofibrosis involve a defective stem cell niche? From concept to evidence. *Blood.* 2008; 112(8): 3026-3035. doi:10.1182/blood-2008-06-158386.
- O'Sullivan JM, Harrison CN. Myelofibrosis: clinicopathologic features, prognosis, and management. *Clin Adv Hematol Oncol.* 2018; 16(2): 121-131.
- Guglielmelli P, Lasho TL, Rotunno G, et al. MIPSS70: Mutation-Enhanced International Prognostic Score System for Transplantation-Age Patients with Primary Myelofibrosis. *J Clin Oncol.* 2018; 36(4):310-318. doi:10.1200/JCO.2017.76.4886
- Oran DP, Topol EJ. Prevalence of Asymptomatic SARS-CoV-2 Infection: A Narrative Review. *Ann Intern Med.* 2020; M20-3012. doi:10.7326/M20-3012.
- Stokes EK, Zambrano LD, Anderson KN, et al. Coronavirus Disease 2019 Case Surveillance - United States, January 22-May 30, 2020. *MMWR Morb Mortal Wkly Rep.* 2020; 69(24): 759-765. Published 2020 Jun 19. doi:10.15585/mmwr.mm6924e2.
- Fang FC, Naccache SN, Greninger AL. The Laboratory Diagnosis of COVID-19-- Frequently-Asked Questions. *Clin Infect Dis.* 2020; ciaa742. doi:10.1093/cid/ciaa742.
- Long QX, Liu BZ, Deng HJ, et al. Antibody responses to SARS-CoV-2 in patients with COVID-19. *Nat Med.* 2020; 26(6): 845-848. doi:10.1038/s41591-020-0897-1.
- Xiang F, Wang X, He X, et al. Antibody Detection and Dynamic Characteristics in Patients with COVID-19 [published online ahead of print, 2020 Apr 19]. 2020; *Clin Infect Dis.* ciaa461. doi:10.1093/cid/ciaa461.
- Verstovsek S, Mesa RA, Gotlib J, et al. A double-blind, placebo-controlled trial of ruxolitinib for myelofibrosis. *N Engl J Med.* 2012; 366(9): 799-807. doi:10.1056/NEJMoa1110557.
- Dioverti MV, Abu Saleh OM, Tande AJ. Infectious complications in patients on treatment with Ruxolitinib: case report and review of the literature. *Infect Dis (Lond).* 2018; 50(5):381-387.
- Tefferi A. Primary myelofibrosis: 2019 update on diagnosis, risk-stratification and management. *Am J Hematol.* 2018; 93(12): 1551-1560. doi:10.1002/ajh.25230.
- Peterson D, Damsky W, King B. The use of Janus kinase inhibitors in the time of severe acute respiratory syndrome coronavirus 2 (SARS-CoV-2). *J Am Acad Dermatol.* 2020; 82(6): e223-e226.
- Seif F, Aazami H, Khoshmirsafa M, et al. JAK Inhibition as a New Treatment Strategy for Patients with COVID-19. *Int Arch Allergy Immunol.* 2020; 181(6):467-475. doi:10.1159/000508247
- Dholaria B, Savani BN. How do we plan hematopoietic cell transplant and cellular therapy with the looming COVID-19 threat?. *Br J Haematol.* 2020; 189(2): 239-240. doi:10.1111/bjh.16597.
- Zeng F, Huang Y, Guo Y, et al. Association of inflammatory markers with the severity of COVID-19: A meta-analysis. *Int J Infect Dis.* 2020; 96: 467-474. doi:10.1016/j.ijid.2020.05.055.