

## A Study of the Prediction of Bowel Resection Due to Strangulated Small Bowel Obstruction

Udaka T<sup>1\*</sup>, Taniguchi A<sup>1</sup>, Kouzai J<sup>1</sup>, Ootsuka T<sup>1</sup>, Watanabe N<sup>1</sup>, Endou I<sup>1</sup>, Yoshida O<sup>1</sup>, Asano H<sup>1</sup> and Kubo M<sup>1</sup>

<sup>1</sup>Department of Surgery, Mitoyo General Hospital, Japan

Volume 4 Issue 2- 2020

Received Date: 20 Apr 2020

Accepted Date: 29 May 2020

Published Date: 02 June 2020

### 2. Key words

Strangulated small bowel obstruction; Prognostic factor; Bowel resection; Reduced enhancement of the intestinal wall; Closed-loop obstruction

### 1. Abstract

**1.1. Background:** In this retrospective study, we aimed to assess the predictive factors for bowel resection due to Strangulated Small Bowel Obstruction (SSBO).

**1.2. Methods:** We enrolled a total of 109 patients diagnosed with SSBO at surgery. They were divided into two groups: those who underwent bowel resection and those who did not. The clinical findings, blood test results, blood gas analysis results, Computed Tomography (CT) findings, and sequential organ failure assessment (SOFA) scores of the patients were examined and compared between the two groups.

**1.3. Results:** The 109 patients were divided into the bowel resection group (n=38) and non-bowel resection group (n=71). A univariate analysis indicated significant predictive factors to be a history of abdominal surgery, prolonged time from the onset of disease to the operation, increased C-reactive protein (CRP) level, decreased albumin, SOFA score, existence of closed-loop obstruction, and reduced enhancement of the intestinal wall at CT. A multivariate analysis indicated that a reduced enhancement of the intestinal wall and the existence of closed-loop obstruction were independent predictive factors. Strangulated bowel obstruction can progress to a serious condition. It is therefore crucial to predict preoperatively those patients who are likely to require bowel resection.

**1.4. Conclusions:** Assessing the reduced enhancement of the intestinal wall and the existence of closed-loop obstruction are required in order to determine whether or not resection of the incarcerated intestine with SSBO is necessary.

**3. Abbreviation:** ALB: Albumin; CRP: C-reactive protein; CT: Computed tomography; OR: Odds ratio ; ROC: Receiver operating-characteristic; SBO: Small bowel obstruction; SIRS: Systemic inflammatory response syndrome; SOFA: Sequential organ failure assessment; SPSS: Statistical Package for Social Science; SSBO: Strangulated small bowel obstruction

### 4. Background

Strangulated Small Bowel Obstruction (SSBO) occurs when a closed loop of the intestine is formed as a result of mechanisms such as strangulation by a fibrous cord, torsion on the bowel, or intestinal hernia [1-3]. It impairs the blood supply to the loop along a spectrum that can range from partial transient ischemia followed by a full recovery after release of the obstruction to irreversible transmural necrosis. In ischemia without necrosis, releasing the obstruction is sufficient. In contrast, necrotic bowel segments must be resected.

A 35-year institutional experience revealed that 42% of cases of

Small Bowel Obstruction (SBO) were due to strangulation, while nonviable strangulation which have a 4-fold greater risk of death than viable strangulation accounted for 16% of cases [4]. Another study reported that patients with strangulated obstruction had 2 to 10 times higher rates of death than those with nonstrangulated obstruction [5, 6]. Thus, in order to prevent strangulation and potential bowel necrosis leading to an increased mortality rate prompt differentiation of the characteristics of SBO is needed [6, 7].

Strangulated obstruction may require immediate surgical intervention [5]. Preoperative recognition of a strangulated bowel with or without irreversible necrosis is important for surgeons to better plan surgical exploration [8].

In the present study, we explored the factors associated with bowel resection due to SSBO using the clinical parameters, including the medical history, laboratory test results, and Computed Tomography (CT) findings.

**Authors' contributions:** TU: Data collection, Manuscript writing. AT, JK, TO, NW, IE, and HA: Acquiring the data and revising the manuscript. IE, OY, HA, and MK: Revising the manuscript. All authors read and approved the final manuscript.

**Citation:** Udaka T. A Study of the Prediction of Bowel Resection Due to Strangulated Small Bowel Obstruction. *Annals of Clinical and Medical Case Reports*. 2020; 4(2): 1-5.

\*Corresponding Author (s): Tetsunobu Udaka, Department of Surgery, Mitoyo General Hospital, 708 Himehama Toyohama-cho, Kanonji, Kagawa 769-1695, Japan, Tel: 0875-52-3366; Fax: 0875-52-4936, E-mail: udaka@abeam.ocn.ne.jp

## 5. Methods

### 5.1. Patients and Study Design

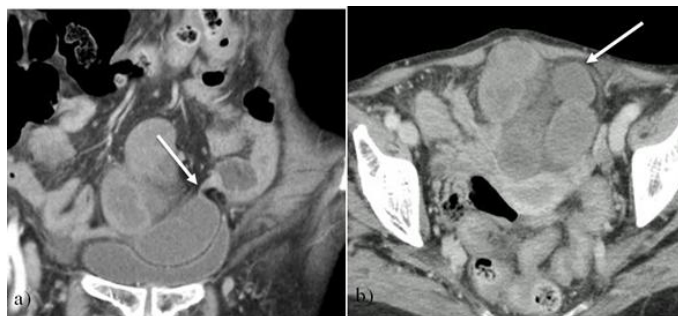
The study protocol was approved by the Institutional Review Board of Mitoyo General Hospital, and it conformed to the concepts of the Declaration of Helsinki and its amendments. This project was reviewed and approved by our institutional ethics committee. We enrolled a total of 109 patients diagnosed with SSBO at surgery between January 2009 and December 2019 in our hospital. Patients with large bowel obstruction, paralytic ileus, inguinal hernia, cancer-associated SBO, and postoperative adhesive SBO were excluded from the study.

Patients were divided into two groups according to the operative findings; the bowel resection group included patients found to have a strangulated small intestine requiring resection, and the non-bowel resection group included patients who did not require small intestine resection. The diagnosis of SSBO was based on the operative description and confirmed with pathology reports where possible.

The preoperative data gathered were the age, sex, history of abdominal surgery, time from the symptom onset to the operation, admission vital signs, maximal preoperative temperature, heart rate, and results of all appropriate laboratory studies including hematologic, electrolyte, blood gas, and enzyme values.

All preoperative abdominal CT findings were reviewed by two attending radiologists who had been blinded to the operative findings. The studies were evaluated for the presence of ascites, abnormally running vessels, elevation of the mesentery density, closed-loop obstruction, and reduced enhancement of the intestinal wall (Figure 1).

The Sequential Organ Failure Assessment (SOFA) score was used to assess the degree of serious illness [9].



**Figure 1:** (a) Representative CT showing closed-loop obstruction with a beak sign (Arrow). (b) Representative CT scan showing reduced enhancement of the intestinal wall (Arrow).

### 5.2. Outcome Measures

The main outcome examined was the factors predictive of a strangulated small bowel necessitating operative resection in patients with SSBO.

### 5.3. Statistical Analyses

Statistical analyses were performed using the Statistical Package for Social Science (SPSS) version 24 (Chicago, IL, USA) software program. The chi-square and Fisher's exact tests were used to compare categorical variables, and Student's *t*-test or the Mann-Whitney test was used to compare continuous variables. Subsequently, receiver operating-characteristic (ROC) curves were constructed to illustrate the sensitivity and false positive rate (1-specificity) of SOFA scores for the prediction of bowel resection. A multiple logistic regression analysis was performed to identify significant predictors associated with the need for bowel resection. All tests were two-sided and *P* values lower than 0.05 were considered significant.

## 6. Results

### 6.1. Patient Group Characteristics

The mean age of the patients was 73.3 (range 18-94) years old, with 46 male and 63 female patients (Table 1). Adhesion or stricture was the primary etiology in patients with SSBO and volvulus was the second-most common. Thirty-three (30 %) patients had no history of laparotomy, whereas 76 (70 %) had undergone previous abdominal operations. Gynecologic surgery was the most frequent previous abdominal operation.

**Table 1:** Patient Group Characteristics

Number of patients	109
Age (years)	73.3 (18~94)
Gender	Male 46 (42%), Female 63 (58%)
Origin of a strangulation	
Adhesion or stricture	92 (84%)
Volvulus	12 (11%)
Defect in the mesentery	5 (5%)
Previous laparotomy	
None	33 (30%)
Positive	76 (70%)
Gynecologic	25 (23%)
Colorectal cancer	18 (17%)
Gastric cancer	14 (13%)
Appendectomy	10 (9%)
Abdominal aortic aneurysm	3 (3%)
Cholecystectomy	3 (3%)
Obturator hernia	2 (2%)
Bowel obstruction	2 (2%)
Duodenal ulcer	2 (2%)

(With overlap examples)

### 6.2. Clinical Characteristics

The 109 patients were divided into the bowel resection group ( $n=38$ ) and non-bowel resection group ( $n=71$ ) (Table 2). There was no statistical difference in age and sex between the two groups. A history of abdominal operation was present in 87% of the bowel resection group and 61% of the non-bowel resection group ( $P=0.004$ ). The bowel resection group showed a significantly longer time from the onset to the operation than the non-bowel resection group ( $P=0.033$ ). There was no significant difference in Systemic Inflammatory Response Syndrome (SIRS) and shock between the two groups.

**Table 2:** Clinical Characteristics

		Bowel resection group (n=38)	Non-bowel resection group (n=71)	P-value
Age (years) (mean±SD)		75.2±11.3	72.2±16	0.615
Gender	Male	13 (34%)	33 (46%)	0.222
	Female	25 (66%)	38 (54%)	
Previous laparotomy	None	5 (13%)	28 (39%)	0.004
	Positive	33 (87%)	43 (61%)	
Time from the symptom onset to surgery (hr)	<24	20 (53%)	53 (75%)	0.033
	≥24	18 (47%)	18 (25%)	
SIRS	None	23 (61%)	53 (75%)	0.189
	Positive	15 (39%)	18 (25%)	
Shock	None	37 (97%)	70 (99%)	0.454
	Positive	1 (3%)	1 (1%)	

**6.3. Blood Test and Blood Gas Analysis Results**

The bowel resection group had significantly higher average C-Reactive Protein (CRP) and lower average albumin (Alb) levels than the non-bowel resection group (Table 3). There was no significant difference in the blood gas results between the two groups.

**Table 3:** Blood Test and Blood Gas Analysis Results

	Bowel resection group (n=38)	Non-bowel resection group (n=71)	P-value
WBC (/μL)	11,209±5209	9976±3819	0.298
mean±SD			
PLT (/μL)	213,680±45,380	23,213±79,276	0.122
CRP (mg/dl)	3.90±7.6	0.92±2.0	0.038
LDH (IU/L)	268.5±90.1	232.1±54.6	0.127
CPK (IU/L)	345.2±1435.9	114.2±84.9	0.911
Alb (g/dl)	3.7±0.6	3.9±0.5	0.029
PT-INR	1.31±1.3	1.06±0.1	0.452
PaO2 (mmHg)	81.3±15.3	87.6±16.9	0.116
PaCO2 (mmHg)	35.4±5.9	35.8±6.3	0.758
BE (mmol/L)	0.9±3.4	0.5±2.3	0.539

WBC: white blood cell, PLT: platelets, CRP: C-reactive protein, LDH: Lactate dehydrogenase, CPK: creatine phosphokinase, Alb: albumin, PT-INR: prothrombin time-international normalized ratio, BE: base excess

**6.4. CT Findings**

Multiple CT scan findings including evidence of a closed-loop obstruction and reduced enhancement of the intestinal wall were significantly more common in the bowel resection group than in the non-bowel resection group (Table 4). There was no significant difference in the presence of ascites, abnormally running vessels, and elevation of the mesentery density between the two groups.

**Table 4:** CT Findings

	Number of positive case (%)	Bowel resection group (n=38)	Non-bowel resection group (n=71)	P-value
Ascites	92 (84%)	3 (8%)	14 (20%)	0.179
	Positive	35 (92%)	57 (80%)	
Abnormally running vessels	104 (95%)	1 (3%)	4 (6%)	0.631
	Positive	37 (97%)	67 (94%)	
Elevation of the mesentery density	78 (72%)	9 (24%)	22 (31%)	0.504
	Positive	29 (76%)	49 (69%)	
Closed-loop obstruction	89 (82%)	2 (5%)	18 (25%)	0.02
	Positive	36 (95%)	53 (75%)	
Reduced enhancement of the intestinal wall	41 (45%)	4 (14%)	47 (74%)	<0.001
	Positive	25 (86%)	16 (26%)	

**6.5. SOFA Score**

The bowel resection group had a significantly higher average SOFA score than the non-bowel resection group ( $P=0.028$ ) (Table 5). In addition, the bowel resection group had a significantly lower average renal function score for SOFA than the non-bowel resection group ( $P=0.011$ ).

**Table 5:** SOFA scores

	Bowel resection group (n=38)	Non-bowel resection group (n=71)	P-value
SOFA score	1.14±1.5	0.63±0.9	0.028
Respiration	0.55±0.6	0.38±0.5	0.199
Coagulation	0.13±0.3	0.13±0.3	0.948
Liver function	0.18±0.5	0.09±0.3	0.347
Cardiovascular	0.05±0.2	0.01±0.1	0.332
Central nerve	0.00±0.0	0.00±0.0	1
Renal function	0.50±1.0	0.11±0.5	0.011

mean±SD  
SOFA: sequential organ failure assessment

**6.6. Multivariate Analysis Results**

Nearly every variable proved insignificant in the logistic regression analysis, with the exception of reduced enhancement of the intestinal wall on CT with an odds ratio (OR) of 87.7 ( $P <0.001$ ) and a closed-loop obstruction on CT with an OR of 59.4 ( $P <0.001$ ) (Table 6).

**Table 6:** The results of multivariate analysis of the prediction of bowel resection due to SSBO

	P value	Odds ratio	95% confidence interval
Previous laparotomy	0.099	5.269	0.796-45.681
Time from onset to the operation	0.089	5.193	0.894-45.665
CRP	0.798	1.253	0.230-7.883
Alb	0.956	1.045	0.223-1.028
SOFA score	0.689	0.857	0.419-1.945
Closed-loop obstruction	<0.001	59.382	8.342-865.818
Reduced enhancement of the intestinal wall	<0.001	87.662	16.212-512.752

**7. Discussion**

Strangulated obstruction is a life-threatening form of SBO. Hashimoto et al. reported the morbidity (31.3%) and mortality (5.4%) rate associated with SSBO [10]. A prompt diagnosis of SSBO and surgical intervention are important for avoiding a serious outcome, such as perforation, sepsis, and death [6]. A number of previous studies have evaluated the accurate and early diagnosis of SSBO, but early detection remains difficult; thus, the identification of more reliable diagnosis tools is urgently required. Identifying the preoperative predictive factors for bowel resection with SSBO is important. In the present study, we explored the factors predictive of the need for bowel resection due to SSBO using clinical parameters.

Significant predictive factors on a univariate analysis were the presence of a history of abdominal surgery, prolonged time from the onset of disease to the operation, increased CRP, decreased Alb, increased SOFA score, existence of closed-loop obstruction, and reduced enhancement of the intestinal wall at CT. However, we found in our regression analysis of multiple clinical variables that CT alone (specifically a reduced enhancement of the intestinal

wall and the existence of closed-loop obstruction) was a moderately sensitive indicator of which patients with SSBO would require bowel resection.

In SBO, ischemia results from the concomitant effects of three factors: mechanical obstruction of the blood vessels due to twisting of the bowel loop; compression caused by distention of the obstructed loop, resulting in arterial and venous microcirculation blockage with anoxia; and venous congestion in the distended loop [11]. Venous congestion can cause hemorrhagic venous infarction of the bowel wall [12], seen on CT as increased unenhanced bowel wall attenuation. However, this sign is not specific for bowel wall ischemia and can also be caused by bowel wall injuries, anticoagulant treatment, and bowel irradiation [13]. Increased unenhanced bowel wall attenuation is difficult to quantify and has never been described in detail. This sign should be assessed subjectively by a comparison with the attenuation of the neighboring normal loops, which has been reported to range 10 to 20 HU [14].

A variety of CT signs, such as mesenteric fluid, mesenteric venous congestion free peritoneal fluid, and reduced bowel enhancement, have been reported as findings related to bowel strangulation [15-18]. Millet et al. reported that a reduced enhancement of the bowel wall is highly predictive of ischemia [15]. Balthazar et al. reported that the detection of ischemic change in the bowel wall, attached mesentery, or both of on CT was diagnostic of bowel ischemia [19]. Nakashima et al. reported that reduced enhancements of the bowel wall and mesenteric vessels was reliable for detecting bowel ischemia [20]. Geffroyet al. reported that increased unenhanced bowel wall attenuation on 64-section multidetector CT had useful sensitivity and high specificity for the diagnosis of bowel wall ischemia in a highly select population of patients with surgically treated SBO [21].

Rondenot et al. reported that increased unenhanced bowel wall attenuation was the only significant predictor of necrosis in strangulated closed-loop SBO [22]. In our study, a reduced enhancement of the intestinal wall and the existence of closed-loop obstruction were found to be independent predictive factors for bowel resection with SSBO.

Distinguishing bowel necrosis from non-necrosis with SSBO is pivotal for developing a well-considered preoperative strategy and planning urgent surgery [7]. Preoperative knowledge of bowel necrosis is valuable for surgeons as they are thus better informed and better prepared for the possible need for bowel resection.

Several limitations associated with the present study warrant mention. First, this was a retrospective study and our data are based on the medical examinations performed at our hospital. Selection bias therefore could not be completely avoided. Second, due to the single-center setting, this model requires further validation. Further large-scale and well-designed studies are needed.

## 8. Conclusions

We have reassessed the value of a comprehensive array of clinical, laboratory, and imaging criteria for the prediction of which patients with SBBO will require resection of the small bowel. A multivariate analysis indicated that reduced enhancement of the intestinal wall and the existence of closed-loop obstruction were independent predictive factors for bowel resection with SSBO.

## 9. Declarations

### Ethics approval and consent to participate

This research project was reviewed and approved by our institutional Ethics Committee of the Affiliated Mitoyo Genral Hospital. Written informed consent was obtained from all individual participants included in the study.

## References

1. Fevang BT, Jensen D, Svanes K, Viste A: Early operation or conservative management of patients with small bowel obstruction? *Eur J Surg*. 2002; 168(8-9): 475-81.
2. Mucha PJ. Small intestinal obstruction. *Surg Clin North Am*. 1987; 67(3): 597-620.
3. Citgez B, Yetkin G, Uludag M, Karakoc S, Akgun I, Ozsahin H. Littre' hernia, an incarcerated ventral incisional hernia containing a strangulated Meckel diverticulum: report of a case. *Surg Today*. 2011; 41(4): 576-8.
4. Fevang BT, Fevang J, Stangeland L, Søreide O, Svanes K, Vista A. Complication and death after surgical treatment of small bowel obstruction: a 35-year institutional experience. *Ann Surg* 2000; 231(4): 529-37.
5. Çevikel MH, Özgün H, Boylu S, Demirkiran AE, Aydin N, Sari C, Erkus M. C-reactive protein may be a marker of bacterial translocation in experimental intestinal obstruction. *ANZ J Surg* 2004; 74(10): 900-4.
6. Cheadle WG, Garr EE, Richardson JD. The importance of early diagnosis of small bowel obstruction. *Am Surg* 1988; 54(9): 565-9.
7. Van Oudheusden TR, Aerts BA, de Hingh IH, Luyer MD. Challenges in diagnosing adhesive small bowel obstruction. *World J Gastroenterol* 2013; 19(43): 7489-93.
8. Kohga A, Kawabe A, Yajima K, Okumura T, Yamashita K, Isogaki J, et al. CT value of the intestine is useful predictor for differentiate irreversible ischemic changes in strangulated ileus. *Abdom Radiol* 2017; 42(12): 2816-21.
9. Vincent JL, de Mendonça A, Cantraine F, Moreno R, Takala J, Suter PM, et al. Use of the SOFA score to assess the incidence of organ dysfunction/failure in intensive care units: Results of a multicenter,

- prospective study. *Crit Care Med.* 1998; 26(11): 1793-800.
10. Hashimoto D, Hirota M, Matsukawa T, Yagi Y, Baba H. Clinical feature of strangulated small bowel obstruction. *Surg Today.* 2012; 42(11): 1061-5.
  11. Laufman H, Nora PF. Physiological problems underlying intestinal strangulation obstruction. *Surg Clin North Am AJR Am.* 1962; 42: 219-29.
  12. Ha HK, Kim JS, Lee MS, Lee HJ, Jeong YK, Kim PN, et al. Differentiation of simple and strangulated small-bowel obstructions: usefulness of known CT criteria. *Radiology.* 1997; 204(2): 507-12.
  13. Segatto E, Mortel  KJ, Ji H, Wiesner W, Ros PR. Acute small bowel ischemia: CT imaging findings. *Semin Ultrasound CT MR.* 2003; 24(5): 364-76.
  14. Frager D, Bacr JW, Medwid SW, Rothpearl A, Bossart P. Detection of intestinal ischemia in patients with acute small-bowel obstruction due to adhesions or hernia: efficacy of CT. *AJR Am J Roentgenol.* 1996; 166(1): 67-71.
  15. Millet I, Boutot D, Faget C, Pages-Bouic E, Molinari N, Zins M, et al. Assessment of strangulation in adhesive small bowel obstruction on the basis of combined CT findings: implications for clinical care. *Radiology* 2017; 285(3): 798-808.
  16. Hayakawa K, Tanikake M, Yoshida S, Yamamoto A, Yamamoto E, Morimoto I. CT findings of small bowel strangulation: the importance of contrast enhancement. *Emerg Radiol.* 2013; 20(1): 3-9.
  17. Sheedy SP, Earnest F 4th, Fletcher JD, Fidler JL, Hokin TL. CT of small-bowel ischemia associated with obstruction in emergency department patients: diagnostic performance valuation. *Radiology.* 2006; 241(3): 729-36.
  18. Wiesner W, Morte K. Small bowel ischemia caused by strangulation in complicated small bowel obstruction. CT findings in 20 cases with histopathological correlation. *JBR-BTR.* 2011; 94(6): 309-14.
  19. Balthazar EJ, Birnbaum BA, Megibow AJ, Gordon RB, Whelan CA, Hulnick DH. Closed-loop and strangulating intestinal obstruction: CT signs. *Radiology* 1992; 185(3): 769-75.
  20. Nakashima K, Ishimura H, Fujimoto T, Mizowaki T, Mitarai K, Nakashima K, et al. Diagnostic performance of CT findings for bowel ischemia and necrosis in closed-loop obstruction. *Abdom Imaging* 2015; 40(5): 1097-103.
  21. Geffroy Y, Boulay-Coletta I, Jull s M-C, Nakache S, Taourel P, Zins M. Increased unenhanced bowel-wall attenuation at multidirectional CT is highly specific of ischemia complicating small-bowel obstruction. *Radiology.* 2014; 270(1): 159-167.
  22. Rondenot C, Millet I, Corno L, Boulay-Coletta I, Taourel P, Zins M. Increased unenhanced bowel-wall attenuation: a specific sign of bowel necrosis in closed-loop small-bowel obstruction. *Eur Radiol* 2018; 28(10): 4225-33.