

Postpartum Meningitis by *Enterococcus Faecalis* Secondary to Neuraxial Anesthesia

Coll S^{1*}, Murillo E¹, Raynard M², Serra B¹ and Prats P¹

¹Department of Obstetrical, Gynecologic and Reproductive Unit, Hospital Universitari Dexeus, Barcelona, Spain

²Department of Anesthesiology, Resuscitation and Pain, Hospital Universitari Dexeus, Barcelona, Spain

Volume 4 Issue 1- 2020

Received Date: 14 Apr 2020

Accepted Date: 14 May 2020

Published Date: 21 May 2020

1. Abstract

Meningitis is an infrequent and serious cause of postpartum fever that requires early diagnosis and treatment to prevent serious complications and to reduce the high mortality rate. Neuraxial anesthesia is a frequently used technique in obstetrics. Meningitis is a very rare complication of neuraxial anesthesia and enterococcus is only involved in exceptional cases. We report the case of a 32-year-old female patient who developed meningitis during the immediate postpartum by *Enterococcus faecalis*, probably caused by contamination of the anesthesia puncture site and we reviewed available literature. Only five cases of enterococcal meningitis after neuraxial anesthesia have been reported so far. Median age was 36 years, 2 cases were males and 3 females. Only in our case there were risk factors for the development of meningitis such as obesity and the difficulty at the catheter insertion. Only one additional case was reported in the obstetrics setting. All patients recovered completely without any sequel.

2. Background

Endometritis is the most common infection during the postpartum. However, we should also consider mastitis, postsurgical wounds or episiotomy infections, urinary tract infections and septic pelvic thrombophlebitis. Meningitis is a rare cause of postpartum fever¹. Risk factors for infection are advanced age, preexistent comorbidities (diabetes mellitus (DM), immunosuppression, obesity, etc), intrapartum maneuvers (premature rupture of membranes, frequent cervical examination, internal fetal monitoring, instrumental delivery, manual examination of the uterine cavity) and postpartum complications (anemia, hematoma or seroma of the postsurgical wounds) [1].

Enterococci are significant human pathogens that are frequently involved in nosocomial infections [2]. Enterococcal Meningitis (EM) is an uncommon disease, accounting for only 0.3-4% of cases of bacterial meningitis [3] and *E. faecalis* is the bacteria involved in the majority of cases⁴. The clinical presentation of meningitis is similar to other causes of acute purulent meningitis.

3. Case Report and Review

A 32-year-old secundigravida with a single pregnancy after an *in vitro* fertilization attended our center to control her pregnancy. She presented a non-complicated pregnancy with normal ultrasound scans. In her medical record, her obesity (BMI: 37 kg/m²) and hypothyroidism were points that were noted.

The patient was admitted at the Delivery Ward for labor induction at 38+2 gestational weeks. Combined spinal and epidural anesthesia were offered and it was performed following antiseptic measures (the anesthesiologist used heat, gloves and mask and the patient's skin was prepared with iodopovidone). The procedure was difficult due to the patient's obesity and it was necessary to perform two attempts. Six hours later, she delivered vaginally with a first-degree perineal tear sutured successfully. Epidural catheter was removed immediately after delivery.

Almost 24 hours after delivery, the patient had an acute holocranial headache which irradiated to the neck and which was not alleviated by painkillers or/and postural measures. She was afebrile and hemodynamically stable. Two hours later, she had a fever (38.1°C). Clinical examination was unremarkable. Intravenous (iv) ampicillin 1g qid hours and gentamicin 80mg tid were administrated as empirical treatment for a possible postpartum infection. Blood test showed leukocytosis (15400/ml) and mild neutrophilia. Reactive C Protein was 106.2 mg/dl (nr <1). No other abnormalities were found. Cranial and abdominopelvic CT scanning came out with no pathological findings. Two hours later, the patient presented an altered mental status and meningeal signs and postpartum meningitis was suspected (**Figure 1**). A lumbar puncture was performed showing the following results: purulent cerebrospinal fluid (CSF), pleocytosis (12160cel/mL, nr <5cel/mL) elevated protein level (320.7mg/dL, nr <45 mg/dL) and hypoglycorrhachia (1mg/dL, nr > 50% of the glycemia). Antimicrobial regimen was modified to iv

*Corresponding Author (s): Dra Sandra Coll, Obstetrical, Gynecologic and Reproductive Unit, Hospital Universitari Dexeus, Barcelona, Spain, E-mail: sancoll@dexeus.com

Citation: Coll S, Postpartum Meningitis by *Enterococcus Faecalis* Secondary to Neuraxial Anesthesia. Annals of Clinical and Medical Case Reports. 2020; 4(1): 1-3.

vancomycin 15mg/kg tid and meropenem 2g tid. CSF culture and CSF Polymerase Chain Reaction (PCR) were positive for *Enterococcus faecalis*. The blood cultures were also positive for *Enterococcus faecalis*, although the results were not available until later. Regarding the susceptibility of the strain, treatment was adapted to iv ampicillin 2g every 4 hours and gentamicin 240mg bid. After two weeks of treatment, the patient was completely recovered with no sequels and was discharged with oral linezolid 600mg bid for one week.

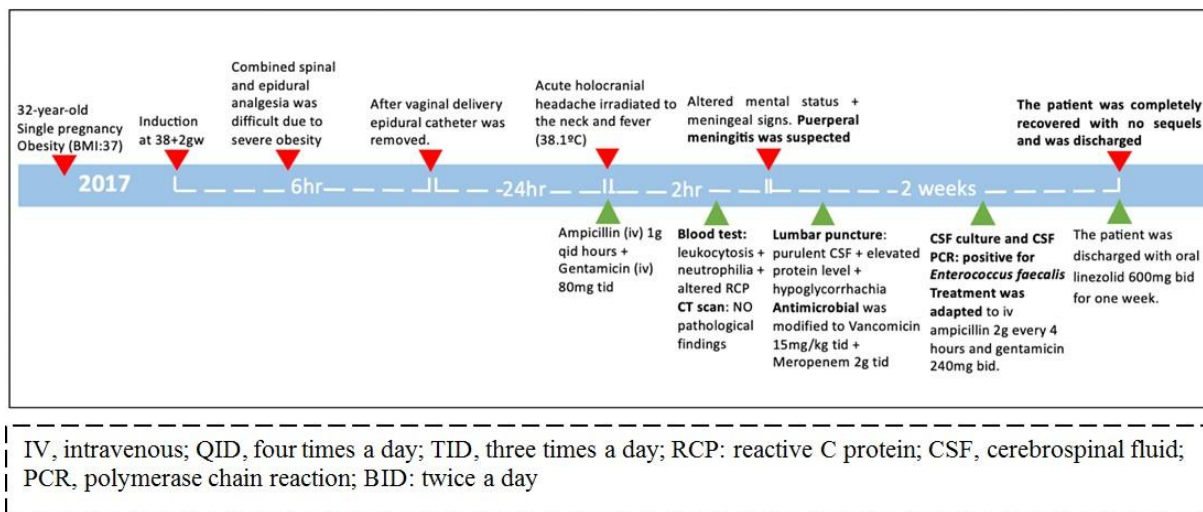


Figure 1: Clinical Evolution

4. Discussion

Postpartum infection is a common early complication after delivery and endometritis is the main cause. However, meningitis is an infrequent but very serious cause of postpartum fever and it should be considered as a differential diagnosis in case of neurological symptoms[1].

Enterococci represent an important cause of nosocomial infections. The microorganism could be inoculated during catheter insertion due to mouth or upper airway colonization of the operator, by bacteria residing on the skin or could be a consequence of an haematogenous spread from a distant source of infection. Finally, the fluids perfused into the peridural or spinal space may also be contaminated [2-4]. In our case, despite the anesthesia being performed following regular antiseptic measures, it was a difficult procedure due to the patient's obesity and it was performed after two attempts. This condition may have favored the inoculation of the germ into the CSF during the catheter insertion. There was no clinical condition or signs suggesting hematogenous spread from another source. After this case, antiseptic measures for NA in obese patients were reviewed and optimized.

Only 5 cases of enterococcal meningitis due to NA, including ours, have been reported so far (Table 1) [6-8], two of them after obstetric procedures. Median age was 36 years, 2 (40%) males and 3 (60%) females. Only in our case, there were risk factors for the

development of meningitis such as obesity and the difficulty at the catheter insertion. 3 (60%) cases were treated by ampicillin or penicillin and gentamicin. 1 (20%) case was treated by ceftriaxone and vancomycin and only 1 (20%) case was treated by linezolid + imipenem/cilastatin + rifampicin (strain was resistant to vancomycin and the patient had hypersensitivity to beta-lactams). All patients recovered completely without any sequel.

EM has a poor prognosis with a mortality rate of 21% [3]. Many complications have been described due to EM, with hydrocephalus being the most frequent one [3]. Cerebral abscess, cellulitis and stroke are less observed [3]. Empirical treatment should be established to prevent complications and to reduce the mortality rate. Ampicillin or penicillin is considered the standard therapy for enterococcal infections. International guidelines recommend antimicrobial therapy by combinations of cell wall-active antibiotics and aminoglycosides, synergistically effective against enterococci [3, 10-12]. Glycopeptides, such as vancomycin, have a lower CSF penetration and should be reserved for penicillin allergic patients or for ampicillin-resistant strains [3, 13]. The duration of treatment has not been established yet, but most reports support the use of a course of 2-3 weeks of antibiotic therapy [3]. Although the strain of our case was fully susceptible to antimicrobials and, thus, was treated by ampicillin and gentamicin, *Enterococcus* resistance to antimicrobials is a growing problem worldwide [14, 15].

Table 1: Reported cases of enterococcal meningitis secondary to neuraxial anesthesia

Patient	Reference List	Gender + Age	Anesthesia indication + type	Symptoms	CSF analysis	CSF culture or PCR	Treatment	Evolution
1	5	F/80	Vertebral fracture/ Epidural	Fever, headache, altered mental status and meningeal signs	L: 3360cel/ml P: 211mg/dl G: 68ml/dl	<i>E faecalis</i>	Ceftriaxone + Vancomycin	Complete recover
2	6	M/20	Inguinal hernia/ Spinal	Fever, headache, stiff neck, and meningeal signs	L: 9550cel/ml P: 1239mg/dl G: 19ml/dl	<i>E faecalis</i>	Ampicillin + Gentamicin	Complete recover
3	7	M/22	Left knee ligamentoplasty/ Rachidian	Fever, headache, vomiting, meningeal signs	L: 1500cel/ml P: 89mg/dl G: 58ml/dl	<i>E faecalis</i>	Linezolid (R to vancomycin) + Imipenem/cilastatin + Rifampicin	Complete recover
4	8	F/28	C-section/ Epidural	Fever, cellulitis, headache, stiff neck and photophobia	L: 3000cel/ml P: 308mg/dl G: 27mg/dl	<i>E faecalis</i>	Penicillin G + Vancomycin	Complete recover
5	Reported here	F/32	Labor/ CSE	Fever, headache, altered mental stratus, meningeal signs	L: 12160cel/ml P: 321mg/dl G: 1mg/dl	<i>E faecalis</i>	Ampicillin + Gentamicin	Complete recover

CSF, cerebrospinal fluid; PCR, polymerase chain reaction; F, female; M, male; L, leukocytes count; P, protein concentration; G, glucose concentration; R: resistance; CSE: combined spinal and epidural anesthesia.

5. Conclusion

To the best of our knowledge, this is the second case of postpartum meningitis by *Enterococcus faecalis* published so far. Although infrequent in the obstetric setting, acute meningitis is an infectious emergency that requires early diagnosis and treatment to prevent fatal complications and reduce the associated morbidity. It must be suspected in all cases of postpartum fever, particularly when headache is also present and it was not solved by painkillers or/ and postural measures. In obstetrical patients without a pathological medical history, NA during the delivery could be a risk factor for bacterial meningitis when it is technically difficult. To prevent EM, optimized antiseptic measures during the administration of the NA must be applied.

Reference

- WHO recommendations for prevention and treatment of maternal peripartum infections. Geneve. 2015.
- Giridhara PM, Ravikumar KL and Umapathy BL. Review of virulence factors of enterococcus: an emerging nosocomial pathogen. Indian Journal of Medical Microbiology. 2009; 27(4):301-5.
- Pintado V, Cabellos C, moreno S, Meseguer MA, Ayats J, Viladrich PF. Enterococcal Meningitis: A clinical study of 39 cases and review of the literature. Medicine. 2003;82:346-64.
- Traurig E. Post-Dural Puncture Bacterial Meningitis. Anesthesiology. 2006; 105:381-93.
- Donnelly T., Koper M. and Mallaiah S. Meningitis following spinal anaesthesia – a coincidental infection? International Journal of Obstetric Anesthesia. 1998; 7:170-172.
- Laguna P, Castañeda A, López-Cano M, García P. Bacterial meningitis secondary to spinal analgesia. Neurología. 2010; 25(9): 552-556.
- Tortosa J.A. and Hernández P. Enterococcus faecalis Meningitis after Spinal Anesthesia. Anesthesiology. 2000; 92: 909.
- Cournac J.-M., Landais C., Gaillard T., Bordes J. and Carli P. Ménin-gite à *Enterococcus faecalis* après rachianesthésie traitée avec succès par linézolide. Médecine et Maladies Infectieuses. 2012; 42(7): 327-8.
- Ready B. and Helfer D. Bacterial Meningitis in Parturients after Epidural Anesthesia. Anesthesiology. 1989; 71: 988-990.
- Maki DG, Agger VA. Enterococcal bacteremia: Clinical features, the risk of endocarditis, and management. Medicine (Baltimore). 1988; 67: 248-269.
- van de Beek D, Cabellos C, Dzupova O, Esposito S, Klein M, Kloek AT, et al. ESCMID guideline: diagnosis and treatment of acute bacterial meningitis. 2016.
- Tunkel A, Hartman B, Kaplan S, Kaufman B, Roos K, Scheld M. et al. Practice Guidelines for the Management of Bacterial Meningitis. Clinical Infectious Disease. 2004;39:1267-1284.
- Murray BE. Vancomycin-resistant enterococcal infections. New England Journal of Medicine. 2000; 342:710-721.
- García-Solache M and Rice L.B. The Enterococcus: a Model of Adaptability to Its Environment. Clinical Microbiology Reviews. 2019; 32(2).
- Sparo M., Delpech G and García Allende N. Impact on Public Health of the Spread of High-Level Resistance to Gentamicin and Vancomycin in Enterococci. Frontiers in Microbiology. 2018.