

## Two Cases of Suspected Novel Coronavirus Pneumonia Treated by Pidotimod Dispersible Tablets

Zhang MJ<sup>1</sup>, Wen XJ<sup>2</sup>, Jiang JJ<sup>3</sup>, Tu JY<sup>3</sup> and Li H<sup>3\*</sup>

<sup>1</sup>Department of Hospital Management, Shenzhen Sami Medical Center, 1# Jinniu West Road, Pingshan, Shenzhen, Guangdong 518118, China

<sup>2</sup>Department of Anesthesiology, The Second People's Hospital of Foshan, 78# Weiguo Road, Foshan, Guangdong 528000, China

<sup>3</sup>Department of Anesthesiology, The Sixth Affiliated Hospital of Guangzhou Medical University, B24 District, Qingyuan, Guangdong 511500, China

Volume 3 Issue 3- 2020

Received Date: 18 Feb 2020

Accepted Date: 15 Mar 2020

Published Date: 21 Mar 2020

### 2. Key words

Novel coronavirus pneumonia;  
Pidotimod dispersible tablets

### 1. Abstract

The global spread of novel coronavirus pneumonia (COVID-19) directly endangers social health and safety. COVID-19 has a rapid onset, rapid progress. All people are susceptible to infection and no specific drugs. Our team directly contacted these patients. In the case of chance and emergency, two suspected patients had taken Pidotimod dispersible tablets. After 30min, the clinical symptoms of patients were improved rapidly. A few days later, the focus of chest CT pneumonia disappeared. We were surprised by the superior therapeutic effect of pidotimod dispersible tablets on patients; hope this report to give other clinicians a good inspiration and help.

### 3. Introduction

Novel Coronavirus Pneumonia (COVID-19) is seriously threatening people's lives, and its morbidity and mortality are increasing [1, 2]. Now the epidemic situation in China has been effectively controlled. But in the recent week, the epidemic has been expanding and spreading rapidly all over the world. As of March 12, 80,793 cases were confirmed, 3,169 cases died and 62,793 cases were recovered. In addition to China, there are 44,483 confirmed cases and 1,456 deaths in 119 countries and regions, and these data are rising sharply [3]. COVID-19 has a rapid onset and deterioration. All people are generally susceptible and have no specific drugs. This paper reports that Pidotimod dispersible tablets were used occasionally in the treatment of two patients with suspected coronavirus pneumonia, and the unexpected curative effect was achieved.

### 4. Case Report

The Patient1's uncle family came from his hometown to Patient1's home (Shenzhen, a southern city in China) to celebrate the Spring Festival. The Patient1's uncle (Patient4) bought fresh food at the poultry market five days ago. Five days later, they returned to their hometown. His uncle (Patient4) and aunt (Patient5) suffered from dry cough, fever, fatigue, shortness of breath and other clinical symptoms. After that, their symptoms gradually worsened, and they were transferred to the hospital for examination. Their throat

swab samples were detected by real-time fluorescent RT-PCR (throat swab test), which showed that the novel coronavirus nucleic acid was positive. Then they were diagnosed as novel coronavirus pneumonia (COVID-19).

After knowing the information of uncle's diagnosis, Patient1's family immediately went to the medical observation hotel for isolation. In the evening (the 10th day after close contact), Patient1 continued to have low fever, with a maximum body temperature of 37.2 °C, accompanied by chest distress. He took antiviral oral liquid (Proprietary Chinese Medicine, unknown ingredients) 10ml and Lianhuaqingfei capsule (Proprietary Chinese Medicine, unknown ingredients) 14g. The next day (the 11th day after close contact) after getting up in the morning, Patient1 had symptoms such as fatigue, chest tightness, cough, dyspnea, etc., and the temperature continued to rise, with a maximum of 37.8 °C. Due to the acute onset of the disease, there are no other drugs in the hotel for monitoring the epidemic. Patient1 had pidotimod dispersible tablets. After reading the instructions, the hotel medical staff suggested that Patient1 could take the medicine voluntarily according to the instructions and observe the effect. Patient1 immediately took pidotimod dispersible tablets 0.8g. After 20 minutes, the respiratory rate slowed down, chest tightness and shortness of breath gradually improved. After 30 minutes, the temperature dropped to 36.8 °C. Chest tightness, dyspnea and other symptoms gradually

\*Corresponding Author (s): HengLi, Department of Anesthesiology, the Sixth Affiliated Hospital of Guangzhou Medical University, B24 District, Qingyuan, Guangdong 511500, China. Telephone: +86-763-3113871, Email: liheng00670@gzhu.edu.cn

<http://www.acmcasereport.com/>

Citation: Li H, Two Cases of Suspected Novel Coronavirus Pneumonia Treated by Pidotimod Dispersible Tablets. Annals of Clinical and Medical Case Reports. 2020; 3(3): 1-5.

disappeared. Patient1 took another 0.8g of pidotimod that night and another 0.8g the next day, with a total dosage of 2.4g. His throat swab test was negative. Diagnosis and Treatment of Novel Coronavirus Pneumonia (trial version seventh) was issued by the National Health Committee (NHC) in March 3, 2020 [4]. Patient1 was classified as a suspected case (Table 1).

The next day (the 11th day after close contact), Patient1's wife (Patient2) also suffered from mild asthenia, shortness of breath after activity, dry cough and low fever of 37.2 °C. However, COVID-19 was diagnosed as positive by swab test. She was then sent to a designated hospital for isolation and treatment.

**Table 1:** Summary of Clinical features and Laboratory Results of the Family Infected with 2019 Novel Coronavirus.

	Patient1	Patient2	Patient3	Daughter1	Daughter2	Patient4	Patient5	Daughter3
Relationship		Wife of Patient 1	Mother-in-law of Patient 1	Patient1's family	Patient1's family	Patient1's Uncle	Patient1's Aunt	Patient4's family
Age(years)	34	34	58	2.7	2.7	55	53	30
Sex	Male	Female	Female	Female	Female	Male	Female	Female
Occupation	Manager	Housewife	Retired	None	None	Worker	Worker	Student
Chronic medical illness	None	None	None	None	None	None	None	None
Interval between symptom onset and the poultry market(days)						14		
Interval between admission to hospital and symptom onset (days)	14	14	15			10	10	
Presenting symptoms and signs								
Fever	+	+	+	-	-	++	+	-
Cough	+(dry)	+(dry)	+(dry)	-	-	++(dry)	+(dry)	-
fatigue	+	+	-	-	-	+	+	-
chest tightness	+	+	-	-	-	++	+	-
Sore throat	-	-	-	-	-	++	+	-
Shortness of breath	+	+	+	-	-	+++	+	
dyspnea	-	+	-	-	-	++	+	-
Diarrhoea	-	-	-	-	-	-	-	-
Body high temperature (°C)	37.8	37.1	37.1	36.5	36.7	38	37.1	36.8
Throat Swab Test	-	+	-	-	-	+	+	-
PCT	+	+	NA	NA	NA	NA	NA	NA
IgM	-	-	++	+	+	NA	NA	NA
IgG	-	-	++	+	+	NA	NA	NA
White blood cell count (×10 <sup>9</sup> cells per L);	Normal	Normal						
Lymphocyte count (×10 <sup>9</sup> cells per L);	Normal	Normal						
Eosinophilcount (×10 <sup>9</sup> cells per L);	↓	↓						
Percentageof eosinophils(%)	↓	↓						
Neutrophilcount (×10 <sup>9</sup> cells per L);	↑	↑						

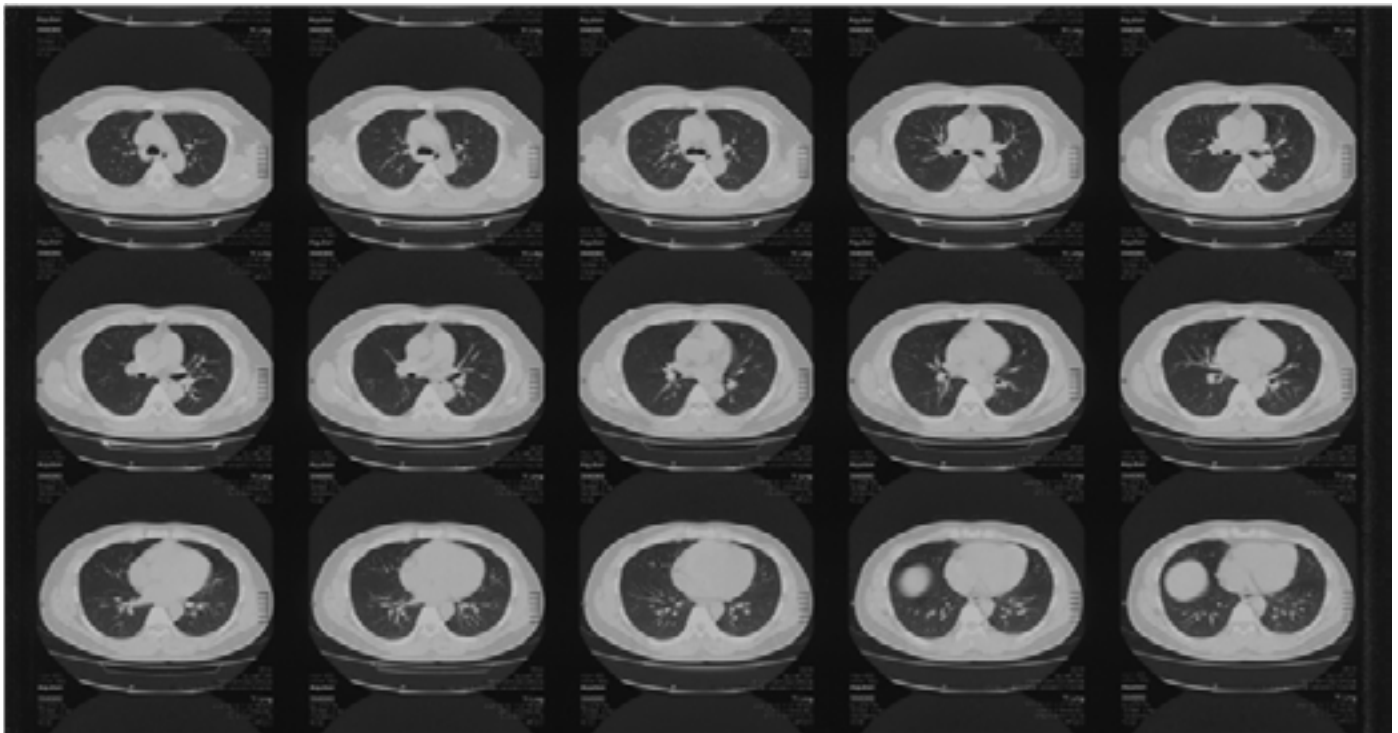
On the third day (the 12th day after close contact), Patient1's mother-in-law (Patient3) who was isolated had low fever, 37.1 °C, accompanied by dry cough and asthenia. Patient3 also took pidotimod dispersible tablet 0.8g by herself. After 30 minutes, the body temperature dropped to 36.6 °C, and the symptoms of asthenia decreased. After 6 hours, 0.8g was taken orally again; because pidotimod was no longer available at that time, it was not taken again. Her nucleic acid of throat swab was negative. According to the diagnosis and treatment plan of NHC, Patient3 was also listed as a suspected case for medical observation.

On the fifth day (the 14th day after close contact), the CT of Patient1 showed that there were a few strip like density increasing shadows in the medial middle lobe of the right lung and the lower tongue segment of upper lobe of the left lung, with fuzzy edges and adhesion near the pleura. Mild pneumonia was diagnosed ( Figure 1). After 4 days of hospitalization, CT of Patient1 showed that both lung fields were clear, lung texture was regular, and the focus of pneumonia disappeared. The results of nucleic acid test of throat swab were still negative. He continued to receive medical observation at the designated place after discharge.

In the 20 days after the oral administration of pidotimod, Patient1 and Patient3 had no fever, clinical discomfort and other symptoms. After a comprehensive assessment by the medical staff, their medical observation was removed. Patients2, Patients4 and Patients5 have recovered from multiple treatments. The children of their two families have never had any clinical symptoms.

## 5. Discussion

The COVID-19 is more serious. At present, there is no specific drug in clinical practice, which has brought great panic to the society. In the course of treatment, clinical doctors actively explore various drugs to cure or inhibit the replication and spread of the virus. Chinese doctors have actively used Traditional or Proprietary Chinese Medicine to treat patients with novel coronavirus and achieved some remarkable results [4]. The clinical treatment of Traditional Chinese Medicine is mainly from the aspects of dispelling dampness and strengthening body, recuperating the body, strengthening physique and immunity and so on. However, traditional Chinese medicine has a long effective time and slow effect, which is its deficiency [5, 6]. Each person's constitution is different,



**Figure 1.** Chest CT findings of Patient 1 on February 12.

This image showed that there were a few pieces of density enhancement in the medial segment of the middle lobe of the right lung and the upper lobe and the lower tongue segment of the left lung, the edge was fuzzy, the adjacent pleura was adhered, the texture distribution of other lung lobes was regular and clear, no abnormal density was found in the lung parenchyma, mediastinum was not displaced, the shape and size of the trachea and large blood vessels were normal, and no definite enlarged lymph nodes were found. The main diagnosis was mild inflammation of the middle lobe of the right lung and the sublingual segment of the upper lobe of the left lung.

and the result is different. Therefore, it is more urgent to explore the therapeutic effect of synthetic drugs to improve the body immunity.

Pidotimod dispersible tablet is a synthetic oral immunostimulant, which plays a role by stimulating and regulating cell-mediated immune response. It is commonly used in the auxiliary treatment of chronic or recurrent respiratory tract infection and urinary tract infection. Pharmacokinetic study showed that the drug was absorbed rapidly by oral administration. The bioavailability of human oral administration was 45% and the half-life was 4 hours [7]. The research effect of Pidotimod in the treatment of children's recurrent respiratory tract infection is significant; the drug can stimulate non-specific natural immunity, and significantly improve the level of IgA and IgG in the body. It can also regulate the function of T-lymphocyte and B-lymphocyte, regulate the generation of antibody, increase the chemo taxis, phagocytosis and killing of macrophages, enhance the immune function of the body, and achieve the purpose of treating respiratory tract infection [8].

Two suspected patients had a history of obvious contact with novel coronavirus, and their physical signs were very consistent with the clinical symptoms of COVID-19. After taking Pidotimod, signs were relieved rapidly. These evidences suggest that Pidotimod may play a therapeutic role by enhancing the immunity of the body through these mechanisms. Unfortunately, due to the complicated procedures for reporting infectious diseases, which took a long time, the best blood sample collection time was missed. When laboratory data were obtained on the fourth day, all indicators showed normal. In addition, patients are afraid of being discriminated and are unwilling to provide these data to our staff. We are not reluctant to ask for further verification of those data.

The novel coronavirus can cause a severe respiratory illness, like SARS and MERS, and human-to-human transmission has been confirmed. Pidotimod, as an immune promoter, can not only promote non-specific immune response, but also promote specific immune response. Animal and clinical trials have shown that although Pidotimod has no direct antibacterial and antiviral activity, it can play a significant role in the treatment of bacterial (*Diplococcus pneumonia*, *Escherichia coli*, *Pseudomonas aeruginosa*, *Proteus*, etc) and viral (Influenza virus, Herpes simplex virus, Mouse encephalomyocarditis virus and Mengo virus) infection by promoting the immune function of the body [9, 10].

It is puzzling that the children of both families have no clinical symptoms of suspected cases, and the nucleic acid test is also negative. Later, the medical history was asked. Before the outbreak,

the children lived in a separate room from their parents, and their parents actively reduced contact. An interesting result attracted us, the twins were both positive for IgG and IgM, while their parents were negative for IgG and IgM. This may be one of the reasons why they are not easy to get sick. Or they have less time to be contacted by their parents and less chance of being attacked by the virus. However, these explanations need a lot of laboratory data to be clarified. Unfortunately, these data are not easy to obtain because of various excuses.

Patient 1 and patient 3 tried Pidotimod dispersible tablets occasionally to improve immunity when other Traditional Chinese Medicine were not available, which had rapid effect and achieved unexpected therapeutic effect. Although it does not have the universality of the treatment of coronavirus pneumonia, it provides a new idea for clinical treatment. In the later stage of the trial, the consent of the ethics committee should be obtained, and the data of the trial sample should be expanded to further prove the therapeutic effect and reveal the internal mechanism of its effect.

## References

1. The Lancet. Emerging understandings of 2019-nCoV. *Lancet*. 2020; 395: 311.
2. Editorial. Challenges of coronavirus disease 2019. *The Lancet Infectious Disease*. 2020; 17.
3. Latest on the novel coronavirus outbreak. *China Daily*. Press. 2020
4. Diagnosis and treatment of novel coronavirus pneumonia (trial version seventh) Issued by National Health Commission of the People's Republic of China. 2020.
5. Wang H, Li J, Yu X, Li SY. Integrated traditional Chinese and conventional medicine in treatment of severe community-acquired pneumonia: study protocol for a randomized placebo-controlled trial. *Trials*. 2018; 19: 620.
6. Eng YS, Lee CH, Lee WC, Huang CC, Chang JS. Unraveling the Molecular Mechanism of Traditional Chinese Medicine: Formulas Against Acute Airway Viral Infections as Examples. *Molecules*. 2019; 24: 3505.
7. Zuccotti GV, Mameli C. Pidotimod: The past and the present. *Ital J Pediatr*. 2013; 39: 75.
8. Mahashur A, Thomas PK, Mehta P, Nivangune K, Muchhala S, Jain R. Pidotimod: In depth review of current evidence. *LungIndia*. 2019; 36: 422-33.

9. Puggioni F, Alves-Correia M, Mohamed ME, Stomeo N, Mager R, Marinoni M, et al. Immunostimulants in respiratory diseases: focus on Pidotimod. *MultidiscipRespir Med.* 2019; 14: 31.
10. Li X, Li Q, Wang X, Lu M, Shen J, Meng Q. Pidotimod in the treatment of pediatric recurrent respiratory tract infection. *Pak J Med Sci.* 2019; 35: 981-6.