

A Valve Repair after Infective Endocarditis Secondary to Perforation Caused by Streptococcus Gordonii - A Case Report and Literature Review

Qu Y*

Department of Medicine, China

*Corresponding author:

Yifan Qu,
Department of Medicine, China,
E-mail: yishuyoutianfen@126.com

Received: 20 Nov 2022

Accepted: 01 Dec 2022

Published: 10 Dec 2022

J Short Name: ACMCR

Copyright:

©2022 Qu Y. This is an open access article distributed under the terms of the Creative Commons Attribution License, which permits unrestricted use, distribution, and build upon your work non-commercially

Citation:

Qu Y, A Valve Repair after Infective Endocarditis Secondary to Perforation Caused by Streptococcus Gordonii - A Case Report and Literature Review. Ann Clin Med Case Rep. 2022; V10(8): 1-5

Keywords:

Bacteraemia; Comprehensive medical and surgical treatment; Streptococcus gordonii; Subacute infective endocarditis

1. Abstract

We report a case of infective endocarditis in a patient with congenital heart valve lesions accompanied by Streptococcus gordonii infection. A 61-year-old man presented with recurrent fever for four months. Immune system and myelopoietic disorders and tuberculosis were all ruled out as possible causes of the fever. He was diagnosed with subacute Infective endocarditis (IE) after blood culture analysis, which revealed presence of a Gram-negative bacterium - Streptococcus gordonii, combined with his history of precordial valve disease and cardiac ultrasound as well as a four-month history of fever. He was subjected to comprehensive anti-infection and anti-heart failure treatment in the internal medicine department. Further examination revealed sudden dislodgement and perforation of the superfluous organism in the aortic valve, as well as occurrence of bacterial emboli dislodgement causing bacteremia and infectious shock. He recovered and was discharged from the hospital after surgical and postoperative anti-infection treatments. Here, we review the treatment process and highlight inspirations and reflections from this case.

2. Introduction

Infective endocarditis (IE) is a life-threatening cardiovascular disease with an annual incidence of 1.5/100,000-15/100,000 and a mortality rate of 20%-25% [1]. The disease is caused by a pathogenic microorganism that directly infects heart valves, the endocardium of the ventricular wall or the endocardium of the adjacent aorta via the bloodstream, often leading to superfluous organisms

[2] Subacute IE is characterized by an insidious and slow onset, with a long course that usually lasts between 6 weeks and 3 months. The patient mostly experiences cardiac problems. Due to the insidious site of infection, Notably, the IE patients have diverse and non-specific clinical manifestations, which subsequently lead to missed diagnosis and misdiagnosis that result in serious adverse consequences that threaten the quality of life [3]. Therefore, early diagnosis coupled with timely treatment are crucial for management of the disease. In the present study, we report a case of IE caused by Streptococcus gordonii, with fever as the main manifestation, at our hospital.

3. Case Report

A 61-year-old man presented at our hospital with intermittent fever and malaise for 4 months. Four months before the visit, he had developed a fever (up to 40°C), mostly in the afternoon and at night, accompanied by chills, and malaise. Although his body temperature normalized after three days of anti-infection treatment via self-infusion, a the fever reappeared after stopping the treatment. The disease worsened progressively, his blood pressure decreased and was accompanied by increased heart rate. The patient was diagnosed with infectious shock and subsequently transferred to our hospital for further treatment.

Physical examination revealed a slightly pale skin and mucous membranes, with no anger in the jugular vein, and enlargement of the cardiac border to the left. There was also evidence of grade III-IV diastolic murmur in the aortic valve area, and peripheral

vascular signs (+). Laboratory test results revealed normal leukocytes and neutrophils, C-reactive protein and calcitonin levels of 53.1 mg/l and 2.66 ng/ml, respectively, as well as liver and renal function that were within normal limits. PPD test results were negative, paired blood cultures (asymmetric limbs, e.g., left upper limb and right lower limb) on three consecutive days shows Gram-positive cocci. Macrogenetic test GNS shows *Streptococcus gordonii*. Cardiac ultrasonography shows EF 52% and aortic valve leaflet thickening and echogenic enhancement, moderate regurgitant signal under the aortic valve in diastole, small amount of regurgitant signal on the left atrial side of the mitral valve in systole, small amount of regurgitant signal on the right atrial side of the tricuspid valve in systole, ascending aortic internal diameter 46 mm, aortic valve Vmax 2.2 m/s, enlarged left atrium, aortic valve calcification and moderate regurgitation, mild regurgitation of the second and tricuspid valves (Figure1, 2); Cardiac MRI results were consistent with dilated cardiomyopathy changes, left heart insufficiency, significantly reduced systolic function, aortic valve thickening and stenosis, incomplete closure, mitral valve, tricuspid valve incomplete closure, small amount of pericardial effusion, pericardial inflammatory changes, and a small amount of bilateral pleural effusion.

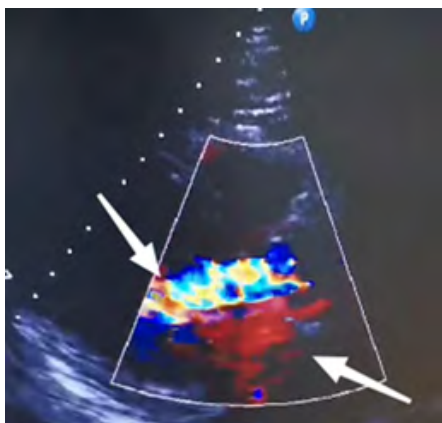


Figure 1: Bidirectional regurgitation of the aortic valve (shown by arrows).

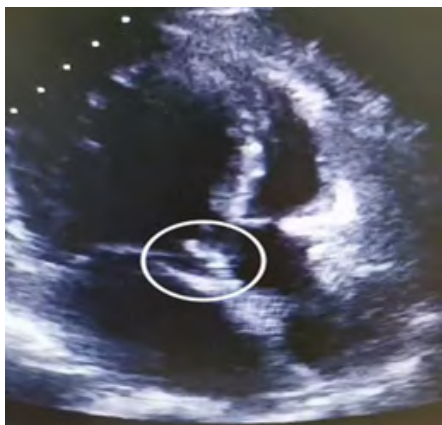

Figure 2: Aortic valve bulge (shown in circle)

Bone marrow aspiration: Flow cytometry showed an increase in the proportion of granulocytes and nucleated red, and a mild decrease in the proportion of lymphocytes. The phenotype was not abnormal. Abnormal immunoglobulins and identification of multiple myeloma: Immunofixation electrophoresis (IFE) results: serum: polyclonal immunoglobulins, no “M protein” detected; urine: no kap and lam light chain “M protein” detected. Serum protein and immunofixation electrophoresis revealed no significant “M protein”, a reduction in albumin levels, and elevated levels of $\alpha 1$ and γ globulin. Serum IgG, IgA, IgM and kap, as well as lam light chain levels were normal, with high IgE levels. We also found a moderate increase in the level of urine kap light chain and 24-hour urine protein levels. Protein electrophoresis revealed no specific band in urine. No light chain type “M protein” was detected in urine via immunofixation electrophoresis, while bone marrow aspiration revealed normal results. The results excluded multiple myeloma. Table 1.

Table 1: (Bone marrow aspiration flow cytology results showed no abnormalities)

Name	value	ref. rang	unit
IgG	1500	751 1560	mg/dl
IgE	126	0 100	Iu/ml
Urine kaP	2.1	<1.9	Mg/dl
Stray lam	38.2	8.3 27.0	mg/l
Lamlight chain	704	313 723	mg/dl
IgA	243	453	mg/dl
Urine lam	<5.0	<5.0	mg/dl
FLC k/l	0.56	0.31 1.56	mg
IgM	57.5	46 304	mg/l
24hUrine protein	298.3	0 150	mg
Stray kap	21.4	6.7 22.4	mg/l
Kaplight chain	1310	629 1350	mg/dl

The patient’s prolonged unexplained fever, coupled with blood culture and echocardiographic results made us to strongly suspect subacute infective. The patient’s fever had subsided after 9 days of continuous treatment, and his infection index was under control. Consequently, aortic valve replacement was recommended following anti-infection treatment. Preoperative sudden onset of chest and abdominal pain with profuse sweating, Emergency transesophageal ultrasonography. Results are presented in Figure 3. Summarily, we found evidence of aortic valve redundancy with perforation, while emergency CTA results revealed moderate stenosis of the lumen at the beginning of the abdominal trunk. The possibility of bacteriophageal involvement and visible penetrating ulcers was considered (Figure 4). Consequently, the surgical approach was changed from simple aortic valve replacement to Aortic valve replacement surgery and aortic valvuloplasty. Intraoperative examination revealed the following results: moderate levels of a yellowish pericardial fluid, marked widening of the ascending

aorta, marked malformation of the aortic bicuspid valve, leaflet destruction with perforation and massive regurgitation, complete leaflet removal, placement of aortic valve bioprosthesis, and compression of the artificial vessel to wrap the ascending aorta. The operation was successfully completed. Postoperative pathological analysis revealed fibrous connective tissue hyperplasia with focal

glassy and mucinous degeneration, localized fibrin deposition, and evidence of calcified foci in the valve tissue. The patient received anti-infection treatment for one month after surgery. Reexamination revealed that his liver, kidney and cardiac functions had been restored back to normal.

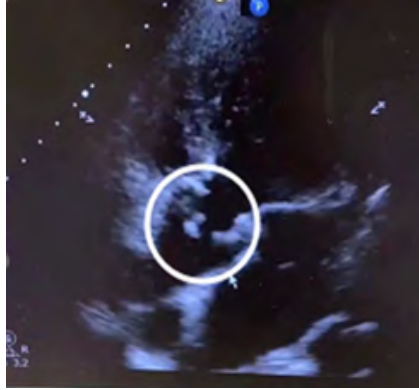


Figure 3: Aortic valve redundancy detached with perforation.

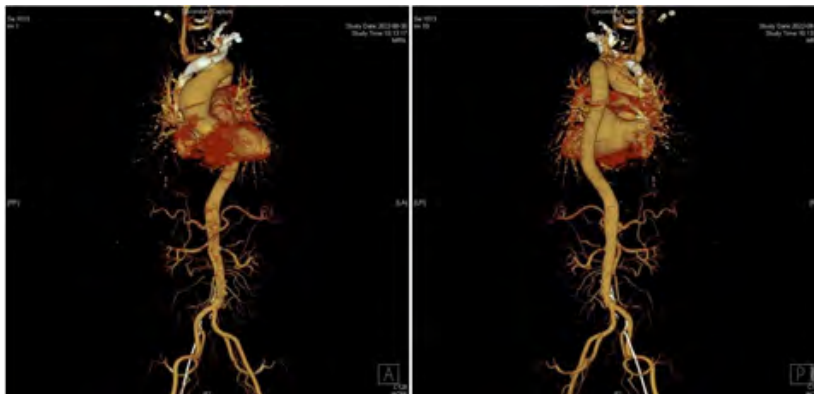


Figure 4: CTA findings showing moderate stenosis of the lumen at the beginning of the abdominal trunk, with possible bacteriophage involvement and visible penetrating ulcers.

4. Discussion

In 2016, the American association for thoracic surgery (AATS) published an expert consensus on surgical management of infective endocarditis, the most recent guiding document for management of this condition. AATS expert consensus indicates that, the current DUKE criteria, which are based on diagnostic criteria proposed in 1994 and have subsequently been modified several times, are the most practical for the diagnosis of IE [4]. The most common clinical IE manifestation is fever, with insidious onset in subacute cases and relatively mild toxic symptoms that may range from weeks to months. Although IE is a common cause of unexplained fever, only 18.6%-20.3% of patients present with typical manifestations described in the DUKE criteria, such as skin petechiae, emboli, splenomegaly, and Osler nodules. About 30% of IE patients do not exhibit obvious heart murmur during early stages of disease development, and during the course of treatment. The doctors who treated the patient in the present study, before he came to our hospital, thought that the heart murmur could be

explained by mitral regurgitation and did not consider the possibility of IE. Notably, they were satisfied with improvement of his clinical symptoms and did not follow up the disease change, a phenomenon that resulted in a delay of the disease.

Bacteremia, caused by pathogenic microorganisms in the blood, is the basis for the development of IE. Blood culture tests have diagnostic value and can help guide selection of anti-infective drugs. The main pathogens and major routes of infection in IE have changed in recent years. Notably, virulent and drug-resistant staphylococci are the most common factors, and are more likely to occur in elderly patients, as well as those with nosocomial chronic disease and intracardiac implants. In the present study, blood culture results suggested that this patient had *Streptococcus gordonii* infection. This pathogen belongs to the Gram-stain-positive retarded streptococcal group and is a partly anaerobic α -hemolytic streptococcus (VGS). Recent studies have shown that Community-acquired autologous valvular endocarditis caused by VGS is also common in IE patients, particularly in developing countries

[5], and many of them are caused by *Streptococcus gordonii*. Generally, *S. gordonii* colonizes the oral cavity and upper respiratory tract, Mainly involved in the composition of dental plaque, it is a conditional pathogen, usually not pathogenic. In recent years, many cases of *S. gordonii* infections have been reported in China and abroad, including sepsis, IE, splenic abscess and septic arthritis. These infections have subsequently been associated with poor oral hygiene, loose teeth, dental surgery and other invasive procedures. The patient in the present study exhibited upper respiratory tract infection symptoms, such as a sore and dry throat 1 week before onset of fever. However, he did not pay attention to these symptoms and had overexertion during the same period [6]. It is worth noting that medical history is imperative to effective disease diagnosis.

Echocardiography is a key procedure for confirming IE diagnosis [7], due to the fact that it cannot only detect the superfluous organisms at an early stage, but also accurately measure their sizes, thereby facilitating assessment of disease severity, understanding cardiac function, and detection of cardiac complications, among others [8]. However, echocardiography is influenced by subjective factors. In the present case, initial cardiac echocardiography failed to detect superfluous organisms in this patient's heart valve, and Relaxed vigilance. We attributed this to the fact that the location and size of the flab were not easily detectable by the ultrasound beam, and physician inexperience. Transesophageal echocardiography can detect the redundant organisms with a diameter of 1-1.5 mm and directly reveal the relationship between the redundant organisms and the valve from the posterior left atrium, achieving a positive detection rate of up to 90%. However, echocardiography is not an ideal detection tool for patients with severe valvular lesions, bulging valves <2 mm, prolapsed valves, or valves without bulging valves/Based on this, a negative result does not completely exclude IE.

Successful IE treatment depends on efficient removal of pathogenic microorganisms, and surgery has shown promise in successfully eradicating them [9]. Previous studies have shown that in order to reduce morbidity and mortality, 20-50% of patients require sexual cardiac surgery to remove infected tissue and restore valve function [10-12]. In fact, timely surgery is the only hope for saving a patient's life in a case of severe IE. Internal medicine and surgery have their own advantages and shortcomings during IE treatment. Although internal medicine-based treatment can clear most of the microorganisms, it was not efficacious in the patient in this case. Use of anti-infection treatment not only caused an impairment of his cardiac function, but also resulted in hemodynamic abnormalities due to the destruction of intracardiac structures, and the emergence of bacterial emboli dislodged. Therefore, internal medicine treatment alone cannot prevent occurrence of superfluous events, necessitating application of surgical treatment which corrects congenital valve malformation, and restores heart valve. The

patient in the current study was subjected to surgical treatment, which corrected his congenital valve malformation, restored heart valve function, and improved heart failure. The patient recovered. Choosing the right time for surgery is the key to effective surgical treatment. It is generally believed that patients with heart failure or hemodynamic disorders, persistent infections, uncontrolled intracardiac local infections, refractory microbial infections, persistent flabby biology >10mm with embolism or valve dysfunction should be operated as soon as possible [13]. Echocardiography results of the patient in the present study revealed a flabby biology measuring 1.2cm * 1.2 cm, with indications for surgery. There are also conservatives who believe that surgical intervention is not appropriate in the acute phase, due to a possibility of increased occurrence of complications and high surgical risks. Notably, controversy still surrounds the timing and indications for surgery necessitating further research explorations with large randomized controlled clinical trials. Although application of cardiac surgery for treatment of active infective endocarditis is only a century old, recent advances in surgical techniques and perioperative management have made it the cornerstone of IE treatment. Moreover, there is no uniform standard for indication, timing, and risk assessment of surgery in active IE, due to the complexity and variable nature of the disease [14]. Therefore, clinical decision making in complex cases must be fully individualized, taking into account the patient's demographic characteristics, comorbidities, disease severity, and stage, in order to determine whether and when to perform surgical intervention and to prepare for the foreseeable risks after surgery. There is need to consult hospitals with multidisciplinary teams specializing in IE in cases of complex IE cases. Given the large number of IE patients in China, there is a need for concerted efforts across clinical research to standardize IE treatment strategies by focusing on the unresolved international issues. Since the population and pathogenic spectrum of IE patients in China are different from those in Europe and the United States, there is need to develop active IE surgery strategies for the Chinese population.

5. Conclusion

The following conclusions are drawn from the present case study:

1. Infective endocarditis is characterized by insidious onset, difficult diagnosis, aggressive condition and susceptibility to flabby dislodgement events. Therefore, patients with recurrent fever of unknown origin need to be alert.
2. There is need for clinicians to raise awareness on IE, especially by performing comprehensive physical examinations and analysis. Clinicians should highly consider IE in patients with unexplained fever, especially those with underlying cardiac disease conditions.
3. Patients with high suspicion of IE but negative echocardiogram should be retested or operated by a senior ultrasonographer. In cases where transthoracic echocardiogram suggests indirect hints, such as valve prolapse, incomplete closure, or septic lesions, trans-

esophageal echocardiogram should be performed promptly to improve the detection rate.

4. Disease course in patients with active IE is often complex and variable. Although international guidelines have somewhat standardized the indications and timing of surgery in active IE patients, there is still a need for concerted efforts from an IE-specific multidisciplinary team during decision making for specific patients. In fact, the discussion on the indication and timing of surgery is a game of risk versus expected benefit. Therefore, assessment of the risk of surgery in active IE patients is imperative to effective management of the disease.

References

1. Werdan K, Dietz S, Löffler B, Niemann S, Bushnaq H, Silber RE, et al. Mechanisms of infective endocarditis: pathogen-host interaction and risk states. *Nat Rev Cardiol*. 2014; 11(1): 35-50.
2. Li JS, Sexton DJ, Mick N, Nettles R, Fowler VG, Ryan T, et al. Proposed modifications to the Duke criteria for the diagnosis of infective endocarditis. *Clin Infect Dis*. 2000; 30(4): 633-638.
3. Kitai T, Masumoto A, Okada T, Koyama T, Furukawa Y. Optimal timing of surgery for patients with active infective endocarditis. *Cardiol Clin*. 2021; 39(2): 197-209.
4. Ciurus M. Prevention of endocarditis in dentistry. *Pol Merkur Lekarski*. 2021; 49(289): 88-89.
5. Li JS, Sexton DJ, Mick N, Nettles R, Fowler Jr VG, Ryan T, et al. Proposed modifications to the Duke criteria for the diagnosis of infective endocarditis. *Clin Infect Dis*. 2000; 30(4): 633-638.
6. Ciurus M. Prevention of endocarditis in dentistry. *Pol Merkur Lekarski*. 2021; 49(289): 88-89.
7. Yoshikawa F, Haba K, Nakajima T, Kumazakia S, Hanadaa M, Hirata K, et al. The Activity of Infective Endocarditis Was Correlated to the Procalcitonin Value. *Journal of Medical Cases*. 2015; 6(5): 183-1842.
8. Cornelissen CG, Frechen DA, Schreiner K, Marx N, Krüger S. Inflammatory parameters and prediction of prognosis in infective endocarditis. *BMC Infect Dis*. 2013; 13: 272.
9. Xu H, Cai S, Dai H. Characteristics of infective endocarditis in a tertiary hospital in East China. *PLoS One*. 2016; 11(11): e0166764.
10. Dickerman SA, Abrutyn E, Barsic B, Cecchi E, Moreno A, Doco-Leconte T, et al. The relationship between the initiation of antimicrobial therapy and the incidence of stroke in infective endocarditis: an analysis from the ICE prospective cohort study (ICE-PCS). *Am Heart J*. 2007; 154(6): 1086-1094.
11. Rutherford SJ, Glenny AM, Roberts G, Hooper L, Worthington HV. Antibiotic prophylaxis for preventing bacterial endocarditis following dental procedures. *Cochrane Database Syst Rev*. 2022; 5: CD003813.
12. Bouza E, Munoz P, Burillo A. Gram-negative endocarditis: disease presentation, diagnosis and treatment. *Curr Opin Infect Dis*. 2021; 34(6): 672-680.
13. Vieira ML, Grinberg M, Pomerantzeff PM, Andrade JL, Mansur AJ. Repeated echocardiographic examinations of patients with suspected infective endocarditis. *Heart*. 2004; 90(9): 1020-1024.
14. Rezar R, lichtenauer M, haarm M, Hödl G, Kern JM, Zhou Z, et al. Infectiveendo-carditis- A review od current therapy and futurechallenges. *Hellenic JC ardiol*. 2021; 62(3): 190-200.
15. Cecchi E, Ciccone G, Chirillo F, Imazio M, Cecconi M, Ponte SD, et al. Mortality and timing of surgery in the left-side in fectiveendo-carditis: anitalian multic entrestudy. *interactcardio-vascthorac surg*. 2018; 26(4): 602-609.